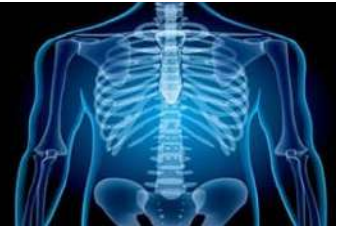

# International Journal of Radiology and Diagnostic Imaging



E-ISSN: 2664-4444  
P-ISSN: 2664-4436  
[www.radiologypaper.com](http://www.radiologypaper.com)  
IJRDI 2020; 3(3): 16-20  
Received: 14-05-2020  
Accepted: 16-06-2020

**Ravindra BN**  
Assistant Professor,  
Department of Radiology,  
MIMS, Mandya, Karnataka,  
India

**Devika C**  
Assistant Professor,  
Department of Radiology,  
MIMS, Mandya, Karnataka,  
India

## Evaluation of optic nerve variations in relation to posterior paranasal sinuses among study population of Mandya District of Karnataka State

**Ravindra BN and Devika C**

**DOI:** <http://dx.doi.org/10.33545/26644436.2020.v3.i3a.110>

### Abstract

This study aims to determine relationship of optic nerves to posterior paranasal sinuses, its types, incidence and prevalence among study population of Mandya district, Karnataka. This observational study comprised 124 patients who were recommended for FESS and were referred to radiology department for CT scan between July 2019 to December 2019 at MIMS, Mandya. The age and sex of the patients along with the symptoms and its duration was recorded. All the patients underwent a comprehensive medical history and head and neck physical examination. A high resolution, 1.25 mm thick CT scan was taken for the study. Relationship of optic nerves to posterior paranasal sinuses was categorized according to Delano classification. Descriptive statistics like mean and percentages were used for analysis using SPSS v.22. The findings showed the prevalence of Onodi cells in 22.6% of the patients. Onodi cells were observed in 8.9% on the right side and 5.6% on left side of the patients respectively. In 8.1% of the patients, bilateral Onodi cells were present. ACP pneumatization was present in 25.1% of the patients bilaterally. ACP pneumatization was found on the right side and left side in 10.5% and 6.5% respectively. 124 patients underwent CT of paranasal sinuses during study period and course of 248 optic nerves were examined in relation to posterior paranasal sinuses. Type 1, Type 2, Type 3, and Type 4 optic nerves were present in 83.33%, 8.87%, 12.1%, and 21.78% respectively. Bilateral Type 1 optic nerves was present in 58.88% patients, both Type 2 and Type 3 optic nerves were seen bilaterally in 3.23% of patients and bilateral Type 4 optic nerve was seen in 10 (8.06%) cases. Optic nerve Type 1 (83.88%) was the most frequent nerve type, followed by Type 4 (21.78%). In conclusion, the anatomical variations of paranasal sinuses are very important to be identified preoperatively since sphenoid sinus and optic nerve relation is known for its variation. Before endoscopic sinus surgery, one needs to know this anatomy using CT of paranasal sinuses using Delano classification of optic nerve.

**Keywords:** optic nerve, posterior paranasal sinuses, tomography, delano classification, Mandya

### Introduction

The use of functional endoscopic sinus surgical procedures (FESS) has increased steadily since their introduction in 1984. The enormous variability in the anatomy of sphenoidal and posterior ethmoidal sinuses is well documented<sup>[1-6]</sup>. Computed tomography (CT) is the gold standard investigation for the evaluation of paranasal sinus diseases<sup>[7-11]</sup>. Accurate evaluation of these structures is possible with preoperative computed tomography (CT) of the sinuses.

With the introduction of nasal endoscope and expanded surgical procedures, knowledge of this anatomy takes on added significance. The pneumatization and development of paranasal sinuses starts in embryonic life during third to fifth gestational months and ends in early adulthood. There are many unknown factors which can change this pattern and can lead to anatomical variants. There are many sinonasal anatomic variants which can be easily detected by CT scan<sup>[12-14]</sup>. Concurrently, an increase in the frequency of serious complications, including death and intracranial and orbital injuries, was noted. Of these, the most common are injuries of the orbit and optic nerve. The term posterior paranasal sinuses include posterior ethmoid and sphenoid sinuses. Optic nerve develops prior to development of paranasal sinuses; hence it is responsible for congenital variations along wall of paranasal sinuses<sup>[15]</sup>. Close anatomical relation between orbits and posterior paranasal sinuses places the optic nerve at risk during FESS<sup>[16]</sup>.

**Corresponding Author:**  
**Ravindra BN**  
Assistant Professor,  
Department of Radiology,  
MIMS, Mandya, Karnataka,  
India

Enormous variation has been recognized in anatomy of sphenoid and posterior ethmoid sinuses. Delano *et al.* proposed a classification for better understanding of regional anatomy; which states that Type 1- Optic nerve is immediately adjacent to lateral and superior wall of sphenoid sinus without impression on sinus wall. Type 2 - Optic nerve causes an impression on lateral sphenoidal sinus wall. Type 3 - Optic nerve courses through the sphenoid sinus. Type 4 - Optic nerve courses immediately lateral to posterior ethmoid and sphenoid sinuses<sup>[17]</sup>.

Therefore, a clear understanding of the relationship between paranasal sinuses and the course of optic nerve is critical in planning and performing surgery involving the posterior ethmoidal and sphenoidal sinuses. With these viewpoints the present study was designed to determine relationship of optic nerves to posterior paranasal sinuses and its various types, their incidence and prevalence among study population of Mandya district of Karnataka state.

### Materials and methods

This observational study comprised of 124 patients who were recommended for FESS and were referred to radiology department for CT scan between July 2019 to December 2019. The patients with prior sinus surgery, sinonasal tumors, nasal polyposis, severe cervical arthropathy, or head and neck injury were excluded from the study. The patients in the age between 5 and above 55 years old and the CT images of the patients aged 12 to 70 years of both sexes were included and planned for FESS. The age and sex of the patients along with the symptoms and its duration was recorded. All the patients underwent a comprehensive medical history and head and neck physical examination.

**CT protocol:** CT was done with patient in supine position with 16 slice Helical Multi Detector CT (Philips 16 slice CT scanner), 1.25 mm thickness, coronal sections in bone window, Kv: 120 and mAs: 100-150. The optic nerves were classified according to Delano classification: which states "Type 1- Optic nerve is immediately adjacent to lateral and superior wall of sphenoid sinus without impression on sinus wall. Type 2 - Optic nerve causes an impression on lateral sphenoidal sinus wall. Type 3 - Optic nerve courses through the sphenoid sinus. Type 4 - Optic nerve courses immediately lateral to posterior ethmoid and sphenoid sinuses." Descriptive statistics like mean and percentages were used for analysis using SPSS v.22.

### Results

The study included 124 patients with 63.7% males and

36.3% females. Age of study population ranged between 5 and  $\geq 55$  years old with mean age of 34 years. Most of study patients are young and middle-aged adults, ranging from 16 to 45 years, 67.7% (Table 1).

**Table 1:** Age and gender wise distribution among patients

S. No.	Characteristics	Frequency	Percent
<b>Age in years</b>			
Mean age 33.62 $\pm$ 16.03			
1	5 to 15	14	11.3
	16 to 25	35	28.2
	26 to 35	26	21.0
	36 to 45	23	18.5
	46 to 55	13	10.5
	Above 55	13	10.5
	Total	124	100
	<b>Gender</b>		
2	Male	45	36.3
	Female	79	63.7
	Total	124	100.0

Among the study population the prevalence of anatomical variants such as Onodi cell out of 124 (100%) patients was 28 (22.6%) and Anterior Clinoid Process (ACP) Pneumatization was 31 (25.1%). The Onodi cells were seen in 28 (22.6%), of them 11 (8.9%) on the right side, 7 (5.6%) on the left side and bilateral 10 in (8.1%). ACP Pneumatization was found in 31 (25.1%) patients, of them 13 (10.5%) were on the right side, 8 (6.5%) on the left side and bilateral in 10 (8.1%) cases (Table 2).

**Table 2:** Distribution of variations in sphenoid sinus among patients

		Right	Left	Bilateral	Total
Onodi cells	n	11	7	10	28.0
	%	8.9	5.6	8.1	22.6
ACP Pneumatization	n	13	8	10	31.0
	%	10.5	6.5	8.1	25.1

124 patients underwent CT of paranasal sinuses and course of 248 optic nerves were examined in relation to posterior paranasal sinuses. The relationship of optic nerve to the posterior paranasal sinuses was characterized as one of four types. Among 124 (100%) study patients, the prevalence of Type 1, Type 2, Type 3 and Type 4 was observed as 104/124 (83.33%), 11/124 (8.87%), 15/124 (1.10%) and 27/124 (21.78%) respectively (Table 3).

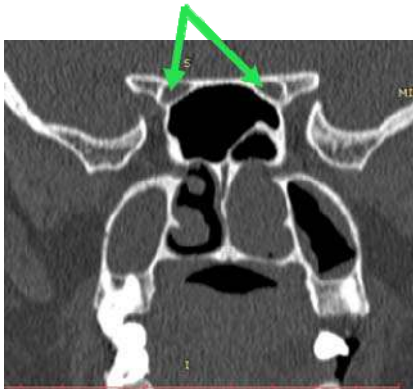
**Table 3:** Optic nerves Types distribution of the patients

Optic Nerves Types		Right	Left	Bilateral	Total
Type 1	n	12.00	19.00	73.00	104.00
	%	9.68	15.32	58.88	83.88
Type 2	n	1.00	6.00	4.00	11.00
	%	0.80	4.84	3.23	8.87
Type 3	n	9.00	2.00	4.00	15.00
	%	7.25	1.62	3.23	12.10
Type 4	n	11.00	6.00	10.00	27.00
	%	8.88	4.84	8.06	21.78

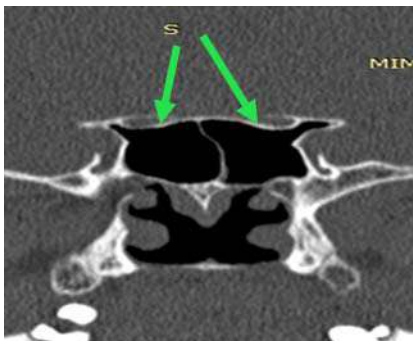
Bilateral Type 1 optic nerves were present in 58.88% (73/124) patients (Figure 1), both Type 2 and Type 3 optic nerves were seen bilaterally in 3.23% (4/124) patients (Figure 2 and 3) and bilateral Type 4 optic nerve was seen

in 8.06% (10/124) (Figure 4). In the most common form, *i.e.* Type 1 optic nerves (83.88%), the optic nerve was immediately adjacent to the lateral or superior wall of the sphenoid sinus, without impression on the sinus wall. There

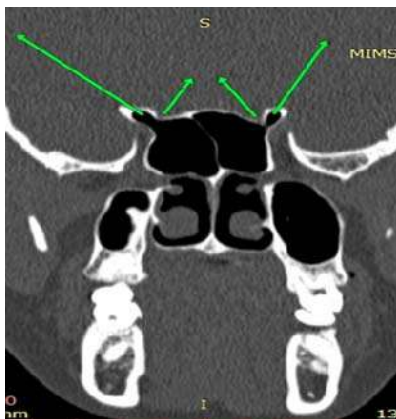
was not much difference between right and left sides. In Type 1 optic nerve pattern, right and left optic nerves was present in 9.68% and 15.32% of subjects respectively. Whereas, Type 2 optic nerves 11 (8.87%) cause an impression on the lateral sphenoidal sinus wall. In Type 2 pattern right and left optic nerve was present in 0.8% and 4.84% respectively. Type 3 optic nerves was present in 12.1% subjects coursing through the sphenoid sinus rather than simply running adjacent to the sinus. In Type 3 optic nerve pattern right and left optic nerve was present in 7.25% and 1.62% respectively. With regards to Type 4 optic nerves immediately lateral to the posterior ethmoidal and sphenoidal sinuses (i.e. Onodi cell) was observed in 27 (21.78%) cases. In Type 4 optic nerve pattern right and left optic nerves was present in 8.8% and 4.84% respectively. Mixed pattern of Right Type IV (with Onodi cell) and Left Type I Optic nerves were also seen (Figure 5).



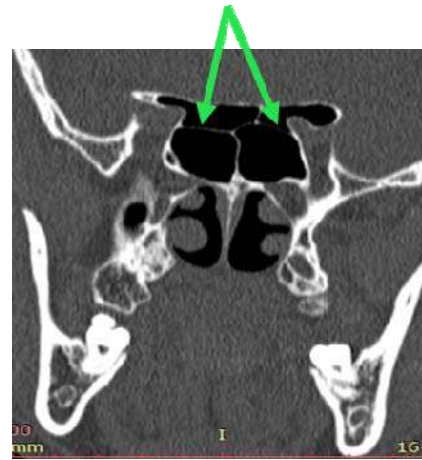
**Fig 1:** Bilateral Type 1 Optic nerves



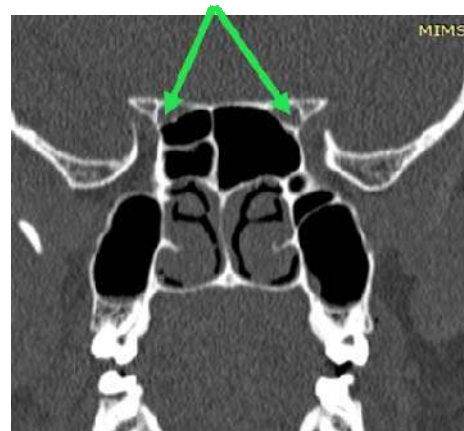
**Fig 2:** Bilateral Type 2 Optic nerves



**Fig 3:** Bilateral Type 3 Optic nerves



**Fig 4:** Bilateral Onodi cells with Type 4 Optic nerves



**Fig 5:** Right Type 4 (with Onodi cell) and Left Type 1 Optic nerves

### Discussion

The relationship between the optic nerve and the paranasal sinuses has been studied for nearly a century. The optic nerve is usually in proximity to both the ethmoidal and sphenoidal sinuses and dehiscence or very thin bone overlying the optic nerve when the posterior ethmoidal or sphenoidal sinuses are extensively pneumatized. CT can clearly show the relationship between optic nerve and the paranasal sinuses. It is the imaging technique of choice in the examination of the paranasal sinuses and adjacent structures. Its ability to display bone, soft tissue, and air facilitates accurate depiction of anatomy and extent of disease in and around the paranasal sinuses. Sphenoid sinus is an aerated mucosa lined cavity occupying central location in skull bone. It is present at birth, pneumatization continues into adulthood. Pneumatization pattern is variable and can extend to surrounding adjacent structures. Varied relation of optic nerve to paranasal sinuses is attributed to inconsistent pneumatization pattern of sphenoid sinus<sup>[18]</sup>. Delano *et al.* were amongst the first to study the relation of optic nerves to posterior paranasal sinuses and to devise a classification system<sup>[17]</sup>.

In the present study 124 patients of age group between 5 and  $\geq 55$  years old were included. The mean age of the study patients was 34 years and most study patients were in young adult age (between 16 to 45 years old). Among the age and gender groups it was highest *i.e.* 63.7% in young adult male group. These findings were like the several other research

studies reported in the literature [19-21]. In our study, the anatomical variants which are of surgical importance was included in our study, such as Onodi cell and ACP pneumatization. The prevalence of Onodi cell was 22.6% and ACP pneumatization was 25.1%. These findings were comparable with the study conducted by Kaya *et al.* where in Onodi cells was observed among 14% patients and 21.1% patients had ACP pneumatization [22]. The prevalence of Onodi cells was reported to be 10%-98% in the literature [23, 24]. The prevalence of Onodi cells was recorded in 22.6% of the paranasal sinuses in our study was in concurrence with literature reports. Onodi cells can be a mistaken point in evaluating the anatomical landmarks during endoscopic sinus surgery. Hence, its presence must be reported since it can result in penetration into the middle cranial fossa, and if it is together with a dehiscence causing pneumatization of crista galli, it can result in penetration into the anterior fossa during FESS [25]. The ACP pneumatization rate was 25.1%, and this is in accordance with previous studies in the literature [17, 26-31].

Of the 248 optic nerves studied in our study, among 124 study patients, prevalence of Type 1, Type 2, Type 3, and Type 4 optic nerves were observed as 83.88%, 8.87%, 12.10% and 21.78% respectively. In Type 1, there is no adjacent ACP pneumatization. Whereas, in Type 2 pneumatization of ACP was adjacent to optic nerve, in Type 3- adjacent pneumatization with indentation, and in Type 4- pneumatization with involvement of less than 50% optic nerve circumference was observed. Optic nerve Type 1 (83.88%) was the most frequent nerve type, followed by Type 4 (21.78%) and is similar to the study of Yazici D 2018 [32]. In another research conducted by Kiran and Bragg found that 58.31% of type 1 of optic nerve, 16.95% of type 2, 9.15% of type 3 and 15.59% of type 4 [18]. Literature survey evidenced, the type 1 optic nerve was the most prevalent type, followed by type 2 [26-33]. Itagi *et al.* also followed a slightly modified version of Delano classification wherein they found that Type 1 at 60%, type 2 at 15%, type 3 at 14% and type 4 at 11% [34]. The relationship of the optic nerve to the posterior paranasal sinus fell into one of four discrete categories, type 1 through type 4. All 248 nerves were intimately related to the sphenoidal sinus. Sphenoid sinus and optic nerve relation are known for variations. Hence, Delano classification is a useful way in looking at location of optic nerve and posterior paranasal sinuses.

### Conclusion

The findings of our study delineated that among all 248 optic nerves evaluated were intimately related to the sphenoidal sinus. We found that increased sphenoidal sinus pneumatization is associated with increasing optic nerve exposure. Identification of Onodi cell is very important clinically because of its proximity to optic nerve canal. Anatomic configurations that predispose the optic nerve to injury include the type 2 or type 3 optic nerve relationship, bone dehiscence over the nerve, and pneumatization of the anterior clinoid process. These patterns are common and should be routinely sought out so that devastating complications of optic nerve injury from sinus surgery can be avoided. Hence, we concluded that the anatomical variations of paranasal sinuses are very important to be identified preoperatively since sphenoid sinus and optic nerve relation is known for its variation. Before endoscopic sinus surgery, one needs to know this anatomy using CT of

paranasal sinuses using Delano classification of optic nerve.

### References

1. Onodi A. The optic nerve and the accessory cavities of the nose. *Ann Otol Rhinol Laryngol.* 1908; 17:1-61.
2. Schaeffer JP. The Nose, Paranasal Sinuses, Nasolacrimal Passageways, and Olfactory Organs in a Man: A Genetic, Developmental, and Anatomico-physiological Consideration. Philadelphia, Pa: Blakiston's Son & Co, 1920, 190-193.
3. Peele JC. Unusual anatomical variations of the sphenoid sinuses. *Laryngoscope.* 1957; 67:208-237.
4. Fujii K, Chambers SM, Rhoton AL. Neurovascular relationships of the sphenoid sinus. *J Neurosurg.* 1979; 50:31-39.
5. Cheung DK, Attia EL, Kirkpatrick DA, Marcarian B, Wright B. An anatomic and CT scan study of the lateral wall of the sphenoid sinus as related to the transnasal transthemoid endoscopic approach. *J Otolaryngol.* 1993; 22:63-68.
6. Hudgins PA. Complications of endoscopic sinus surgery. *Radiol Clin North Am.* 1993; 31:21-32.
7. de Miranda CM, de Miranda Maranhão CP, Arraes FM, Padilha IG, de Farias LD, de Araujo Jatobá MS. Anatomical variations of paranasal sinuses at multislice computed tomography: what to look for. *Radiol Bras.* 2011; 44:256-62.
8. Tiwari R, Goyal R. Study of Anatomical Variations on CT in Chronic Sinusitis. *Indian J Otolaryngol Head Neck Surg.* 2015; 67(1):18-20.
9. Adeel M, Rajput MS, Akhter S, Ikram M, Arain A, Khattak YJ. Anatomical variations of nose and paranasal sinuses; CT scan review. *J Pak Med Assoc.* 2013; 63(3):317-9.
10. Kim HJ, Jung Cho M, Lee JW *et al.* The relationship between anatomic variations of paranasal sinuses and chronic sinusitis in children. *Acta Otolaryngol.* 2006; 126(2):1067-1072.
11. Fadda GL, Rosso S, Aversa S *et al.* Multiparametric statistical correlations between paranasal sinus anatomic variations and chronic rhinosinusitis. *Acta Otorhinolaryngol Ital.* 2012; 32(1):244-251.
12. Piskunov IS, Emel'ianova AN. Variants of the anatomical structure of frontal sinuses based on the results of X-ray computed tomography. *Vestn Otorinolaringol.* 2011; 1:16-21.
13. Robinson M, Donlon D, Harrison H, Houang M, Stammberger H, Wolf G. Variations of the paranasal sinuses in Melanesians as observed by CT. *Rhinology.* 2010; 48(1):11-7.
14. Bâldea V, Indrei A, Ciupilan C, Scutariu MD. Anatomical variations of landmarks in endoscopic surgery of the paranasal sinuses revealed by MRI imaging. *Rev Med Chir Soc Med Nat Iasi.* 2010; 114(2):490-503.
15. Reddy UD, Dev B. Pictorial essay: Anatomical variations of paranasal sinuses on multidetector computed tomography-How does it help FESS surgeons? *The Indian journal of radiology & imaging.* 2012; 22(4):317.
16. Kim JY, Kim HJ, Kim CH, Lee JG, Yoon JH. Optic nerve injury secondary to endoscopic sinus surgery: an analysis of three cases. *Yonsei medical journal.* 2005; 46(2):300-4.

17. Delano MC, Fun FY, Zinreich SJ. Relationship of the optic nerve to the posterior paranasal sinuses: a CT anatomic study. *American journal of neuroradiology*. 1996; 17:669-75.
18. Kiran KS, Braggs A. CT Study of Relationship of Optic Nerve to Posterior Paranasal Sinuses. *International Journal of Contemporary Medicine Surgery and Radiology*, 2017, D71-D73.
19. Espinosa W, Genito R, Ramos RZ. Anatomic variations of the nasal cavity and paranasal sinus and their correlation with chronic rhinosinusitis using Harvard staging system. *J Otolaryngol ENT Res*. 2018; 10(4):190-3.
20. Kaygusuz A, Haksever M, Akduman D, Aslan S, Sayar Z. Sinonasal anatomical variations: their relationship with chronic rhinosinusitis and effect on the severity of disease-a computerized tomography assisted anatomical and clinical study. *Indian Journal of Otolaryngology and Head & Neck Surgery*. 2014; 66(3):260-6.
21. Hadi HH, Al-Bayati HA, Al-Gazali SS. Prevalence of normal anatomical variations in the region of paranasal sinuses in patients with chronic rhinosinusitis. *Medical Journal of Babylon*. 2018; 15(3):243-50.
22. Kaya M, Çankal F, Gumusok M, Apaydin N, Tekdemir I. Role of anatomic variations of paranasal sinuses on the prevalence of sinusitis: Computed tomography findings of 350 patients. *Nigerian Journal of Clinical Practice*. 2017; 20(11):1481-8.
23. Perez-Pinas I, Sabate J, Carmona A, Catalina-Herrera CJ, Jimenez-Castellanos J. Anatomical variations in the human paranasal sinus region studies by CT. *J Anat*. 2000; 197:221-7.
24. Meyers RM, Valvassori G. Interpretation of anatomic variations of computed tomography scans of the sinuses: A surgeon's perspective. *Laryngoscope*. 1998; 108:422-5.
25. Zinreich SJ, Benson ML, Oliverio PJ. Sinonasal cavities: CT normal anatomy, imaging of the osteomeatal complex, and functional endoscopic surgery. In: Som PM, Curtin HD, editors. *Head and Neck Imaging*. 3rd ed. St. Louis: Mosby Year Book, 1996, 110.
26. Lee JC, Kao CH, Hsu CH, Lin YS. Endoscopic transsphenoidal vidian neurectomy. *Eur Arch Otorhinolaryngol*. 2011; 268(6):851-6.
27. Mladina R, Cujjić E, Subarić M, Vuković K. Nasal septal deformities in ear, nose, and throat patients: an international study. *Am J Otolaryngol*. 2008; 29(2):75-82.
28. Turna O, Aybar M, Karagoz Y, Tuzcu G. Anatomic Variations of the Paranasal Sinus Region: Evaluation with Multidetector CT. *Istanbul Medical Journal*. 2014; 15(2):104-9.
29. Onwuchekwa RC, Alazi N. Computed tomography anatomy of the paranasal sinuses and anatomical variants of clinical relevants in Nigerian adults. *Egyptian Journal of Ear, Nose, Throat and Allied Sciences*. 2017; 18(1):31-8.
30. Bolger WE, Parsons DS, Butzin CA. Paranasal sinus bony anatomic variations and mucosal abnormalities: CT analysis for endoscopic sinus surgery. *The Laryngoscope*. 1991; 101(1):56-64.
31. Tonai A, Baba S. Anatomic variations of the bone in sinonasal CT. *Acta Otolaryngol Suppl*. 1996; 525:9-13.
32. Yazici D. Evaluation of Anatomical Variations on Paranasal Sinus CT. *ENT Updates*. 2018; 8(3):175.
33. Al-Tameemi HN, Hassan HA. The Anatomical relationship of Optic Nerve Canal to the Posterior Paranasal Sinuses on Computerized Tomography in Iraqi Patients. *Journal of Contemporary Medical Sciences*, 2018, 4(3).
34. Itagi RM, Adiga CP, Kalenahalli K, Goolahally L, Gyanchandani M. Optic nerve canal relation to posterior paranasal sinuses in Indian ethnics: Review and objective classification. *Journal of clinical and diagnostic research: JCDR*. 2017; 11(4):TC01.