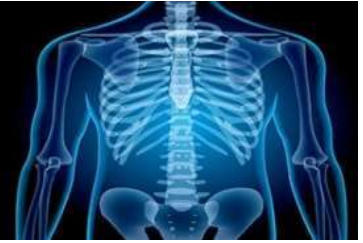

International Journal of Radiology and Diagnostic Imaging



E-ISSN: 2664-4444
P-ISSN: 2664-4436
www.radiologypaper.com
IJRDI 2021; 4(1): 79-83
Received: 29-10-2020
Accepted: 12-12-2020

Dr. Khaleel Ibraheem Mohson
Assiatant Professor in
National Cancer Research
Center, University of Baghdad,
Iraq

Role of magnetic resonance in-phase and out of phase sequences in differentiating benign from suspicious vertebral marrow lesions

Dr. Khaleel Ibraheem Mohson

DOI: <http://dx.doi.org/10.33545/26644436.2021.v4.i1b.165>

Abstract

Background: advances in Magnetic resonance imaging sequences which include the in-phase and out of phase sequences are helpful in the assessment of worrying vertebral marrow lesion especially if the patients presented with primary malignancy outside the spines.

Objectives: The study aimed to evaluate the role of spinal MR (magnetic resonance) imaging in the evaluation of bone marrow lesion in patients with primary malignancy using in-phase and out of phase sequences in addition to conventional MR sequences.

Methods: This is a cross-sectional study included 80 patients referred to MR unit from the oncology department in oncology teaching hospital – medical City, Baghdad, Iraq during the period from the beginning of September 2018 to October 2019, 22 of them having no cancer and referred to MRI due to lower back pain while the remaining 58 patients had primary non-osseous cancer and referred complaining from back pain and exclude bony metastasis.

Results: the study sample consisted of 55 females and 25 males, the breast cancer is the main primary in females and represent 30/58 patients while the prostate cancer is main cancer in males and represent 7/58 patients, Most of the suspicious lesions appearing low on T1W, high on T2W and Fatsat sequences this represents seen in (27.5%) of those only (12%) patients are really metastasis, while when adding the high out of phase/in phase ratio, the percentage decrease from 27.5% to 8.5%, the sensitivity, specificity, positive predictive value (PPV) and negative predictive valve (NPV) and overall accuracy of out of phase/ in phase ratio in detecting metastasis within the vertebral marrow are 66.6%, 90.7%, 61.4%, 92.4%, and 86% respectively.

Conclusion: Utilizing in phase and out of phase sequences and calculating the OIR greatly assist in diagnosing suspicious marrow lesions, hence this technique is greatly reducing the need for Intravenous contrast administration.

Keywords: Vertebral metastasis, MRI, in phase sequence, out of phase sequence

Introduction

Unfortunately, secondary deposit to the bone marrow to the axial skeleton including the vertebral bodies, pelvic bone, the femora, sternum, and *humeri* is, a common manifestation in many cancers being an either early or late presentation of the disease ^[1]. The presence of marrow deposit changes the treatment plan for the patients because this diagnosis was considered late-stage and here only palliative treatment may be used ^[2]. Once the bone metastasis occurs the presentation is either bone pain, marked morbidity from the neurological problems and restriction of patient life from severe pain ^[3].

So any bony lesion seen in patients with primary malignancy need full characterization, this is usually done by using Magnetic resonance imaging (MRI), the traditional MRI can detect the lesion clearly from surrounding normal marrow, but this had a drawback in deciding whether this lesion is benign or malignant ^[4]. For that, the introduction of Functional MR imaging which includes the in-phase and out of phase sequences can help in doing this job and guessing what is the nature of the lesion ^[5].

In-phase/opposed-phase imaging bases on the assessment of the presence of fat and water in a voxel of tissue has been used mainly in assessment of the presence of intracellular fat in the case of focal liver fatty infiltration and adrenal glands adenomas. This technique utilizes the advantage of different precession frequencies of water and fat molecules ^[6].

The physics of this process at 1.5T shows that water and fat protons are in phase with one another at a TE of 4.6 milliseconds (MS), and 180°opposed at a TE of 2.4 Ms.

Corresponding Author:
Dr. Khaleel Ibraheem Mohson
Assiatant Professor in
National Cancer Research
Center, University of Baghdad,
Iraq

usually the signal intensity suppression occurs when the volume of fat and water is evenly equal, using this property is of benefit in the spine as its marrow consist of fat and marrow (which is high in water content), so when the is abnormal infiltration of the marrow by abnormal cells there will be loss of normal signal suppression on out of phase and thus the lesion is highlighted [7].

Materials and methods

This study included 80 patients referred to MR unit from the oncology department in an oncology teaching hospital-medical City, Baghdad, Iraq during the period from the beginning of September 2017 to October 2019.

All patients including those primary malignant tumors outside the bone marrow which are consist of 58 patients and 22 of them are having no cancer and all complaining of either back pain, symptoms related to spinal cord compression or having neurological deficit, those patients then subjected MRI examination of the spine, including the lumber or thoracolumbar areas, using Avanto 1.5T closed MRI system Siemens (Germany).

The MRI protocols include Sagittal T1-weighted spin-echo (SE), sagittal T2-weighted spin-echo (SE), Sagittal T2-weighted fat suppression spin-echo (TSE), and Axial T2-weighted spin-echo (SE).

After that we applying in phase and out of phase sequences

in the sagittal plane using TR of 4.8 and 2.5 MS respectively.

After obtaining these images, full analysis of pathological findings was done by reviewing the T1, T2 images and doing 3 dimensional (3D) reference to allocated the position of the lesion is in phase and out of phase sequences, the signal of the lesion is recorded in all sequences and in the suspicious lesion was calculated including the signal intensity ratio between the out of phase and in phase.

A correlation was done with histopathology and follow up the patient after radiotherapy, chemotherapy or hormonal therapy.

Results

This is a cross-sectional study which include 80 patients and four of them had followed up study after three months, 22 of them are cancer-free patients referred to MRI because of lower back pain and the remaining 58 patients had primary cancer outside the spine and referred complaining of back pain and to exclude metastasis.

The study sample consisted of 55 females and 25 males, the breast cancer is the main primary in females and represents 30/58 patients while the prostate cancer is main cancer in males, the later represent 7/58 patients, the detailed information of the age, the gender, and cancer types are illustrated in table one.

Table 1: age, gender and cancer types of study population

Age	
Age group	Number (%)
< 40 years	14 (17.5)
41-49	15 (18.7)
50-59	21 (26)
60-69	22 (27.5)
>70	8 (1)
Total	80 (100)
Gender	
Gender	Number (%)
Males	25 (31.25)
Females	55 (68.75)
Total	80 (100)
Cancer type	
Females	
	Number (%)
Breast	29 (72.5)
Ovary	03 (7.5)
Uterus	03 (7.5)
Other	05 (12.5)
Total	40 (100)
Males	
	Number (%)
Prostate	06 (46)
Lung	02 (15.5)
Other	05 (38.5)
Total	13(100)

The MR examination in the control group is normal in 18/22 patients, the remaining four reveals typical hemangioma in two, atypical hemangioma in one and modic I endplate changes in the remaining one.

While the examination of the patients with primary cancer reveals metastasis in 12/ 58 the remaining findings are discussed briefly in table 2

Table 2: MRI findings in control and patients in the study

	MRI findings	Number (%)
Control	Normal	18(82)
	Typical hemangioma	02(9)
	Modic I	01(4.5)
	Atypical hemangioma	01(4.5)
	Total	22(100)
Patients	Metastasis	14(24)
	Normal	17(29)
	Inactive	09(15)
	Typical and atypical hemangioma	07(12)
	Modic	03(5)
	Fracture	05(9)
	Collection	01(2)
	Others	02(4)
	Total	58(100)

Most of the suspicious lesions appearing low on T1W, high on T2W and Fatsat sequences this represents seen in 16/58 (27.5%) of those only 7 (12%) patients are really metastasis, while when adding the high out of phase/in phase ratio the percentage decrease from 27.5% to 8.5% (5/55). The out of phase/in phase ratio (OIR) greater than 1 is seen

in suspicious boney lesion. The sensitivity, specificity, positive predictive value (PPV) and negative predictive value (NPV) and overall accuracy of out of phase/in phase ratio in detecting metastasis within the vertebral marrow is illustrated in table 3.

Table 3: sensitivity, specificity, positive predictive and negative valve and overall accuracy of OIR in detecting metastasis.

OIR	Metastasis present	Metastasis absent	Total
high	8/84	5/84	13/84
low	4/84	49/84	53/84
Total	12/84	54/84	
	Value	95% CI	
Sensitivity	66.67%	34.89% to 90.08%	
Specificity	90.74%	79.70% to 96.92%	
PPV	61.54%	38.80% to 80.15%	
NPV	92.45%	84.56% to 96.48%	
Accuracy	86.36%	75.69% to 93.57%	

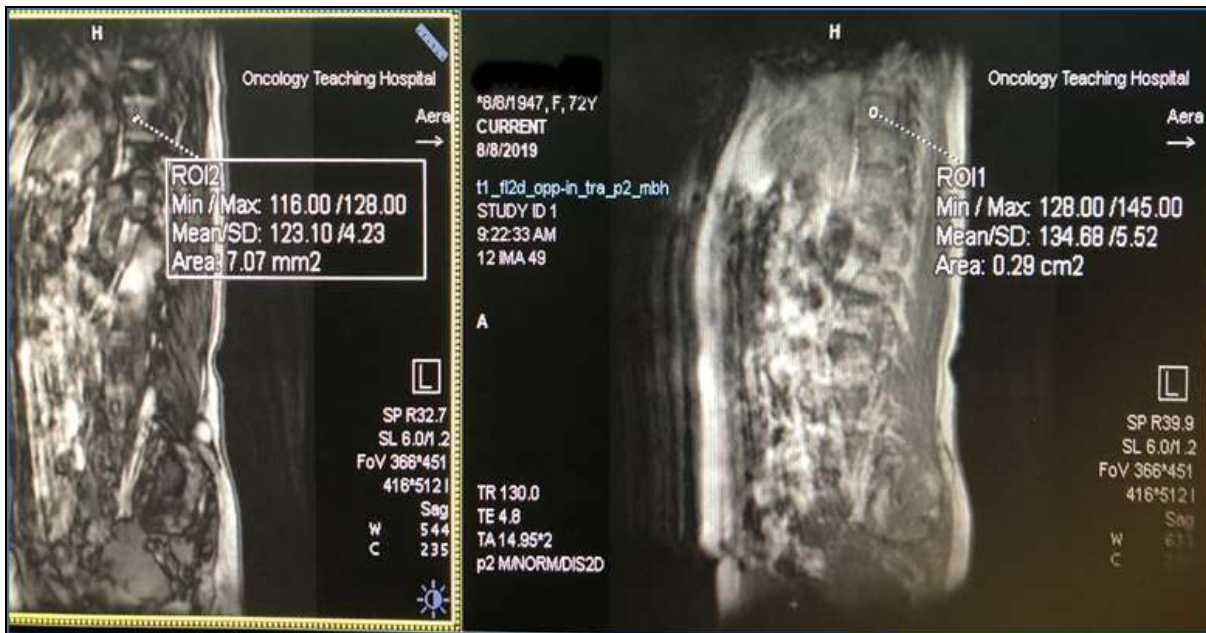

Fig 1: 72 years age female patient with history of ovarian cancer presented with back pain, her MRI reveals (a) focal lesion in lower dorsal vertebra (D11) the lesion appears isointense to fatty marrow in in-phase sequence, it signal intensity s 134.68 and the signal decrease to 123.1 in out-of-phase sequence with OIR= 0.95 indicate benign condition, follow up scan after 6months reveals size stability favors atypical hemangioma.

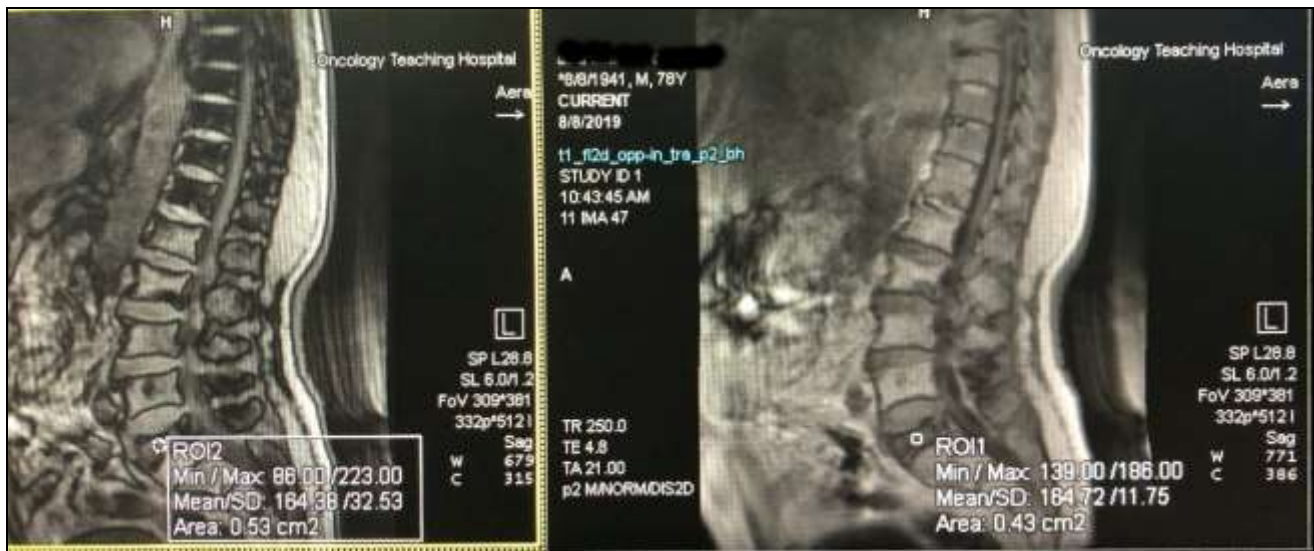


Fig 2: 78 years age male patient with history of bronchial cancer presented with lower back pain, his MRI reveals compressive fracture seen involving the L5 vertebral body, the in-phase signal is 164.72 while the out-phase signal was 164.38, the OIR is 0.99 follow up of this patients 3 months later reveals healing of the fracture.

Discussion

The differentiation between benign and malignant bone marrow lesions are not always possible in clinical practice and even by using traditional MR imaging, however the introduction of advance sequences including the Diffusion and apparent diffusion coefficient greatly improving and limiting the differential diagnosis of suspicious marrow lesion greatly improving and limiting the differential diagnosis of suspicious marrow lesion especially in patients with primary malignancy [1, 8, 12].

Before the introduction of the in phase/out of phase sequences, there was difficulties in accurately differentiating the lesion as a benign or malignant especially when depending on T1W and T2W images and even when adding the fat saturation sequence to conventional MR, in addition to that, sometimes the addition of the intravenous contrast media did not solve the problem because many benign lesions were enhancing.

Normal marrow compose of fluid and intracellular fat, so by applying the in phase and out of phase resulting in loss of normal marrow signal in out of phase sequence, however this is not seen when the marrow is replaced by benign or malignant lesion resulting in high signal within suppressed marrow in out of phase images the higher the OIR the likelihood the lesion is malignant [9].

In our study, the OIR in detection bony metastasis shows a high sensitivity of 66%, the specificity of 90% which is of higher sensitivity and specificity in comparison to the study done by Disler DG *et al.* in 1997 [10] the explanation of this is due to increment in percentage may be due to revolution in MR machines and increasing their field strength.

Regarding the PPV, NPV and overall accuracy of OIR in the detection of vertebral marrow secondary was 61.4%, 92.4%, and 86% respectively and these results are in concordance with a study done by Hoda A. El-Kareem A. El-Samie and Hosny Sayed A. El-Ghany in Egypt in 2015 [11].

Conclusion

1. Differentiation of the benign and malignant bony lesion is not possible by using Conventional MR imaging.
2. Utilizing in phase and out of phase sequences and calculating the OIR greatly assist in diagnosing

suspicious marrow lesions.

3. Utilizing this technique greatly reducing the need for Intravenous contrast administration.

References

1. Heindel W, Gübitz R, Vieth V, Weckesser M, Schober O, Schäfers M. The diagnostic imaging of bone metastases. *Dtsch Arztebl Int* 2014;111:741-747.
2. Sathiakumar N, Delzell E, Morrissey MA, Falkson C, Yong M, Chia V *et al.* Mortality following bone metastasis and skeletal-related events among women with breast cancer: a population based analysis of U.S. Medicare beneficiaries, 1999-2006. *Breast Cancer Res Treat* 2012;131(1):231-8.
3. Tanaka R, Yonemori K, Hirakawa A, Kinoshita F, Takahashi N, Hashimoto J *et al.* Risk factors for developing skeletal-related events in breast cancer patients with bone metastases undergoing treatment with bone-modifying agents. *Oncologist*. 2016.
4. Vande Berg BC, Lecouvet FE, Michaux L, Ferrant A, Maldague B, Malghem J. Magnetic resonance imaging of the bone marrow in hematological malignancies. *Eur Radiol* 1998;8:1335-1344.
5. Eito K, Waka S, Naoko N *et al.* Vertebral neoplastic compression fractures: assessment by dual-phase chemical shift imaging. *J Magn Reson Imaging* 2004;20:1020-24.
6. Gokalp G, Mutlu FS, Yazici Z, Yildirim N. Evaluation of vertebral bone marrow fat content by chemical-shift MRI in osteoporosis. *Skeletal Radiol* 2011;40:577-85.
7. Erly WK, Oh ES, Outwater EK. The utility of in-phase/opposed phase imaging in differentiating malignancy from acute benign compression fractures of the spine: *AJNR* 2006;27:1183-8.
8. Yu JS, Chung JJ, Kim JH, Kim KW, Fat-containing nodules in the cirrhotic liver: chemical shift MRI features and clinical implications, *Am. J Roentgenol* 2007;188:1009-1016.
9. Vande Berg BC, Malghem J, Lecouvet FE *et al.* Magnetic resonance imaging of normal bone marrow. *Eur Radiol* 1999;8(8):1327-34.
10. Disler DG, McCauley TR, Ratner LM *et al.* In-phase

- and out-of-phase MR imaging of bone marrow: prediction of neoplasia based on the detection of coexistent fat and water. *AJR Am J Roentgenol* 1997;169:1439-47.
11. Hoda A. El-Kareem A. El-Samie, Hosny Sayed A. El-Ghany. The value of added opposed/in phase MRI sequences in characterization of the focal vertebral bone marrow lesions in oncology patients, *The Egyptian Journal of Radiology and Nuclear Medicine* 2015;46(3):727-732.
 12. Khaleel Ibraheem Mohson, Qusay Tayser Naief, Farah Abdul Jalil. Differentiating Benign from Suspicious Vertebral Marrow Lesions Detected with Conventional Magnetic Resonance Imaging Using Apparent Diffusion Coefficient and Diffusion-Weighted Image, *Open Access Macedonian Journal of Medical Sciences* 2020;8(B):114-118.