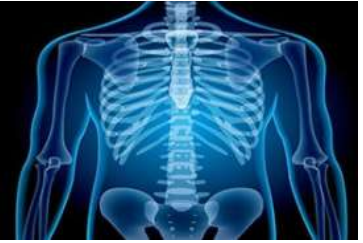

# International Journal of Radiology and Diagnostic Imaging



E-ISSN: 2664-4444  
P-ISSN: 2664-4436  
[www.radiologypaper.com](http://www.radiologypaper.com)  
IJRDI 2021; 4(3): 09-16  
Received: 06-04-2021  
Accepted: 16-06-2021

**Dr. Sathu Sri Sravya**  
Senior Resident, Department  
of Radiodiagnosis, Dr.  
Pinnamaneni Siddhartha  
Institute of Medical Sciences  
and Research Foundation,  
Chinnavutapalli, Gannavaram,  
Andhra Pradesh, India

**Dr. Chandra Sekhara Rao  
Kondragunta**  
Professor and HOD,  
Department of Radiodiagnosis,  
Dr. Pinnamaneni Siddhartha  
Institute of Medical Sciences  
and Research Foundation,  
Chinnavutapalli, Gannavaram,  
Andhra Pradesh, India

**Dr. Ashok Kumar Veerla**  
Senior Resident, Department  
of Radiodiagnosis, Dr.  
Pinnamaneni Siddhartha  
Institute of Medical Sciences  
and Research Foundation,  
Chinnavutapalli, Gannavaram,  
Andhra Pradesh, India

**Dr. Sai Keerthana Mikkilineni**  
Post Graduate, 2<sup>nd</sup> Year,  
Department of Radiodiagnosis,  
Dr. Pinnamaneni Siddhartha  
Institute of Medical Sciences  
and Research Foundation,  
Chinnavutapalli, Gannavaram,  
Andhra Pradesh, India

**Dr. Sai Siva Nageswara Rao  
Movva**  
Post Graduate, 2<sup>nd</sup> Year,  
Department of Radiodiagnosis,  
Dr. Pinnamaneni Siddhartha  
Institute of Medical Sciences  
and Research Foundation,  
Chinnavutapalli, Gannavaram,  
Andhra Pradesh, India

**Corresponding Author:**  
**Dr. Sathu Sri Sravya**  
Senior Resident, Department  
of Radiodiagnosis, Dr.  
Pinnamaneni Siddhartha  
Institute of Medical Sciences  
and Research Foundation,  
Chinnavutapalli, Gannavaram,  
Andhra Pradesh, India

## Evaluation of anatomical variants of sphenoid sinus by multidetector computed tomography

**Dr. Sathu Sri Sravya, Dr. Chandra Sekhara Rao Kondragunta, Dr. Ashok kumar Veerla, Dr. Sai Keerthana Mikkilineni and Dr. Sai Siva Nageswara Rao Movva**

**DOI:** <http://dx.doi.org/10.33545/26644436.2021.v4.i3a.214>

### Abstract

**Background:** Para nasal sinuses are air-filled cavities present in facial bones. Sinusitis is a common medical problem affecting millions of people annually. CT screening of paranasal sinuses has the advantages of showing bony details and good soft tissue outlines. CT is valuable in the identification of variations in pneumatization of sphenoid sinuses and characterization of sphenoid variations prior to FESS and trans-sphenoidal surgeries.

**Materials and Methods:** This was a cross-sectional study conducted at Dr. PSIMS & RF, Chinnavutapalli. This study was done on SIEMENS SOMATOM EMOTION 16 slice spiral CT machine. We included a total of 100 patients clinically diagnosed with chronic sinusitis, who were referred for CT scan of PNS in our hospital.

**Results:** Out of 100 patients, 52 males and 48 females. Most of the patients were in the 20-30 years age group comprising 55% of the study population. Presellar type of pneumatization found in (83%), Postsellar type of pneumatization (11%). Pneumatization of pterygoid process (42%), anterior clinoid process (28%), greater wing of sphenoid (22%). Bilateral protrusion of internal carotid artery (19 cases), right side (5 cases) and on left side (3 cases). Protrusion of optic nerve noted in 21 cases, among these 14 bilaterally, (4) right N and (3) left side, maxillary nerve protrusion (16 cases), among these 8 (bilaterally), (5) right and (3) left side, Vidian nerve protrusion (20 cases), among these (8) bilaterally, (7) right and (5) left side.

**Conclusion:** Computed Tomography plays an important role in visualization of variation in sphenoid sinus and its pneumatization patterns and has re-emphasized the concept that variations especially in the sphenoid sinus region is the key factor in the causation of accidental damage to vital structures like ICA, Optic nerve, Maxillary nerve and Vidian nerve.

**Keywords:** Paranasal sinuses, computed tomography, pneumatization, dehiscence, protrusion

### Introduction

Para nasal sinuses are air-filled cavities present in facial bones. Certain sinuses get pneumatized at certain age period. Among the entire sinuses maxillary sinus is the largest one and first sinus to develop. Sinusitis is a common medical problem affecting millions of people annually. First described over 2 decades ago <sup>[1]</sup>, functional endoscopic sinus surgery (FESS) has become the treatment of choice for patients with medically refractory Rhinosinusitis. FESS procedures are now performed more than 200,000 times per year approximately <sup>[2]</sup>, with published success rates of 76%-98% for primary FESS and 65%-78% for revision cases <sup>[3]</sup>. The sphenoid sinus is one of the most variable of all sinuses. Its relations to vital vascular and nervous elements make its approach a challenge for endoscopic surgeons <sup>[4]</sup>. These relations include the internal carotid artery, the optic nerve, the pituitary gland, the Vidian nerve and other vascular and nervous elements depending on the size of the sinus <sup>[5, 6]</sup>. Sphenoid sinus has close relation to the optic nerve, internal carotid artery, pituitary gland & vidian nerve. According to the extent of sinus pneumatization, the bone covering the carotid arteries, optic nerves, maxillary nerves, and vidian nerves can be thin or even absent, making these structures susceptible to iatrogenic injury <sup>[7]</sup>. There are multiple variations in septation, shape, and dimensions of the sphenoid sinus. High-resolution cranial tomographic scan may show pneumatization of the sphenoid sinuses from as early as 2 years of age <sup>[9-11]</sup>.

CT screening of paranasal sinuses has the advantages of showing bony details (using wide window settings) and good soft tissue outlines (using narrow window setting). Axial and coronal views may be useful for delineating the anatomical landmarks of the sinonasal cavity, but coronal CT scan provides most of the information required for an endoscopic clearance. Its advantage over axial CT scanning is that it shows progressively deeper structures as they are encountered by the surgeon during the operation (e.g., sphenoid sinus, in an antero-posterior direction) [7, 12]. CT is valuable in the identification of variations in pneumatization of sphenoid sinuses and characterization of sphenoid variations prior to FESS and trans-sphenoidal surgeries [8].

### Aims and Objectives

To evaluate the anatomical variations of sphenoid sinus by multidetector computed tomography.

### Materials and Methods

This was a cross-sectional study conducted at Dr. PSIMS & RF, Chinnavutapalli. This study was done on SIEMENS SOMATOM EMOTION 16 slice spiral CT machine. We included a total of 100 patients clinically diagnosed with chronic sinusitis, who were referred for CT scan of PNS in our hospital.

**Imaging protocol:** For coronal studies, patients were put in prone position. Taking the hard palate as reference axis, the plane of section was perpendicular to this structure. Direct scans of 0.6 mm in thickness were made from the anterior walls of the frontal sinuses to the posterior wall of the sphenoid sinus. The exposure settings used were 130 kVp and 80 to 100 mAs for giving less radiation without compromising on image quality.

### Results

Out of 100 patients, 52 males and 48 females. Most of the patients were in the 20-30 years age group comprising 55% of the study population. The commonest symptom being headache (64%) followed by nasal obstruction (53%) and nasal discharge (38%). Conchal type of pneumatization is very rare and, in our study, there is no conchal pneumatization found i.e. it was noted in 0%. In present study sellar type of pneumatization is more common which is found in 83%. Postsellar type of pneumatization was noted in 11% in present study. Pre sellar type of pneumatization was noted in 6% of cases in present study. Extension of pneumatization from sphenoid sinus to adjacent structures occurs. In present study pterygoid process pneumatization is common and was noted in 42%. Among these 23% noted bilaterally, 12% noted unilaterally on left side and 7% noted unilaterally on right side. Anterior clinoid process pneumatization seen in 28%. Among these bilateral anterior clinoid process pneumatization is seen in 17 cases, unilaterally on right side in 8 cases and left side in 5 cases. Greater wing of sphenoid pneumatization seen in 22 cases (22%). Among these bilateral greater wings of pneumatization is seen in 14 cases, unilaterally on right side in 5 cases and on left side in 3 cases. Protrusion of internal carotid artery is more common in present study. It is noted in 27 cases (27%). Among these bilateral protrusion of internal carotid artery noted in 19 cases, right side in 5 cases and on left side in 3 cases. Protrusion of optic nerve noted in 21 cases, among these 14 were noted bilaterally, 4 cases

noted on right side and 3 cases on left side. Maxillary nerve protrusion noted in 16 cases, among these 8 cases noted bilaterally, 5 cases noted on right side and 3 cases noted on left side. Vidian nerve protrusion noted in 20 cases, among these 8 cases noted bilaterally, 7 noted on right side and 5 noted on left side. Dehiscence is less common, when compared to protrusion. Dehiscence of ICA, optic nerve, maxillary nerve and vidian nerve are observed in present study. Dehiscence of optic nerve noted in 11 cases, among them 4 cases were noted bilaterally, 4 cases on right side and 3 cases on left side. Dehiscence of internal carotid artery is next common in present study. ICA dehiscence is seen in 13 cases, among them 8 were noted bilaterally, 3 on right side and 2 on left side. Dehiscence of maxillary nerve is noted in 8 cases, 3 bilaterally, 3 on right side and 2 on left side. Dehiscence of vidian nerve seen in 16 cases, among them 9 was noted bilaterally, 4 on right side and 3 on left side. Number of septae in sphenoid sinus can be variable, they can be absent septum, single, double or multiple septae in present study sphenoid sinuses with single septum are 72 cases, multiple septae are 19 cases and sphenoid sinus with absent septae are 9 cases.

### Discussion

The normal anatomical variations of the sphenoid sinus pneumatization (TABLE 5) and relations with adjacent structures are implicated in the etiology of accidental damage of vital structures like ICA, Optic nerve, Maxillary nerve & Vidian nerve. In this study Computed tomography images of a group of 100 patients were studied to evaluate anatomical variations of sphenoid sinus and its Pneumatization.

### Anatomy

The sphenoid sinus is the most posterior paranasal sinus. It lies antero-inferior to the sella. At birth, sphenoid sinus is a potential cavity, after development during puberty it reaches its original size. At first years of life, it extends backward into the presellar area and gradually expands into the area below and behind the sella turcica, and reaches its full-size during adolescence. During childhood, maturation of the bone from red to yellow marrow takes place in the anterior part of the sphenoid bone. Aoki *et al.* hypothesized that pneumatization promotes the conversion of the sphenoid marrow). Pneumatization widens inferiorly and posterolaterally and does not exceed the sphenoid-occipital synchondrosis. At 14 years of age, its expansion is completed but pneumatization proceeds slowly and completely ceases by the age of 25. Size and degree of pneumatization of sphenoid sinus is an important concern for the decision of surgery of sellar region. The types of the sphenoid sinus can be classified in three groups in the adult: I. conchal, II. presellar, III. sellar types and Postsellar (FIG 2), depending on the extent to which the sphenoid bone is pneumatized. In the conchal type, the area below the sella is a solid block of bone without an air cavity. In the presellar type (Fig 1), the sphenoid sinus has moderate air cavity with no sellar indentation.

The sellar type (Fig 3), which is the most common, the corpus of the sphenoid is well pneumatized with full indentation of the sella into the sinus and extends posteriorly until the clivus. The conchal type is most common in children and infrequent in the adult [13]. The pneumatization pattern of the sphenoid sinus is variable and can extend to

surround the anterior clinoid process (ACP), foramen rotundum, vidian canal, pterygoid process, or the maxilla-ethmoid process. The relations of the sphenoid sinus with structures around are close when the sinus is well pneumatized. When this happens, the surrounding vessels and nerves are seen in the sinus cavity as irregularities or ridges [14]. The sphenoid sinus may pneumatise the anterior clinoid processes. When present this pneumatization can encroach the optic nerve [15, 16]. The incidence of pneumatization in the anterior clinoid processes in literature is between 11% and 29.3% [17, 18]. The pneumatization of the sphenoid to the pterygoid processes is an extension of the sinus between the maxillary nerve and the nerve of the pterygoid canal (Vidian nerve). The internal carotid artery is the most medial element of the cavernous sinus, and it lies in direct relation to the lateral wall of the sphenoid sinus.

**Sphenoid pneumatization**

In our study, Conchal type of pneumatization is very rare 0%. Sellar type of pneumatization is more common, which was evident even in other studies. In present study sellar type of pneumatization is found in 83%. Post sellar pneumatization is next common variety. Post sellar type of pneumatization was noted in 11% in present study. Presellar type of pneumatization was noted in 6% of cases in present study. The studies done by showed the most common variant as sellar type Budu. *et al.* sellar 65%, Hamid. O. *et al.* sellar 54% and Nathan *et al.* sellar 54%, which coincides with our study results.

**Extension of sphenoid pneumatization**

Extension of pneumatization from sphenoid sinus to adjacent structures occurs. In present study pterygoid process pneumatization was noted in 42% among these 23% noted bilaterally, 12% noted unilaterally on left side (Fig 6) and 7% noted unilaterally on right side (Fig 4). Anterior clinoid process pneumatization is next most common in present study; it is associated with optic nerve protrusion. Anterior clinoid process pneumatization (Fig 7) seen in 28% among this bilateral anterior clinoid process pneumatization is seen in 17 cases, unilaterally on right side (Fig 4) in 8 cases and left side in 5 cases. Greater wing of sphenoid pneumatization seen in 22 cases (22%) among these bilateral greater wings of pneumatization is seen in 14 cases, unilaterally on right side (Fig 5) in 5 cases and on left side in 3 cases. In a study done by Rudresh *et al.* extension of pneumatization to Pterygoid process was 31%, to anterior clinoid process was 15% and to Greater wing of sphenoid was 12.7%. In a study done by Hewaidi. *et al.* extension of pneumatization to Pterygoid process was 29%, anterior Clinoid process was 15.3% and to Greater wing of sphenoid was 20%. In a study done by Budu *et al.* extension of pneumatization to Pterygoid process was 39%, anterior clinoid process was 29% and greater wing of sphenoid was 0%. This comparison of studies with study results shows greater correlation with the existing studies.

**Protrusion of adjacent vital structures**

Protrusion of internal carotid artery (Table 2) is more common in present study. It is noted in 27 cases (27%). Among these bilateral protrusion of internal carotid artery (Fig 14) noted in 19 cases, right side in 5 cases and on left side in 3 cases. Protrusion of optic nerve (Table 1) noted in

21 cases, among these 14 were noted bilaterally, 4 cases noted on right side and 3 cases on left side. Maxillary nerve protrusion (Table 3) noted in 16 cases, among these 8 cases noted bilaterally (Fig 12), 5 cases noted on right side and 3 cases noted on left side. Vidian nerve protrusion (Table 4) noted in 20 cases, among these 8 cases noted bilaterally (Fig 11), 7 noted on right side and 5 noted on left side. In a study done by Sareen. *et al.* the protrusion of internal carotid artery was 36%, optic nerve was 30%, maxillary nerve was 19.7% and vidian nerve was 23.1%. This study shows good correlation of results with the existing studies.

**Dehiscence adjacent vital structures**

Dehiscence of optic nerve (FIG 8) noted in 11 cases, among them 4 cases were noted bilaterally, 4 cases on right side and 3 cases on left side. Dehiscence of internal carotid artery is next common in present study. ICA dehiscence (Fig 15) is seen in 13 cases, among them 8 were noted bilaterally, 3 on right side and 2 on left side. Dehiscence of maxillary nerve (Fig 13) is noted in 8 cases, 3 bilaterally, 3 on right side and 2 on left side. Dehiscence of vidian nerve (Fig 11) seen in 16 cases, among them 9 was noted bilaterally, 4 on right side and 3 on left side. In a study done by Rudresh *et al.* The dehiscence of internal carotid artery was 03%, optic nerve was 05%, maxillary nerve was 2.75% and vidian nerve was 3.75%. In a study done by Hewaidi *et al.*, the dehiscence of internal carotid artery was 30% optic nerve was 30% maxillary nerve was 13% and vidian nerve was 37%. In a study done by fasunla. AJ *et al.*, the dehiscence of internal carotid artery was 10.7% optic nerve was 13% maxillary nerve was 00% and vidian nerve was 00%. These studies signify the better correlation of my study to the existing studies.

**Sphenoid sinus septum**

Number of septae in sphenoid sinus can be variable. They can be absent septum (Fig 20), single, double or multiple septae. In present study sphenoid sinuses with single septum (Fig 16) are 72 cases, multiple septae (Fig 17) are 19 cases and sphenoid sinus with absent septae are 9 cases. In a study done by fasunla *et al.*, the sphenoid septum was present in 97.3% and absent in 12.7%. Hewaidi *et al.* shows 89.2% presence and 10.8% absence. Nathan *et al.* shows 96% presence and 04% absence. Sareen *et al.* shows 100% presence and 00% absence. Present study correlates well with all the mentioned existing studies.

**Relationship between pneumatization of ACP and on protrusion**

Concomitant presence of a pneumatized ACP and a protruding ON was encountered in 21 cases. Chi square test indicated significant association between ACP pneumatization and ON protrusion. ( $\chi^2 = 63.9$  with 1 degree of freedom  $p < 0.001$ ).

**Table 1:** Relationship between pneumatization of ACP and on protrusion

Anterior clinoid process pneumatization	Optic nerve protrusion (ONP)				Total
	Present (ON+)		Not present (ON-)		
	Number	%	Number	%	
Present (ACP+)	21	75	7	25	28
Not seen (ACP-)	0	0	72	100	72
Total	21		79		100

**Relationship between pneumatization of ACP and ICA protrusion**

Concomitant presence of a pneumatized ACP and a protruding ICA was encountered in 25 cases. Chi square test indicated significant association between ACP pneumatization and ICA protrusion. ( $\chi^2 = 72.2$  with 1 degree of freedom,  $p < 0.001$ ).

**Table 2:** Relationship between pneumatization of ACP and ICA protrusion

Anterior clinoid process pneumatization	Internal carotid artery protrusion (ICAP)				Total
	Present (IC+)		Not present (IC-)		
	Number	%	Number	%	
Present (ACP+)	25	89.2%	3	10.8%	28
Not seen (ACP-)	2	2.7%	70	97.3%	72
Total	27		73		100

**Relationship between GWS pneumatization & maxillary nerve protrusion (MNP)**

Concomitant presence of a pneumatized GWS and a

protruding maxillary nerve was encountered in 25 cases. Chi square test indicated significant association between GWS pneumatization and MN protrusion. ( $\chi^2 = 62.2$  with 1 degree of freedom,  $p < 0.001$ ).

**Relationship between PP pneumatization & vidian nerve protrusion (VNP)**

Concomitant presence of a pneumatized GWS and a protruding maxillary nerve was encountered in 20 cases. Chi square test indicated significant association between GWS pneumatization and MN protrusion. ( $\chi^2 = 30.6$  with 1 degree of freedom,  $p < 0.001$ ).

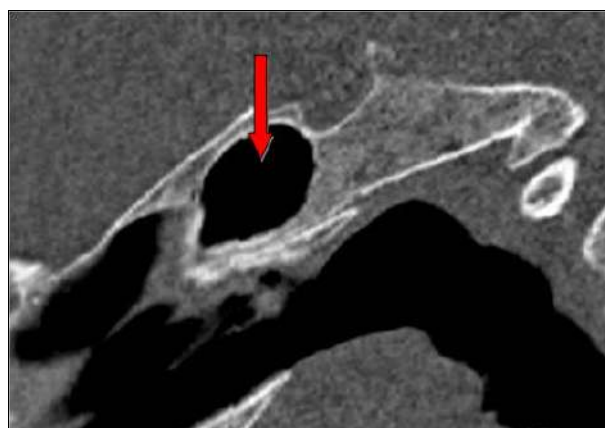
**Table 3:** Vidian nerve protrusion

Pterygoid process pneumatization	Vidian nerve protrusion (VNP)				Total
	Present (VNP+)		Not present (VNP-)		
	Number	%	Number	%	
Present (PP+)	20	45%	22	55%	42
Not seen (PP-)	0	0	58	100%	58
Total	20		80		100

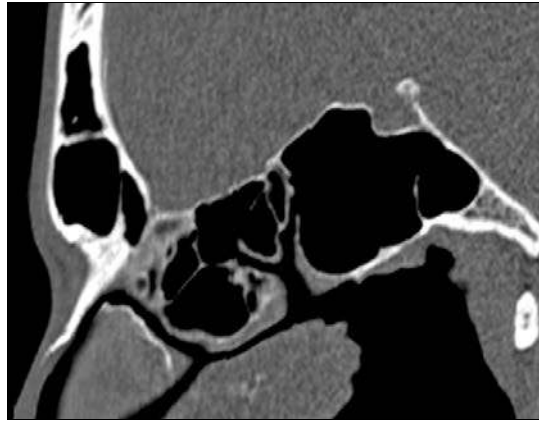
**Table 4:** Comparison of outcome of various studies on anatomical variations in sphenoid sinus on CT

		Present study	Fasunla AJ <i>et al.</i>	Budu <i>et al.</i>	Haid O <i>et al.</i>	Rudresh <i>et al.</i>	Hewaidi GH <i>et al.</i>	Nathan <i>et al.</i>	Sareen D <i>et al.</i>
Year		2015	2012	2013	2008	2010	2011	2014	2008
Sphenoid pneumatization	Conchal	00%		02%	02%			00%	00%
	Sellar	83%		65%	54%			37%	40%
	Post sellar	11%		23%	22%			54%	55%
	Pre sellar	06%		10%	21%			09%	05%
Extension of pneumatization	Pterygoid	42%		39%		31%	29%		
	Ant-clinoid	28%	14.5%	29%		15%	15.3%		
	Greater wing of sphenoid	22%			15.9%	12.7%	20%		
Protrusion	ICA	27%	27.3%	34%		7%	41%		36%
	ON	21%	38.2%			10%	35.7%		30%
	MN	16%				12%	24.3%		19.7%
	VN	20%				31.2%	27%		23.1%
Dehiscence	ICA	13%	10.9%	04%		3%	30%		
	ON	11%	13.6%			5%	30%		
	MN	08%				2.75%	13%		
	VN	16%				3.75%	37%		
Septum	Present	91%	97.3%		89.2%			96%	100%
	Absent	09%	2.7%		10.8%			04%	00%

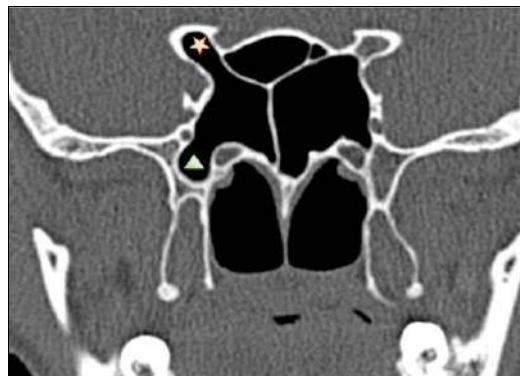
**Figures**



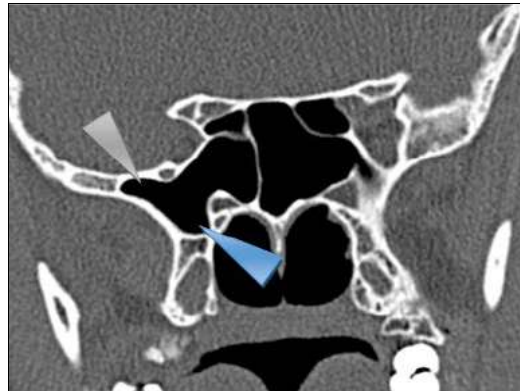
**Fig 1:** Pre sellar type of pneumatization



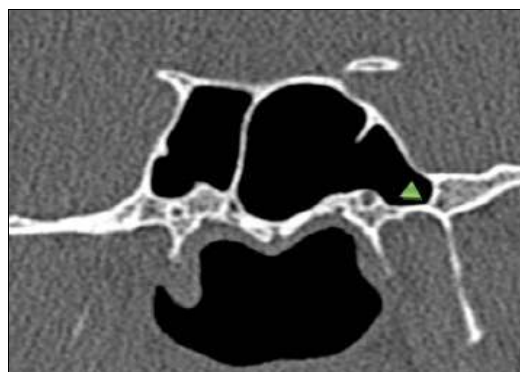**Fig 2:** Post sellar pneumatisation



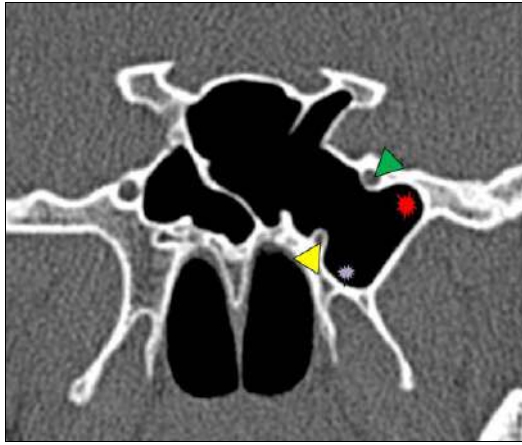
**Fig 3:**  
★ Right anterior clinoid process pneumatisation.  
▲ Right pterygoid process pneumatisation.



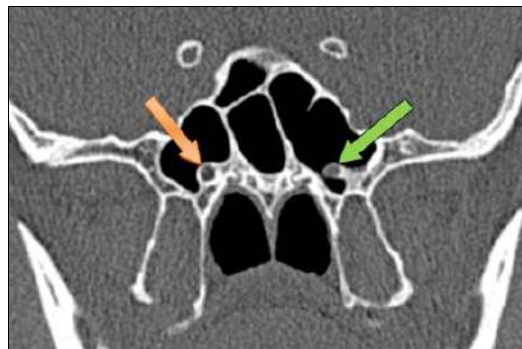
**Fig 4:**  
▶ Greater wing of sphenoid pneumatisation on right side.  
▶ Pterygoid process pneumatisation on right side.



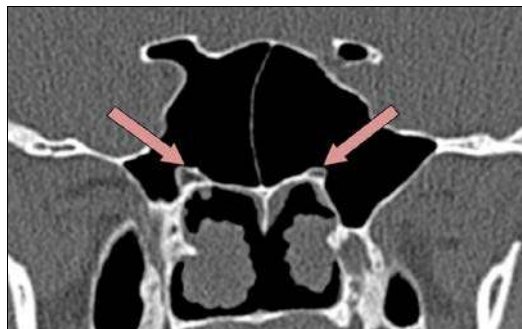**Fig 5:** Left pterygoid process pneumatisation



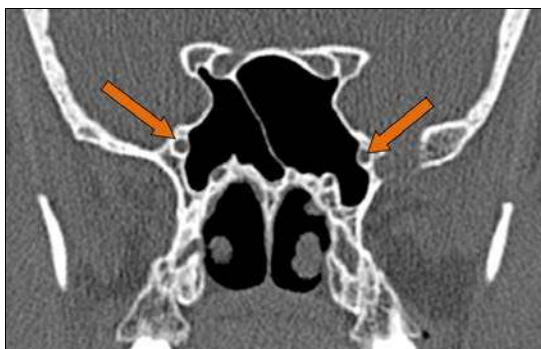
**Fig 6:**  
★ Greater wing of sphenoid pneumatization  
▶ Maxillary nerve protrusion  
★ Pterygoid process pneumatization  
▶ Vidian nerve protrusion



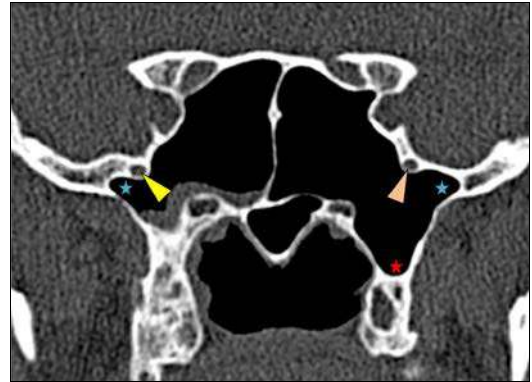
**Fig 7:**  
➔ Vidian nerve dehiscence  
➔ Vidian nerve protrusion



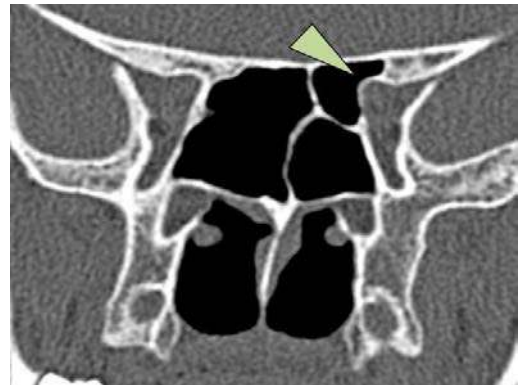**Fig 8:** Bilateral vidian nerve protrusion



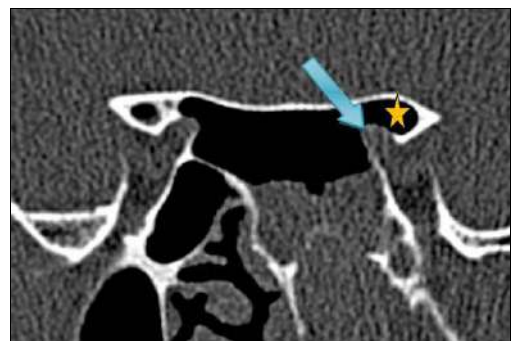
**Fig 9:** Bilateral maxillary nerve protrusion



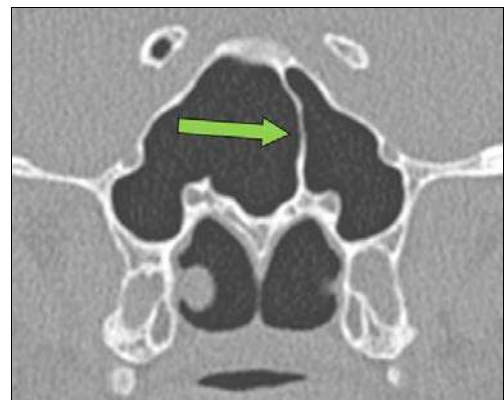
**Fig 10:**  
▶ Maxillary nerve protrusion  
▶ Maxillary nerve dehiscence  
★ Greater wing of sphenoid pneumatization  
★ Pterygoid process pneumatization



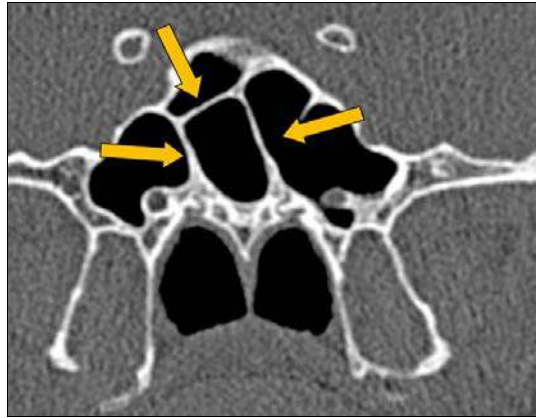
**Fig 11:**  
▶ Internal carotid artery protrusion



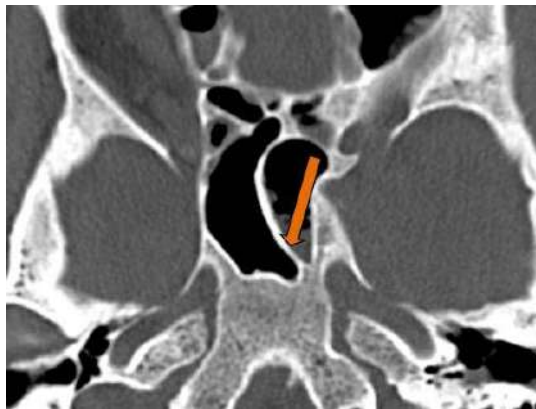**Fig 12:**  
Internal carotid artery dehiscence  
★ ACP pneumatization



**Fig 13:** Single septum



**Fig 14:** Multiple septa



**Fig 15:**

→ Septum attached to bone adjacent to ICA

### Conclusion

This study has demonstrated that Computed Tomography plays an important role in visualization of variation in sphenoid sinus and its pneumatization patterns and has re-emphasized the concept that variations especially in the sphenoid sinus region is the key factor in the causation of accidental damage to vital structures like ICA, Optic nerve, Maxillary nerve and Vidian nerve. It helps in evaluating the complex anatomy of paranasal sinuses which is not possible with plain radiographs. Improvement in FESS and CT technology has concurrently increased interest in the sphenoid sinus anatomy, pneumatization and its variations. The radiologist must pay close attention to variants of sphenoid sinus and its pneumatization patterns in the preoperative evaluation as it is important for the surgeon to be informed of these variations, protrusion/dehiscence of ICA, Optic nerve, Maxillary nerve and Vidian nerve which may predispose patients to increased risk of intra-operative complications/recurrent failures thereby helping avoid possible complications and accidental damage to vital structures.

### References

- Kennedy DW, Zinreich SJ, Rosenbaum AE, Johns ME. Functional endoscopic sinus surgery: theory and diagnostic evaluation. *Arch Otolaryngol* 1985;111(9):576-582.
- Gross CW, Schlosser RJ. Prevalence and economic impact of rhinosinusitis. *Curr Opin Otolaryngol Head Neck Surg* 2001;9(1):8-10.6.
- Musy PY, Kountakis SE. Anatomic findings in patients undergoing revision endoscopic sinus surgery. *Am J Otolaryngol* 2004;25(6):418-422.
- Wormald PJ. The agger nasi cell: the key to understanding the anatomy of the frontal recess, *Otolaryngology- Head and Neck Surgery* 2003;129(5):497-507.
- Budu V, Carmen Aureliya Mogoant, Fanut B. The anatomical relations of the sphenoid sinus and their implications in sphenoid endoscopic surgery. *Rom J Morphol Embryol* 2013;54(1):13-16.
- Hewaidi GH1, Omami GM. Anatomic Variation of Sphenoid Sinus and Related Structures in Libyan Population: CT Scan Study Libyan *J Med* 2007;19(21):128-133.
- Janskowski R, Auque J, Simon C. Endoscopic pituitary tumor surgery. *Laryngoscope* 1992;102:198-203.
- Uma Devi, Murali Appavoo Reddy, Bhawna Dev. Pictorial essay: Anatomical variations of paranasal sinuses on multidetector computed tomography-How does it help FESS surgeons? *Indian Journal of Radiology and Imaging* 2012;22(4):317-324.
- Kainz J, Stammberger H. Danger areas of the posterior rhinobasis. An endoscopic and anatomical-surgical study. *Actaotolaryngol* 1992;122:852-861.
- Arsalan H, Aydinlioglu A, Bozkurt M *et al.* Anatomic variations of the paranasal sinuses: CT examination for endoscopic sinus surgery. *Auris Nasus Larynx* 1997;26:39-48.
- Zinreich J. Functional anatomy and computed tomography imaging of the paranasal sinuses. *Am J Med Sci* 1998;316:2-1.

12. Kaluskar SK, Patil NP, Sharkey AN. The Role of CT Scan in Functional Endoscopic Sinus Surgery. *Rhinology* 1993;31(2):49-52.
13. Baskin JZ, Kuriakose MA, Lebowitz RA. The anatomy and physiology of the sphenoid sinus. *Oper. Tech. Otolaryngol* 2003;14(3):168-72.
14. Hoseman W, Gross R, Göde U, Kühnel T, Röckelein G. The anterior sphenoid wall: relative anatomy for sphenoidotomy, *Am J Rhinol* 1995;9(3):137-144.
15. Climelli D, Contributo Alla Morfologia Del Seno Sphenoidale, *Oto-rino-laringol Ital* 1939;9:81-86.
16. Vidić B. The postnatal development of the sphenoidal sinus and its spread into the dorsum sellae and posterior clinoid processes, *Am J Roentgenol Radium Ther Nucl Med* 1968;104(1):177-183.
17. Citardi MJ, Gallivan RP, Batra PS, Maurer CR Jr, Rohlfing T, Roh HJ *et al.* Quantitative computer-aided computed tomography analysis of sphenoid sinus anatomical relationships, *Am J Rhinol* 2004;18(3):173-178.
18. Sapçı T, Derin E, Almaç S, Cumali R, Saydam B, Karavuş M. The relationship between the sphenoid and the posterior ethmoid sinuses and the optic nerves in Turkish patients, *Rhinology* 2004;42(1):30-34.