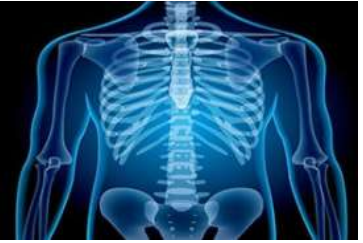

International Journal of Radiology and Diagnostic Imaging



E-ISSN: 2664-4444
P-ISSN: 2664-4436
www.radiologypaper.com
IJRDI 2021; 4(4): 19-27
Received: 25-07-2021
Accepted: 22-09-2021

Dr. Lalit Kumar
Junior Resident, Department
of Radiodiagnosis, Subharti
Medical College, Meerut, U.P.,
India

Dr. BB Thukral
Professor and Head,
Department of Radiology,
Subharti Medical College,
Meerut, U.P., India

Dr. Sunil Malhotra
Associate Professor,
Department of Orthopedic,
Subharti Medical College,
Meerut, U.P., India

Dr. Akanksha Singh
Assistant Professor,
Department of Radiology,
Subharti Medical College,
Meerut, U.P., India

Corresponding Author:
Dr. Lalit Kumar
Junior Resident, Department
of Radiodiagnosis, Subharti
Medical College, Meerut, U.P.,
India

Role of MRI in the evaluation of spinal trauma

Dr. Lalit Kumar, Dr. BB Thukral, Dr. Sunil Malhotra and Dr. Akanksha Singh

DOI: <http://dx.doi.org/10.33545/26644436.2021.v4.i4a.235>

Abstract

Aim: Role of MRI in the Evaluation of Spinal Trauma.

Material and methods: The present prospective observational study was on 50 patients with clinical suspicion of spinal trauma referred to Department of Radio diagnosis, from OPD/IPD of C.S.S.Hospital, Subharti Medical College, Meerut. After obtaining clinical history relevant clinical examination was done. MRI examinations were done on GE – Signa HD contour GE 1.5 Tesla Feiloversikt, whole body MR scanner with sense surface coil and then evaluation of M R Imaging was done by using different pulse sequences. The findings were viewed in the light of complete clinical and radiographic data.

Results: 78% subjects were male, hence there was male preponderance with age group of 31-40 years with compression fracture in 72% & retropulsion of vertebral body. Spinal cord oedema was found among 78% with maximum no of cases, having cord oedema >3 cm. AIS grade A, B, C, D and E was found among 20%, 20%, 16%, 22% and 22% of cases respectively. Sensory & Motor loss in 24% & 74% of cases. Sensory loss was corresponded with level of spinal cord oedema & level of vertebrae fracture.

Discussion: MRI plays a crucial role in evaluating and detecting spinal trauma. Subtle bone marrow, soft-tissue, and spinal cord abnormalities, which may not be apparent on other imaging modalities, can be readily detected on MRI. Early detection often leads to prompt and accurate diagnosis, expeditious management, and avoidance of unnecessary procedures. The depiction of parenchymal SCI on MRI not only correlates well with the degree of neurologic deficit, but it also bears significant implications in regard to prognosis and potential for neurologic recovery.

Conclusion: With this study we concluded that MRI findings in spinal trauma correlate with the clinical findings according to ASIA impairment scale and can be helpful to clinician in predicting the outcome.

Keywords: magnetic resonance imaging and ASIA impairment Scale

Introduction

The vertebral column, also called the spinal column, spine, or backbone, in vertebrate animals is the flexible column that houses the spinal cord extending from neck to tail, made of series of bones, the vertebrae. In human vertebral column, there are 33 vertebrae divided into cervical (C1-C7) (C1-Atlas, C2-Axis), thoracic (T1- T12), lumbar (L1-L5), sacral (S1-S5 fused) and coccyx (3-5 segments) ^[1]. It is a part of the axial skeleton and the most important function of the spine is to protect the spinal cord, which is the nerve supply for the entire body originating in the brain.

To evaluate the spinal trauma, the lesion can be correctly identified by the radiologist and further damage to the patient can be arrested. Injury is said to be acute if it has occurred within 3 weeks of diagnosis and thus have to be considered as fresh injuries. They may cause damage at not only one but at many site of the spinal cord. Thus, early detection of the spinal injury results in better prognosis. Radio-imaging is one of the most important tools in the diagnosis of spinal injury and helps to start a prompt and correct treatment to patients ^[2].

In major trauma patients, the cervical spine is mostly injured. Falls are the most important cause followed by motor vehicle accidents and violent acts. Traumatic spine injury occurs mostly in males in their teens or twenties. More than half of cord injuries occur in the cervical spine region, a third in the thoracic region and the remainder in the lumbo-sacral region. Quadriplegia is one of the most devastating consequences of cervical spine trauma ^[3].

The imaging evaluation of spinal cord injury (SCI) has undergone a remarkable evolution with the development of Magnetic Resonance Imaging. Although plain radiographs, myelography and computed tomography were once the mainstay of spinal imaging, the MRI has recently become a necessity in the management of SCI. The vertebral column, spinal cord, and adjacent soft tissue structures and neural compression can directly be imaged by MRI. The information provided by MR imaging has radically changed our abilities to access the patient in the emergent period and has altered our understanding of pathophysiology of SCI and its prognosis. With this background, the present study is aimed to review the magnetic resonance characteristics in prospective evaluation of SCI, and to assess the potential impact of MR imaging in the management of spinal axis trauma [4].

MRI has been playing an increasingly important role in the management of spinal trauma patients due to its increased availability in the emergency settings and its inherently superior contrast resolution. Notably, MRI is the modality of choice for evaluation of soft tissue structures including the intervertebral disc, the ligaments, the epidural space, the blood vessels, the spinal cord and occult osseous injuries. Imaging plays a critical role in diagnosis of acute spinal trauma and helps in initiating prompt and accurate treatment in these patients [5].

The main indications of MRI in spinal trauma include [5].

1. To identify spinal cord abnormalities in patients with impaired neurological status.
2. To exclude clinically suspected ligamentous or occult bony injuries in patients with negative radiographs.
3. To determine the stability of the cervical spine and assess the need for cervical collar in obtunded trauma patients.
4. To differentiate between haemorrhagic and nonhemorrhagic spinal cord injuries for the prognostic significance as the presence of hemorrhage significantly worsens the final clinical outcome.
5. To look for epidural hematoma or disc herniation before attempting a closed reduction of cervical facet dislocations.
6. Radiographic and/or CT scan findings suggestive of ligamentous injury, such as prevertebral hematoma, spondylolisthesis, asymmetric disc space widening, facet joint widening or dislocations, and inter-spinous space widening.

The grading is done by using ASIA impairment scale [6] which as follows:

- A. Complete: No motor or sensory function is preserved in the sacral segments S4- S5.
- B. Incomplete: Sensory but not motor function preserved below the neurologic level and includes the sacral segments S4-S5.
- C. Motor function is preserved below the neurologic level, and more than half of the key muscles below the neurologic level have a muscle grade less than 3.
- D. Incomplete: Motor function is preserved below the neurologic level, and at least half of key muscles below the neurologic level have a muscle grade of 3 or more.
- E. Normal: Motor and sensory function are normal.

Considering the advantages of MRI as an excellent diagnostic modality for evaluation of spinal trauma, it was

possible to suggest that the MRI findings correlated directly with the severity of injury. The purpose of this study was to evaluate the role of MRI in evaluation of spinal trauma to assess the severity of injury and to analyze the correlation of imaging and clinical findings.

Material and methods

The present prospective observational study was on 50 patients with clinical suspicion of spinal trauma referred to Department of Radio diagnosis, Imaging and interventional radiology from OPD/IPD of C.S.S. Hospital, under the age is of N.S.C.B Subharti Medical College, Meerut. After obtaining clinical history relevant clinical examination was done. MRI examinations were done on GE – Signa HDe contour GE 1.5 Tesla Feiloversikt, whole body MR scanner with sense surface coil and then evaluation of M R Imaging was done by using different pulse sequences. The findings were viewed in the light of complete clinical and radiographic data.

Setting: Department of Radio diagnosis, Imaging & Interventional radiology N.S.C.B. Subharti Medical College, CSS Hospital, Meerut.

Type of Study: Prospective observational study.

Sample Size: The study was conducted on minimum of 50 patients.

Duration of Study: The source of data for this study was patients referred to Department of Radio diagnosis, Imaging and Interventional radiology from OPD/IPD of C.S.S. Hospital, Subharti Medical College, Meerut for a period of 2 years, from October 2019 to August 2021.

Inclusion Criteria

Patients across all age groups referred to the radiology department with clinical suspicion of spinal trauma were included in the present study.

Exclusion Criteria

1. Patients with cardiac pacemakers, ferromagnetic aneurysm clips, other ferromagnetic implants (Ex: cochlear implants), intraocular metallic foreign bodies were excluded.
2. Patients with claustrophobia were also excluded.

Procedure: After obtaining clinical history relevant clinical examination was done. ASIA grading was done for neurological injury. MRI examinations was done on GE – Signa HDe contour GE 1.5 Tesla Feiloversikt, whole body MR scanner with sense surface coil and then evaluation of M R Imaging was done as per departmental protocols. Author correlate MRI findings directly with the degree of weakness according to ASIA (American Spinal Injury Association) impairment scale [7].

Positioning: Every patient lay in supine position with quiet breathing. No movement was allowed during examination. It was specially taken care of that adequate stabilization of spine specially cervical was done prior to and during imaging.

Protocol of MR imaging: Patients included in the study

were subjected to routine MRI of the spine by following pulse sequences as indicated: Sagittal T1 F, T2 F, T2 FrF, STIR, PD FS & Axial T1 FSE, T2 frFS, PD FS, 3D FSPG & Coronal STIR, PD F, T1 SE & Myelo SAG.

Slice thickness: 5.0/1.0 mm

Matrix: 352X256

Number of excitation: 4

Field of view: 35X35 mm

The findings were viewed in the light of complete clinical

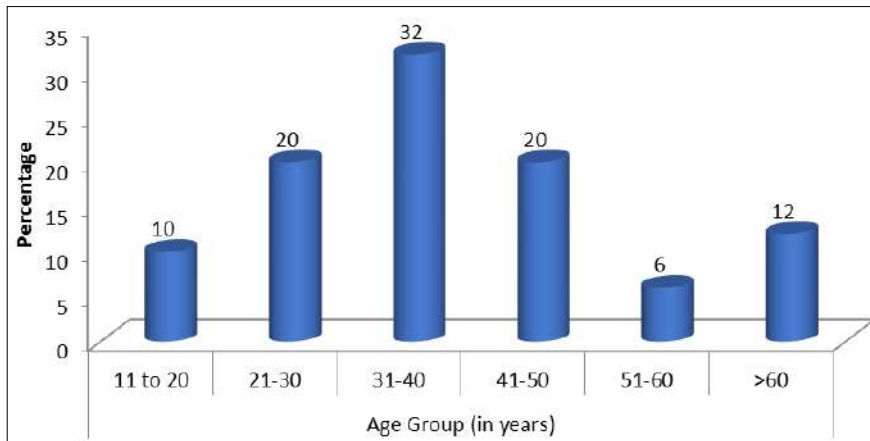
and radiographic data.

Statistical analysis

Data was collected and subjected to statistical analysis using SPSS software version 24.

Results

78% of the subjects were male, hence there was male preponderance with age group of 31-40 years (32%) (Graph1) with History of fall and road traffic accident (RTA) was reported among 68% and 32% of the subjects respectively.



Graph 1: Age distribution among the study subjects

Burst fracture, compression fracture and posterior element was reported among 22%, 72% and 30% of the subjects respectively. (Table1& Graph2) Anteropulsion and retropulsion was reported among 6% and 44% respectively. Lamina, Pedicle, both lamina & pedicle and Spinous process fracture were reported among 17.6%, 23.6%, 11.8% and 47 % respectively.

Table 1: Part and Type of vertebrae involved in fracture among the study subjects

S. No.	Vertebral Body	No. of cases	%
1.	Burst Fracture	11	22
	Compression Fracture	36	72
2.	Posterior Element	15	30

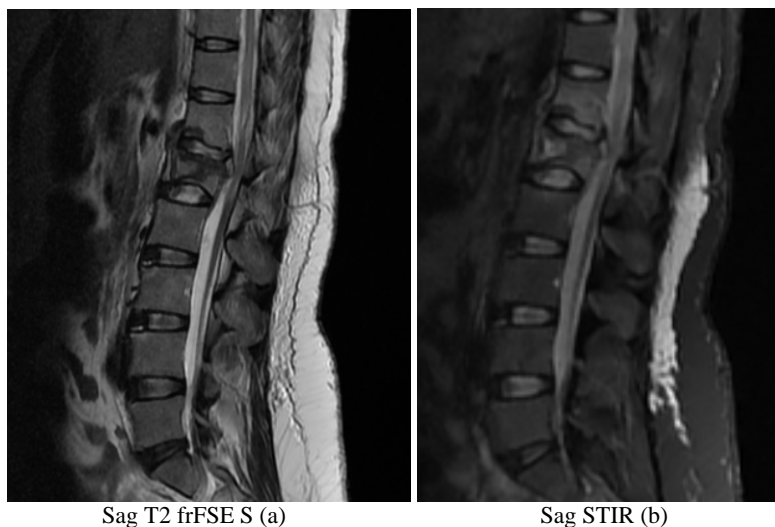

Fig 1: A 30 year old female with history of fall from height presented with numbness and tingling. Sag T2 frFSE S (a) Burst compression fracture with partial collapse & reduced height of L1 vertebral body is seen with small retropulsed posteriorly displaced fractured fragment compressing the thecal sac and spinal canal at that level. A short segment of spinal cord is seen showing T2/STIR hyperintensity at the level of D12-L1 vertebral bodies – suggestive of acute cord contusion/myeloedema. Fracture of inferior end plate of D12 vertebral body is seen. Sag STIR (b) STIR hyperintensity seen in D12 & L1 vertebral bodies extending to posterior elements and intervening intervertebral disc – suggestive of bone marrow edema and disc edema. Thin rim of fluid is seen in prevertebral and epidural regions – suggestive of collection (hematoma).

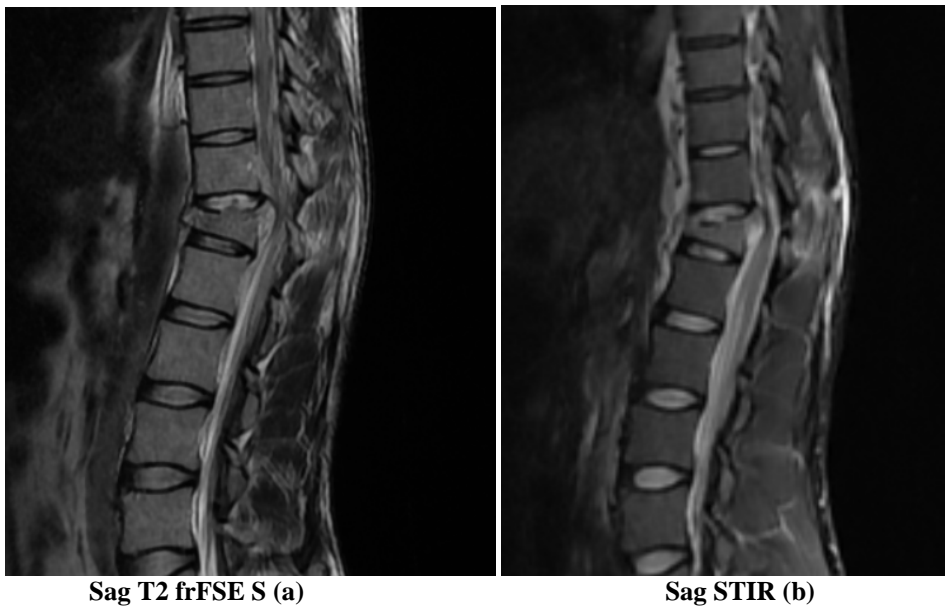
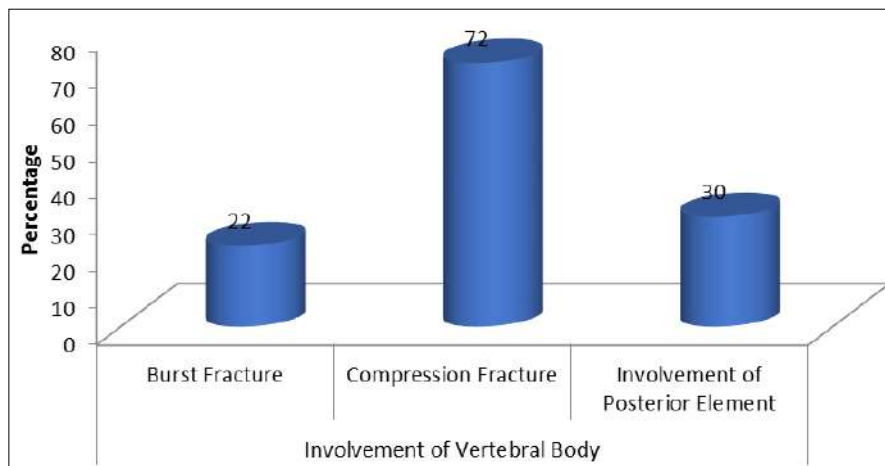


Fig 2: A 37 year old male with history of fall of heavy object at back.
 Sag T2 frFSE S (a) There is compression fracture with central and anterior wedging of D12 vertebral body seen with partial collapse and small fractured fragment displaced anteriorly. The posteriorly displaced vertebral body is compressing the thecal sac and spinal canal. Sag STIR (b) STIR hyperintensity seen in D12 vertebral body – suggestive of bone marrow edema. Subtle T2/STIR hyperintensity seen in small segment of dorsal cord at that level - suggestive of acute cord contusion/myeloedema. STIR hyperintensity also seen in D12 vertebral body D11-D12 intervertebral disc – suggestive of disc edema. Small collection is seen in prevertebral and epidural region s/o hematoma.



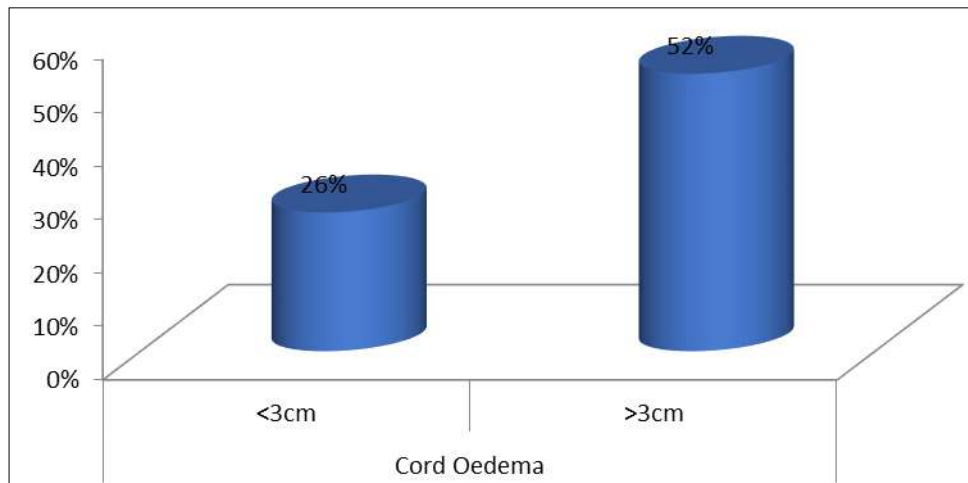
Graph 2: Involvement of Vertebral Body

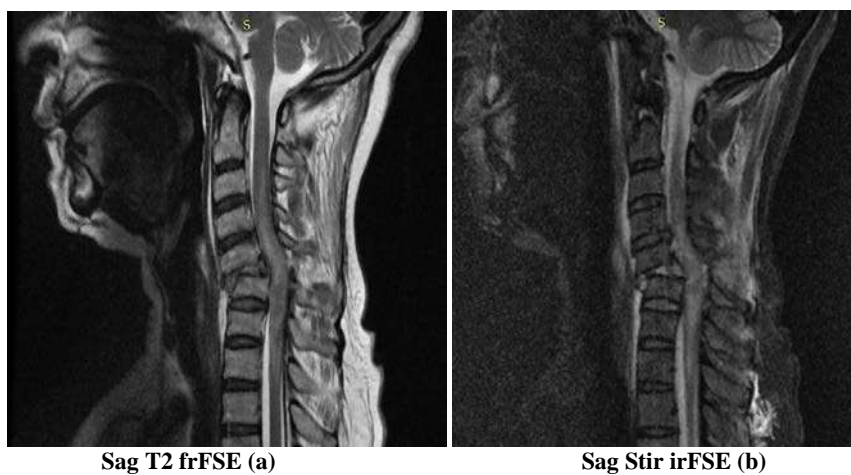

Fig 3: 60 year old female with history of fall from staircase, Sag T2 frFSE (a) Anterolisthesis of the C5 over C6 vertebral body is noted with loss of cervical lordosis with disruption of facet joint at that level with narrowing of spinal canal with compression of spinal cord at that level. Sag Stir irFSE(b) long segment area of altered signal intensity appearing hyperintense on T2 and STIR extending from the level of upper border of C3 vertebra to lower border of D1 vertebra – suggestive of myeloedema.

Spinal cord haemorrhage was present among 4% of the study subjects. Spinal cord oedema was found among 39 (78%) study subjects. Out of 39 subjects, 13 (26%) were

having cord oedema <3 cm and 26 (52%) were having cord oedema >3 cm. (Graph3)



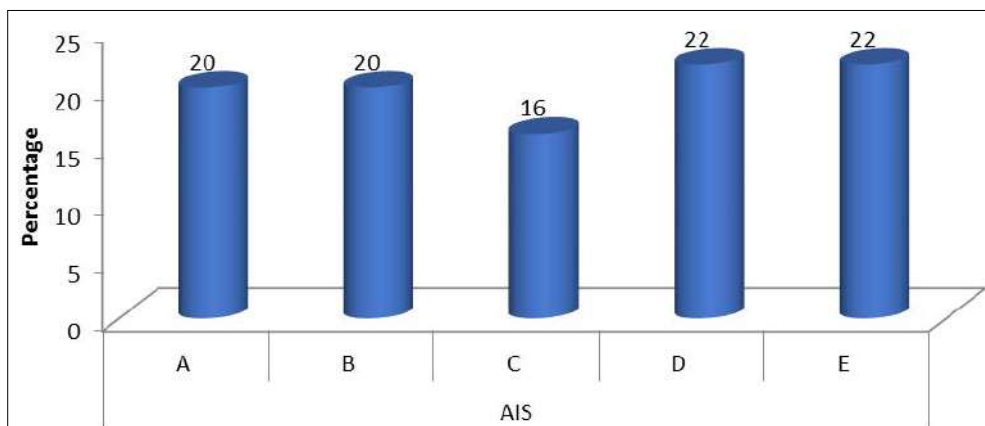
Graph 3: Cord Oedema

Normal and abnormal spinal cord was revealed among 80% and 20% of the subjects respectively. AIS grade A, B, C, D

and E was found among 20%, 20%, 16%, 22% and 22% of the study subjects respectively. (Table 2 & Graph4)

Table 2: AIS among the study subjects

AIS	No. of cases	%
A	10	20
B	10	20
C	8	16
D	11	22
E	11	22
Total	50	100



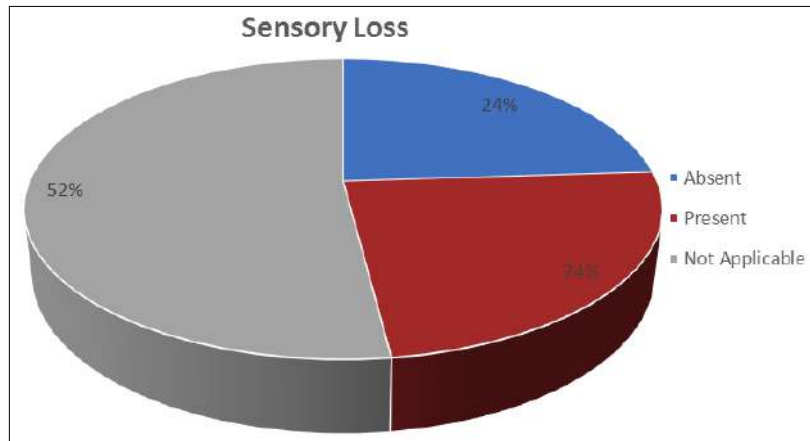
Graph 4: AIS among the study subjects

50% and 50% of the subjects with cord haemorrhage were having AIS grade A and E respectively at admission. 23%, 34.7%, 23%, 19.3% and 0% of the subjects with cord oedema >3cm were having AIS grade A, B, C, D and E respectively. 25%, 25%, 20%, 25% and 5% of the subjects with abnormal spinal cord were having AIS grade A, B, C, D and E respectively. Sensory loss was noted among 24% of the study subjects. Motor loss was absent and present among 26% and 74% of the subjects respectively. Sensory loss was found in 58.4%, 16.65%, 8.3%, 16.65% and 0% of the subjects with grade A, B, C, D and E respectively and level of dermatome involved in sensory loss was correspond with level of spinal cord oedema & level of vertebrae

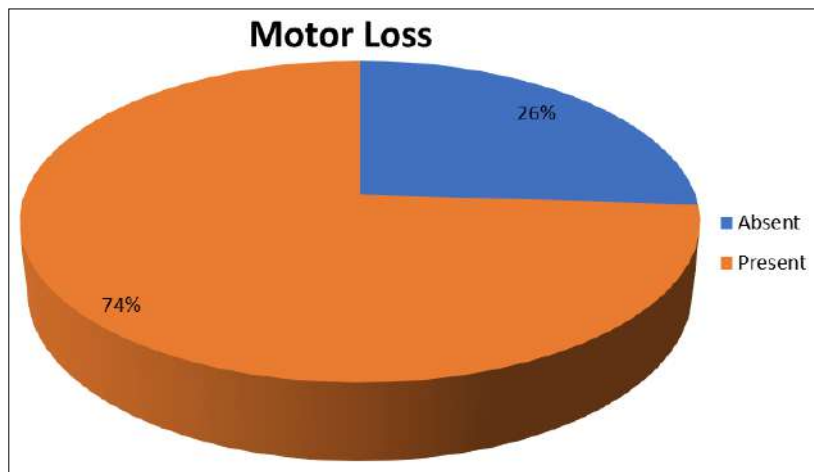
fracture. Motor loss was found in 27%, 27%, 22%, 24% and 0% of the subjects with AIS grade A, B, C, D and E respectively. (Table 3 & Graph 5a & b)

Table 3: Sensory and Motor loss among the study subjects

Sensory Loss	No. of cases	%
Absent	12	24
Present	12	24
Not Applicable	26	52
Motor Loss	No. of cases	%
Absent	13	26
Present	37	74



Graph 5a: Sensory loss among the study subjects



Graph 5b: Motor loss among the study subjects

Discussion

Diagnostic imaging, particularly Magnetic Resonance Imaging (MRI), plays a crucial role in evaluating and detecting spinal trauma. Subtle bone marrow, soft-tissue, and spinal cord abnormalities, which may not be apparent on other imaging modalities, can be readily detected on MRI. Early detection often leads to prompt and accurate diagnosis, expeditious management, and avoidance of unnecessary procedures. The depiction of parenchymal SCI on MRI not only correlates well with the degree of neurologic deficit, but it also bears significant implications in regard to prognosis and potential for neurologic recovery. Considering the advantages of MRI as an excellent diagnostic modality for evaluation of spinal trauma, it was possible to suggest that the MRI findings correlated directly with the degree of weakness according to ASIA (American Spinal Injury Association) impairment scale⁷. The present prospective observational study was conducted among 50 patients with clinical suspicion of spinal trauma referred to Department of Radio diagnosis, Imaging and Interventional radiology from OPD/IPD of C.S.S. Hospital, Subharti Medical College, Meerut for a period of 2 years, from October 2019 to August 2021. Out of 50 subjects:

Gender & Age

78% and 22% of the subjects were male and female respectively. Hence there was male dominance in our study. In our study, maximum subjects were from the age group of 31-40 years (32%) followed by 41-50 years (20%). Minimum subjects were from the age group of 51-60 years

(6%) followed by 11-20 years (10%). The relative predominance of young male patients is most likely due to increased mobility, work related injuries and road traffic accidents. Bollipo JP *et al.* ^[8] in their study mentioned that most of the patients were males with the maximum of the patients being between the ages 21-50 years. Gender related findings correlate well with the similar studies done by, Hassan Gamal G ^[9], Gupta R *et al.* ^[10], Debebe F *et al.* ^[11] and Lalwani S *et al.* ^[12]. Age group of affected patients were comparable with the findings of Gupta R *et al.* ^[10] and Hassan Gamal G ^[9], where with mean age groups were 43 years and 41.2 years respectively. In a study by Gurinder Bir Singh *et al.* ^[13], the peak age range for spinal trauma was 19 to 40 years with male to female ratio of 4.5:1.

Mode of Injury

History of fall and road traffic accident (RTA) was reported among 68% and 32% of the subjects respectively in our study. These findings were consistent with the findings of Hassan Gamal G, where the main causative agents of spinal injury were motor vehicle accidents (41.8%), falls from height (28.6%), motorcycle accidents (19.4%), sports (6.1%), and others (4.1%) ^[13]. Similar results were also obtained in the studies conducted by Debebe F. *et al.* ^[11], Rahimi-Movaghar V. *et al.* ^[14] and Tee J. *et al.* ^[15]. Gurinder Bir Singh *et al.* ^[13] in their study revealed that the most common cause of spine related injury in 29(58%) cases, followed by fall from height in 12(24%) cases and assault in 5(10%) cases. Bollipo JP *et al.* ^[8] in their study showed that the most common cause of injury was fall from

height where 39 (50%) of the patients were affected, followed by 23 patients who had road traffic accident (28.5%).

Part and Type of Vertebra Involved in Fracture

In this study; burst fracture, compression fracture and posterior element was reported among 22%, 72% and 30% of the subjects respectively. Anteropulsion and retropulsion was reported among 6% and 44% respectively. Bajracharya S *et al.* [13] in their study found that out of all the spinal fractures, 90% occurred between T-11 and L-4 vertebra. According to Bollipo JP *et al.* [8], of the osseous fracture injuries, vertebral fracture was observed in 37 (47.4%) of the patients, posterior elements fracture was observed in 5 (6.4%) patients and dislocation was observed in 21 (26.9%) of the patients. According to Gurinder Bir Singh *et al.* [13], vertebral body injury was seen in 20 (40%) cases while posterior element was found in 4% of the subjects.

Spinal Cord Haemorrhage and AIS

Spinal cord haemorrhage was present among 4% in our study subjects, In these cases 50% and 50% of the subjects with cord haemorrhage were having AIS grade A and E respectively. Patients with spinal cord edema and hemorrhage areas had more neurological damage and indicated poor prognosis. In a study by Umesh C. Parashari *et al.* [7], sizable focus of hemorrhage (>1 cm) involving cord was present in 20/62 patients i.e. 32% of patients. In patients with presence of sizable focus (>3cm) of hemorrhage, among the 19 patients graded initially as AIS A, only one patient showed improvement. Preethi Ganesan *et al.* [16] study demonstrated that patients with presence of sizable focus of haemorrhage had larger cord edema and more severe grade of initial ASIA impairment scale (AIS) with poor recovery at follow up. Gurinder Bir Singh *et al.* [13] in their study revealed that cord haemorrhage and oedema was seen only in 2(4%) cases respectively. Ayush Gupta *et al.* [17] in their study revealed that cord hemorrhage was found among 4% of the subjects. The above findings are similar to our study.

Spinal Cord Oedema and AIS

Spinal cord oedema was found among 39 (78%) study subjects. Out of 39 subjects, 13 (26%) were having cord oedema <3 cm and 26 (52%) were having cord oedema >3 cm. 30.9%, 7.6%, 15.4%, 38.5% and 7.6% of the subjects with cord oedema <3cm were having AIS grade A, B, C, D and E respectively. 23%, 34.7%, 23%, 19.3% and 0% of the subjects with cord oedema >3cm were having AIS grade A, B, C, D and E respectively. According to Umesh C. Parashari *et al.* [7], Cord edema involving less than 3 cm cord was present in 14/62 patients i.e. 24.56% and more than 3 cm of cord was present in 28/62 patients i.e. 49.12%. In patients with cord edema involving <3cm of cord, initial paralysis was graded as AIS A in only 2 of 14 patients – 14.3% of patients, AIS D in 11 patients – 78.57%. Out of two patients with initial AIS A, one patient has shown improvement to AIS C. In patients with initial cord edema involving >3 cm of cord, 21 patients i.e. 75% were graded as AIS A and on follow-up only two patients showed improvement to AIS D. Of the 15 patients who had shown no finding in cord, 12 patients showed no clinical deficit, 2 patients were graded as AIS D and one patient was graded as AIS C. Ayush Gupta *et al.* [17] in their study reported that

cord oedema was found in approximately 80% of the subjects.

Abnormal Spinal Cord and AIS

Normal and abnormal spinal cord was revealed among 80% and 20% of the subjects respectively. 25%, 25%, 20%, 25% and 5% of the subjects with abnormal spinal cord were having AIS grade A, B, C, D and E respectively. Umesh C. Parashari *et al.* [7] in their study revealed that cord abnormalities were present in 47 out of 62 patients i.e. 75.80% of patients. In a similar study, Kulkarni *et al.* [23] revealed the presence of cord abnormalities in 70% of patients. Preethi Ganesan *et al.* [16] in their study found normal cord in only 26% of the subjects. Majority of MR findings correlated well with clinical profile of the patient according to ASIA impairment scale. This study demonstrated that patients with presence of sizable focus of haemorrhage had larger cord edema and more severe grade of initial ASIA impairment scale (AIS) with poor recovery at follow up.

AIS

In our study AIS grade A, B, C, D and E was found among 20%, 20%, 16%, 22% and 22% of the study subjects respectively. In a study by Umesh C. Parashari *et al.* [7], initial paralysis was graded as AIS A in 26 patients (41.93%), B in 1 (1.61%), C in 6 (9.67%), D in 17 (27.42%) and E in 12 (19.35%) patients. Ayush Gupta *et al.* [16] in their study showed that 8 subjects were graded as AIS E (12.3%), on follow up 15 subjects graded as AIS E. Hence these findings were similar to our study. Severity of injury according to ASIA in Bollipo JP *et al.* [8] study was grade D (39.7%), grade A (35.9%), grade C (15.4%) and grade B (9%). In a study by Bozzo A *et al.* [18], 40% of the patients had grade A severity, 22% had grade B, 33% had grade C, 34% had grade D and 11% had normal cord i.e., Grade E. A study by Andreoli C *et al.* [19], reported 42% ASIA Grade A, 32% Grade B, 42% grade C and 26% grade D. However, a study by Shimada K *et al.* reported a higher-Grade C (40%) compared to the other severity grades [20]. The difference in the grade of numerous studies might be due to severity of injury of the patients involved in their respective studies.

AIS and Sensory/Motor Loss

Sensory loss was noted among 24% of the study subjects. Motor loss was absent and present among 26% and 74% of the subjects respectively. Sensory loss was found in 58.4%, 16.65%, 8.3% and 16.65% & 0% of the subjects with AIS grade A, B, C, D and E respectively. Motor loss was found in 27%, 27%, 22%, 24% and 0% of the subjects with AIS grade A, B, C, D and E respectively. Similarly, Ayush Gupta *et al.* [17] in their study revealed that cord transection and cord hemorrhage were associated with complete SCI and with poor neurological recovery.

Correlation of Level of Dermatome Involved with MRI findings

There are 7 cervical (neck), 12 thoracic (chest), 5 lumbar (back), and 5 sacral (tail) vertebrae. The spinal cord sends roots that exit the spinal canal between vertebral bodies. Spinal cord segmental levels are defined by their roots but are not always situated at the corresponding vertebral levels. For example, the C8 cord segment is situated in the C7 vertebra while the T12 cord is situated in the T8 vertebra.

The lumbar cord is situated between T9 and T11 vertebrae. The sacral cord is situated between the T12 to L2 vertebrae. The spinal roots for C1 exit the spinal column at the atlanto-occiput junction. The spinal roots for C2 exit the spinal column at the atlanto-axis. The C3 roots exit between C2 and C3. The C8 root exits between C7 and T1. The first thoracic root or T1 exits the spinal cord between T1 and T2 vertebral bodies. The T12 root exits the spinal cord between T1 and L1. The L1 root exits the spinal cord between L1 and L2 bodies. The L5 root exits the cord between L1 and S1 bodies. Sensory loss is seen when dorsal column of spinal is also involved [21]. In our study all the 12 patients with sensory loss were having spinal cord edema/contusion involving spinal cord segment and the level of sensory loss was matched with the spinal cord segment and the level of vertebrae fracture.

Our study revealed that MRI is a vital imaging technique and provides accurate prognostic information regarding neurological function and aids in diagnosis and treatment of cases of spinal trauma. Saifuddin A also established that MRI is a vital imaging technique. Selden NR showed that emergency MRI after spinal cord injury provides accurate prognostic information regarding neurological function and aids in diagnosis and treatment of cases of persistent cord compression after vertebral alignment. Slucky AV *et al.* showed that MRI of acute spinal injury provides excellent visualization of neurological and soft tissue structures in non-invasive format. Slucky AV *et al.* also showed the correlation of MRI findings with experimental and clinical SCI with a relative predictive value to SCI pattern on MR images indicative of long-term neurological outcome [22].

Conclusion

Patients with large cord edema had initial high grade AIS and less chance of recovery with vice versa. Sizable focus of hemorrhage (>3 cm) within the cord was most important prognostic factor. Patients with presence of sizable focus of hemorrhage had larger cord edema and more severe grade of initial AIS than those without hemorrhage with significantly more chances of retaining complete injury at follow up. Patient with small amount of hemorrhage (<3 cm) showed relatively better outcome. Patients with hemorrhage had significantly less upper extremity motor scores at the time of injury and at follow-up. Length of cord oedema was indicative of extent of sensory involvement. Recovery rates of sensory scores can be predicted significantly lower in patients with hemorrhage when compared with those without hemorrhage in the spinal cord.

With this study we concluded that various MRI findings in acute spinal cord injury correlate well with the initial clinical findings according to ASIA impairment scale and can be helpful to clinician in predicting the outcome and extent of recovery in patients of spinal cord injury.

References

- Schaefer DM, Flanders AE, Osterholm JL, Northrup BE. Prognostic Significance of Magnetic Resonance Imaging in the Acute Phase of Cervical Spine Injury. *Journal of Neurosurgery* 1992;76:218-23.
- Shih P, Fessler RG. Trauma of the Nervous System and Spinal Cord Trauma, *Bradley's Neurology in Clinical Practice*, 6th edition, Philadelphia, Elsevier 2012:1212-1250.
- Ling GSF. Traumatic Brain Injury and Spinal Cord

- Injury, Cecil Medicine, 24th edition, Philadelphia, Elsevier 2011, 406- 422.
- Moore KL. Clinically Oriented Anatomy Williams and Williams, Baltimore 3rd edition 1992.
- Damadian R. Tumour Detection by Nuclear Magnetic Resonance. *Science* 1976;171:1151-1153.
- Snell RS. Clinical neuroanatomy. Lippincott Williams & Wilkins 2010.
- Parashari UC, Khanduri S, Bhadury S, Kohli N, Parihar A, Singh R, *et al.* Diagnostic and prognostic role of MRI in spinal trauma, its comparison and correlation with clinical profile and neurological outcome, according to ASIA impairment scale. *Journal of Craniovertebral Junction and Spine* 2011;2(1):17.
- Bollipo JP, Rao PB. Evaluation of spinal injuries by MRI. *International Surgery Journal* 2019;6(2):542-6.
- Hassan Gamal G. Evaluation of spinal trauma by multi detector computed tomography and magnetic resonance imaging. *EJRN* 2014;45(4):1209-14.
- Gupta R, Mittal P, Sandhu P, Saggarr K, Gupta K. Correlation of qualitative and quantitative MRI parameters with neurological status: a prospective study on patients with spinal trauma. *Journal of clinical and diagnostic research: JCDR* 2014;8(11):RC13.
- Debebe F, Woldetsadik A, Laytin A, Azazh A, Maskalyk J. The clinical profile and acute care of patients with traumatic spinal cord injury at a tertiary care emergency centre in Addis Ababa, Ethiopia. *Afr J Emerg Med* 2016;6(4):180-4.
- Lalwani S, Singh V, Trikhya V, Sharma V, Kumar S, Bagla R, *et al.* Mortality profile of patients with traumatic spinal injuries at a level I trauma care centre in India. *The Indian journal of medical research.* 2014;140(1):40.
- Gurinder Bir Singh, Shubhangi Saroa, Arvinder Singh, Ramesh Chander, Neki NS. Role of Magnetic Resonance Imaging in diagnostic evaluation of Spinal Trauma. *Int. J. Curr. Res. Med. Sci* 2018;4(12):76-86.
- Rahimi-Movaghar V, Sayyah M, Akbari H, Khorramirouz R, Rasouli M, Moradi-Lakeh M, *et al.* Epidemiology of Traumatic Spinal Cord Injury in Developing Countries: A Systematic Review. *Neuroepidemiology* 2013;41(2):65-85.
- Tee J, Chan C, Fitzgerald M, Liew S, Rosenfeld J. Epidemiological Trends of Spine Trauma: An Australian Level 1 Trauma Centre Study. *Global Spine J* 2013;3(2):075-84.
- Preethi Ganesan AS, Prakash S, Parthasarathy EA, Anand R, Kalaiarasan R. Role of CT and MRI in spinal trauma. *International Journal of Contemporary Medicine Surgery and Radiology* 2018;3(2):11-4.
- Gupta A, Dhande R. Role of magnetic resonance imaging in the evaluation of spinal trauma. *J Datta Meghe Inst Med Sci Univ* 2020;15:192-6.
- Bozzo A, Marcoux J, Radhakrishna M, Pelletier J, Goulet B. The role of magnetic resonance imaging in the management of acute spinal cord injury. *Journal of neurotrauma* 2011;28(8):1401-11.
- Andreoli C, Colaiacomo MC, Rojas Beccaglia M, Di Biasi C, Casciani E, Gualdi G. MRI in the Acute Phase of MRI In Spinal Cord Injury - Relationship Between MRI Findings and Neurological Outcome. *Radiology* 2005;110:636-645.
- Shimada K, Tokioka T. Sequential MR studies of

- cervical cord injury: correlation with neurological damage and clinical outcome. *Spinal Cord*. 1999;37(6):410.
21. BD. Chaurasia's-Handbook of General Anatomy. 4th edition. New Delhi: CBS; Chapter 7, 2009, 137-150.
 22. Saifuddin A. MRI of acute spinal trauma. *Skeletal Radiol* 2001;30:237-46.
 23. Kulkarni MV, McArdle CB, Kopanicky D, Miner M, Cotler HB, Lee KF, *et al.* Acute spinal cord injury: MRI imaging at 1.5T. *Radiology* 1987;164:837-43.