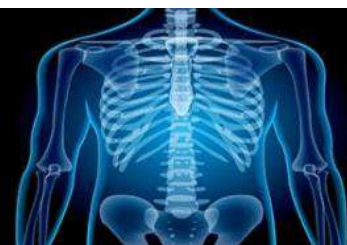

International Journal of Radiology and Diagnostic Imaging



E-ISSN: 2664-4444
P-ISSN: 2664-4436
www.radiologypaper.com
IJRDI 2022; 5(1): 54-57
Received: 26-11-2021
Accepted: 15-01-2022

Adjadohoun S
Medical Imaging service,
National University Hospital
Center Huber Koutoukou Maga,
CNHU-HKM, de Cotonou, Benin

Videgla Ble
Medical Imaging service,
National University Hospital
Center Huber Koutoukou Maga,
CNHU-HKM, de Cotonou, Benin

Akanni Dwmm
Medical Imaging service,
National University
Département Center of Borgou
and Alibori, Benin

Olounde M
Medical Imaging service,
National University Hospital
Center Huber Koutoukou Maga,
CNHU-HKM, de Cotonou, Benin

Yekpe Ahouansou P
Medical Imaging service,
National University Hospital
Center Huber Koutoukou Maga,
CNHU-HKM, de Cotonou, Benin

Savi De Tove Kms
Medical Imaging service,
National University
Departmental Center of Borgou
and Alibori, Benin

Biaou O
Medical Imaging service,
National University Hospital
Center Huber Koutoukou Maga,
CNHU-HKM, de Cotonou, Benin

Adjibabi W
Oto-rhino-laryngology cervico-
facial surgery Service, National
University Hospital Center
Huber Koutoukou Maga,
CNHU-HKM de Cotonou, Benin

Boco V
Medical Imaging service,
National University Hospital
Center Huber Koutoukou Maga,
CNHU-HKM, de Cotonou, Benin

Corresponding Author:
Adjadohoun S
Medical Imaging service,
National University Hospital
Center Huber Koutoukou Maga,
CNHU-HKM, de Cotonou, Benin

Panorama of etiologies of headaches seen on the scanner at the CNHU-HKM of Cotonou from 2016 to 2019

Adjadohoun S, Videgla Ble, Akanni Dwmm, Olounde M, Yekpe Ahouansou P, Savi De Tove Kms, Biaou O, Adjibabi W and Boco V

DOI: <http://dx.doi.org/10.33545/26644436.2022.v5.i1a.256>

Abstract

Introduction: Headaches are one of the main indications for CT in our daily practice. The purpose of this study is to assess the contribution of CT scans in the etiological research of headaches.

Materials and Methods: This was a cross-sectional, descriptive study with retrospective collection carried out over a period of 46 months, in the University Clinic of Medical Imaging of CNHU-HKM in Cotonou (BENIN). We collected all CT scan reports for headaches during the study period. The variables studied were the socio-demographic data, the type of headaches, the computed tomography data.

Results: 5678 cranio-encephalic and sinus scans were recorded, including 353 (6,2%) for an indication of headache. The average age is 43 years with a standard deviation of 4 years at 91 years. A female predominance was noted with a sex ratio (M/F) of 0.72. Chronic headaches were predominant (87% of cases). The CT scan was normal in 38.5% of cases, and objectified lesions consisting mostly of sinus abnormalities (47.6%) followed by intracranial hemorrhages (3.7%), brain tumors (2.3%) and subarachnoid hemorrhages (1.1%).

Conclusion: The cerebral scanner is essential for the etiological assessment of headaches in the absence of MRI.

Keywords: Headaches, scanner, etiology, Benin

Introduction

Headaches are a frequent reason for medical consultation ^[1]. They often pose a diagnostic problem because of the extremely wide range of causes, from potentially serious situations to trivial and benign causes ^[2]. The interrogation is the basis of the diagnostic approach. It aims to specify the mode of installation, the characteristics of the pain, the circumstances of appearance and the associated signs ^[3]. Complementary examinations, including imaging, have an important role to confirm the diagnosis. This study was carried out to review the etiologies found on CT scans in the context of headache exploration at the National University Hospital Center Hubert Koutoukou Maga (CNHU HKM).

Materials and methods

This was a descriptive cross-sectional study with retrospective collection over a period of 46 months from January 2016 to October 2019 in the scanning unit of CNHU HKM. The selection was exhaustive and consisted of the census of all cranio-encephalic and sinus scans realized for headache. The examinations were performed with a multidetector CT (SIEMENS Somatom Emotion Excel Edition, 16 bars, Germany), and consisted of helices on the skull and/or sinuses, without injection and/or with intravenous injection of iodinated contrast medium.

All incomplete files were excluded, i.e. those whose results were not recorded in the registry. We used the register of scan examinations and the reports archived on hard disk for the census.

The general characteristics, the indications of the scan, and the diagnoses found in the scan were the study variables. For the indications, they were grouped according to the doctors' prescriptions into 3 types of headache, namely recent unusual headache, recent usual headache and chronic headache. The data were collected using a collection form on which all the information obtained was recorded and entered into epi info. Data processing and

analysis were done with Excel software. Quantitative variables were expressed as mean plus or minus standard deviation, and qualitative variables as percentage. The confidentiality of the results of the patients' scans was guaranteed and the authorization to access the results of the scans was given by the head of the department concerned.

Results

Prevalence of cranioencephalic and sinus scans performed for headache

Of the 5678 cranioencephalic and sinus scans performed during the study period, 353 were requested for headache, or 6.2%.

Socio-demographic characteristics

A predominance of women was found with 205 (58.1%) women for 148 (41.9%) men, i.e. a sex ratio of 0.72.

The average age was 43 years with extremes of 4 and 91 years. There was a peak in the number of requests for scans for headaches between the ages of 30 and 45 years, which gradually decreased with age (Figure 1).

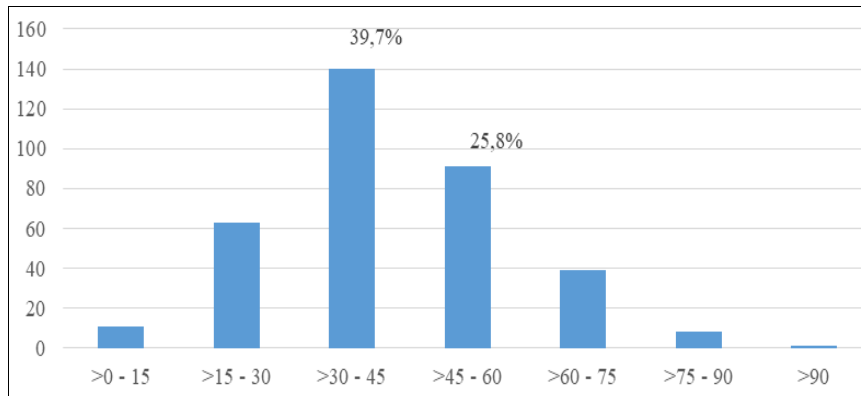


Fig 1: Distribution of CT requests by patient age

Indications

Chronic headaches were the main reason for requesting a CT scan and were found in 87% of cases (Figure 2).

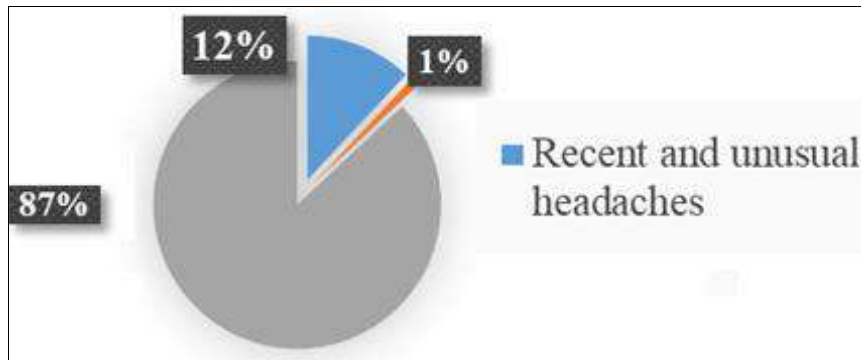


Fig 2: Distribution of patients according to indications for cranio-encephalic or sinus scans.

Scans results

Of the 353 scans performed for headache, 217 were pathological or 61.5% and 136 normal or 38.5% (Table I).

Table I: Distribution of patients according to cranio-encephalic and sinus scan findings.

Results	Effectives N	Percentage (%)
Normal scans	136	38,5
Chronic sinusitis	151	42,8
Acute sinusitis	17	04,8
Hemorrhagic stroke	17	04,8
intra parenchymal hematoma	13	03,7
meningeal hemorrhage	4	01,1
Brain tumor	8	02,3
Bone tumor of the head	3	00,6
Cerebral ischemia	3	00,6
Other**	18	04,5
Total	353	100,0

** Cerebral thrombophlebitis, hydrocephalus and encephalitis

The pathologies diagnosed are diverse but sinusitis is the most frequent (47.6%), followed by cerebral intra

parenchymal hematoma (3.7%), and brain tumors (2.3%), as shown in Table I.

Discussion

In this study, over a period of 46 months (3 years 10 months), 353 cranio-encephalic and sinus scans were requested for headaches. Sonhaye *et al.* [4] in Togo had collected 78 scans over one year (01 year) and Lougué *et al.* [5] in Burkina-Faso 164 scans over 3 years. This shows the overall low trend in our underdeveloped countries in the number of CT scans performed for headache. The limited resources, the relatively high cost of brain scans and the availability of scans could explain this state of affairs.

A predominance of women was found with a sex ratio of 0.72. This result is similar to the literature in the sub-region and elsewhere, notably 0.74 by Lougué *et al.* [5], in Burkina-Faso, 0.66 by Sonhaye *et al.* [4] in Togo and 0.56 by Domingues *et al.* [6] in Brazil.

The mean age was 43 years in this study, slightly lower than that of Sonhaye *et al.* [4] and Domingues *et al.* [6], which were respectively 36 and 33.4 years. This is therefore often a young and active population. A peak in the frequency of indications for headache was observed between the ages of 30 and 45 years, which decreased progressively with age, as in the studies by Sonhaye *et al.* [4] and Domingues *et al.* [6]. This could be explained by the fact that the number of patients with headaches decreases with age.

Chronic headache was the most frequent indication (87%). Contrary to the studies of Sonhaye *et al.* [4] and Stovner *et al.* [7], the majority of patients with headaches were those with recent, brutal or progressive headaches. The inclusion of sinus scans in our cohort as in the study of Domingues *et al.* [6] could explain these large variations.

The high frequency of normal scans, 39% in this study, also found in the study of Sonhaye [4] and Lougé [5] respectively 35% and 54% despite the degree of complaint of the patients, shows the need for a good clinical analysis, particularly the study of the evolutionary profile of the headaches before any imaging exploration and any management.

The pathologies found are diverse, but sinusitis is the most frequent (47.6%), followed by hemorrhagic strokes

(parenchymal hematoma and meningeal hemorrhage) (4.8%) and brain tumors (2.27%). Domingues [6] in Brazil found sinusitis as the first diagnosis, as in our study. Hemorrhagic strokes were predominant in the study by Sonhaye [4] *et al.* and that of Lougué *et al.* [5]. This predominance of hemorrhagic stroke in the sub-region could be explained by several reasons such as examinations performed for the most part in case of sudden headaches as noted by Sonhaye [4], sinus abnormalities relegated to second place by possible parenchymal lesions and the possible omission of reading scans in bone windows.

Sinusitis is a non-specific term referring to inflammation of the paranasal sinuses. There are several forms that are specific entities based on etiology and clinical features [8]. Acute sinusitis (Figure 3) is a clinical diagnosis characterized by a duration of symptoms of less than 4 weeks. Apart from headache, other manifestations include fever, postnasal drip of thick sputum, nasal congestion and abnormal sense of smell. On imaging, thickening of the peripheral mucosa, hydroaerobic level in the paranasal sinuses, gas bubbles in the fluid, and obstruction of the osteo-meatal complexes are signs recognized on CT [9]. It is said to be chronic (Figure 4) when the nasosinus infection lasts for more than 12 weeks. Patients may present with symptoms such as nasal obstruction, nasal discharge, facial pain, headache, bad breath, anosmia. A characteristic feature of sinus scans is sclerotic thickened bone (hyperostosis) involving the sinus wall as a result of a prolonged mucoperiosteal reaction [10].

Intra-parenchymal cerebral hemorrhage is an accumulation of blood in the brain parenchyma [11]. When acute, the blood is markedly hyperdense relative to the brain parenchyma (Figure 5) and as such generally poses little diagnostic difficulty. Its density decreases over time due to its degradation and detersion until it leaves a sequential cavity that is very hypodense on CT [12].

Subarachnoid hemorrhages present as hyperdensity filling the subarachnoid space (figure 5) [13].

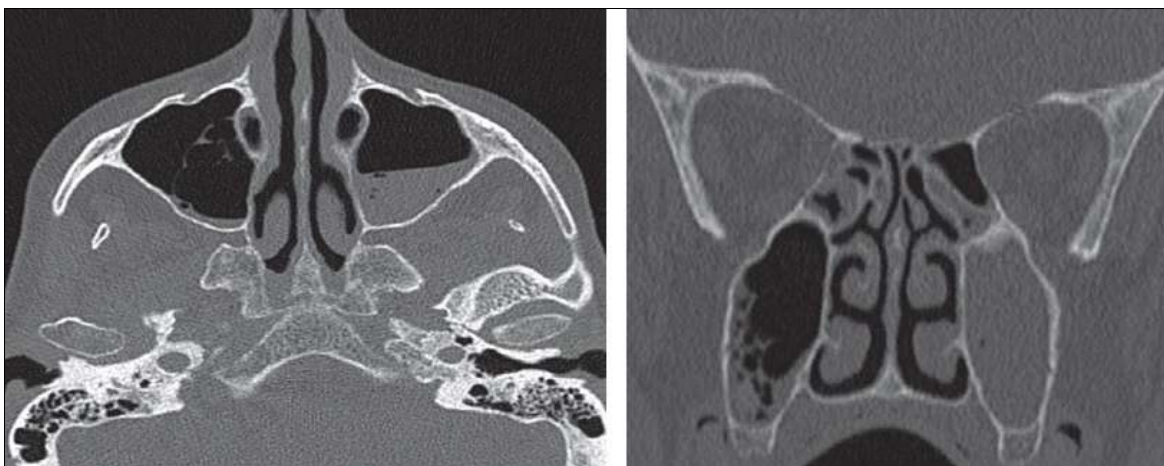

Fig 3: Axial slice (left) and coronal reconstruction (right) of a patient's sinus CT scan showing filling with a hydro-aeric level of the left maxillary sinus and gas bubbles in the maxillary sinus fluids, realizing a foamy appearance on the right consistent with bilateral acute maxillary sinusitis.

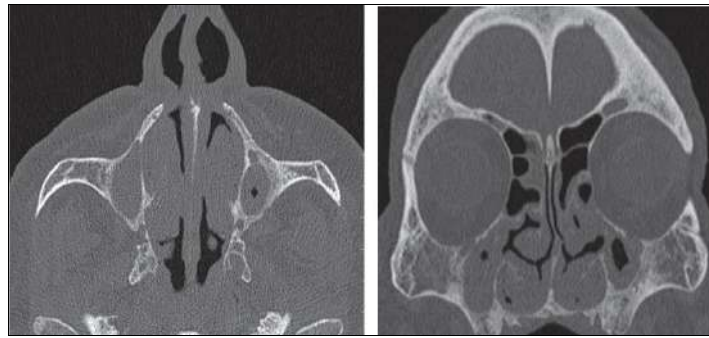


Fig 4: Axial section (left) and coronal reconstruction (right) of a patient's sinus CT scan showing framed mucosal thickenings of the maxillary sinuses with osteosclerosis of the sinus walls consistent with bilateral chronic maxillary sinusitis.

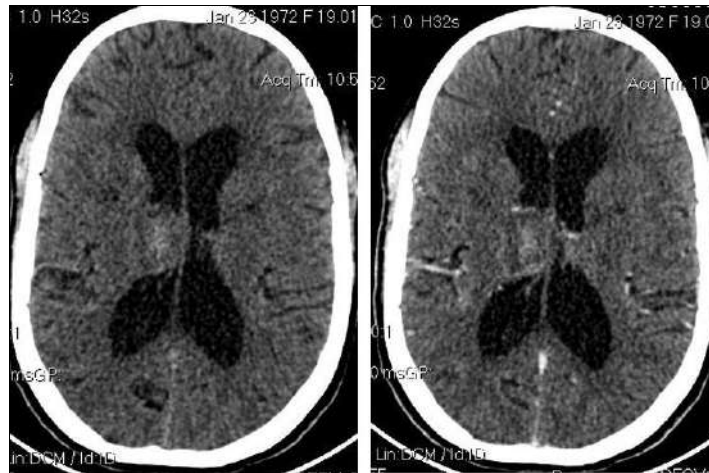


Fig 5: Axial section without (left) and with (right) contrast injection of a patient's cranioencephalic CT scan showing a spontaneously moderately hyperdense formation of the body of the right caudate nucleus massing on the right lateral ventricle and not taking contrast after contrast injection in relation to a resorbing hematoma of the right caudate nucleus body.

Conclusion

At the end of this study, it appears that the cranio-encephalic and sinus scans performed for the etiological assessment of headaches at the CNHU-HKM were pathological in more than half of the cases. Sinusitis was the main etiology found. Cranio-encephalic CT is therefore essential for the etiological assessment of headaches in our context in case of unavailability of MRI. However, the clinic must guide its indications for a good justification of the examination taking into account the irradiation and the health expenses.

References

- Goldstein J, Camargo C, Pelletier A, Edlow J. Headache in United States Emergency Departments: demographics, work-up and frequency of pathological diagnoses. *Cephalalgia*. 2006;26(6):684-690.
- Decroix JP, Céphalées, *et al.* facials. In: Blétry O, Marroun I. Du symptôme au diagnostic. 2^e éd. Paris: Elsevier, 2014, 315-20p.
- Valade D, Céphalée. démarche diagnostique. EMC (Elsevier Masson SAS, Paris), Traité de Médecine Akos, 2011, 1-0300.
- Sonhaye L, Kolou B, Tchaou M, Amadou A, Gbande P, Assih K, *et al.* Aspects tomodensitométriques des céphalées de l'adulte vues au Centre Hospitalier Universitaire Campus de Lomé, Togo. *Rev. méd. Madag*. 2015;5(1):497-500.
- Lougué LC, Cissé R, Dravé A, Bamouni YA, Tapsoba TL, Siko A, *et al.* Apport de la TDM cérébrale dans le bilan des céphalées. *Journal de Radiologie*. 2005;86(10):1344.
- Domingues RB, Kuster GW, Dutra LA, *et al.* Headache epidemiology in Victoria. *Arq Neuro-psiquiatr*. 2004;62(3-A):588-591.
- Stovner L, Hagen K, Jensen R, *et al.* The global burden of headache: a documentation of headache prevalence and disability worldwide. *Cephalalgia*. 2007;27:193-210.
- Searyoh K, Lubbe D. Complications of rhinosinusitis. *South African Family Practice*. 2019;60(5):17-20. doi:10.4102/safp.v60i5.4915
- Cornelius RS, Martin J, Wippold FJ *et al.* ACR appropriateness criteria sinonasal disease. *J Am Coll Radiol*. 2013;10(4):241-6. doi:10.1016/j.jacr.2013.01.001 - Pubmed citation
- Stewart MG, Johnson RF. Chronic sinusitis: symptoms versus CT scan findings. *Curr Opin Otolaryngol Head Neck Surg*. 2004;12(1):27-9. DOI: 10.1097/00020840-200402000-00008
- Sacco RL, Kasner SE, Broderick JP *et al.* An updated definition of stroke for the 21st century: a statement for healthcare professionals from the American Heart Association/American Stroke Association. *Stroke*. 2013;44(7):2064-89. doi:10.1161/STR.0b013e318296aeca
- Brust JC. Current diagnosis and treatment in neurology. 3e éd. New York: McGraw Hill / Medical, 2018, 1717p.
- Oppenheim C, Domigo V, Gauvrit JY *et al.* Subarachnoid hemorrhage as the initial presentation of dural sinus thrombosis. *AJNR Am J Neuroradiol*. 2005;26(3):614-7.