

# International Journal of Radiology and Diagnostic Imaging



E-ISSN: 2664-4444  
P-ISSN: 2664-4436  
[www.radiologypaper.com](http://www.radiologypaper.com)  
IJRDI 2022; 5(2): 21-26  
Received: 11-01-2022  
Accepted: 19-02-2022

**Dr. Karthik HV**  
Post Graduate in MD Radio-  
Diagnosis Bangalore Medical  
College and Research Institute,  
Bangalore, Karnataka, India

**Dr. Sahana C**  
Post Graduate in MD Radio-  
Diagnosis Bangalore Medical  
College and Research Institute,  
Bangalore, Karnataka, India

**Dr. Anand M**  
Post Graduate in MD Radio-  
Diagnosis Bangalore Medical  
College and Research Institute,  
Bangalore, Karnataka, India

**Dr. Ravi N**  
Professor, Department of  
Radiodiagnosis, Bangalore  
Medical College and Research  
Institute, Bangalore,  
Karnataka, India

**Corresponding Author:**  
**Dr. Karthik HV**  
Post Graduate in MD Radio-  
Diagnosis Bangalore Medical  
College and Research Institute,  
Bangalore, Karnataka, India

## Evaluation of spectrum of brain changes in alcohol dependence syndrome patients by magnetic resonance imaging

**Dr. Karthik HV, Dr. Sahana C, Dr. Anand M and Dr. Ravi N**

**DOI:** <http://dx.doi.org/10.33545/26644436.2022.v5.i2a.261>

### Abstract

**Background:** Alcohol is socially and legally accepted substance of abuse ethanol intoxication may lead to loss of subcortical white matter, cerebral atrophy, Wernicke's sencephalopathy, Marchiafava-Bignami disease etc. [1]

Thus the main purpose of the study is to diagnose the alcohol-induced brain changes in Alcohol dependence syndrome patients and thus help in the planning of early treatment of the diagnosed condition, thereby preventing the further neurological decline.

### Aims

1. To describe the various magnetic resonance imaging findings in alcohol dependence syndrome patients.
2. To correlate the cortical changes to the number of years of drinking in alcohol dependence syndrome patients.

**Materials and Methods:** The Study group consisted of 55 patients, who fulfilled the alcohol dependence syndrome criteria according to the International Classification of Disease criteria (ICD-10). Alcohol use disorder identification test scale was applied and individual with alcohol dependence score of >15 (for men) were considered for study.

MRI brain protocol was used and MRI sequences were meticulously evaluated.

Global cortical atrophy scale was used to qualitatively assess the cortical atrophy on FLAIR images. Scoring is given to each lobe separately after assessing the sulci and gyri appearance in each lobe.

**Results:** Most common MRI brain finding was cerebral atrophy (40%) followed by cerebellar atrophy (21.8%), non specific T2 hyperintensities (14.5%) hepatic encephalopathy (5.4%), least common being central pontine myelinosis (1.8%) and marchiafava bignami disease (1.8%).

Most common lobe to show changes of atrophy was frontal lobe, followed by parietal, temporal and least occipital lobe.

**Conclusions:** MRI is the most sensitive imaging modality to identify various neuroimaging findings in alcohol dependence syndrome patients. Cortical atrophy findings were seen more in patients who were chronic drinkers with long duration history of alcohol intake alcohol intake of more than 20 years There was a significant association noted between duration of drinking and atrophic changes and the results were statistically significant ( $p < 0.001$ ). In cortical atrophy the predominantly involved lobe was frontal lobe followed by parietal lobe.

**Keywords:** Magnetic resonance imaging, alcohol dependance syndrome, cortical atrophy, FLAIR sequence

### Introduction

Substance abuse is an enormous problem worldwide. Alcohol is socially and legally accepted substance of abuse. Alcoholism causes a multitude of social and health problems with negative impact on quality of life and secondary costs to society. Alcohol is one of the most commonly abused substances and it is the third leading cause of disease burden in developing countries worldwide. The overall prevalence of alcohol dependence among males aged  $\geq 15$  years was 3.8% and among females aged  $\geq 15$  yrs was 0.4% [2].

Alcohol affects every part of the body, from hair to nail. The first and foremost organ which is influenced and damaged is the brain, especially frontal lobe. Chronic ethanol intoxication may lead to loss of subcortical white matter, cerebral atrophy, Wernicke's encephalopathy, Marchiafava-Bignami disease, osmotic demyelination syndrome and basal ganglia changes seen in patients of hepatic encephalopathy [1].

Moderate/heavy alcohol consumption in older people has been associated with reduced total brain volume, increased ventricle size [3]. Several studies have shown that abstinence can reverse much of the cognitive damage caused by heavy drinking [1].

MRI is the most sensitive imaging modality to identify various neuroimaging findings in chronic alcoholic patients. Alcohol-related encephalopathies can be life-threatening conditions, so the early diagnosis can significantly alter the prognosis of the afflicted patient [4]. Thus the main purpose of the study is to diagnose the alcohol-induced brain changes in Alcohol dependence syndrome patients and thus help in the planning of early treatment of the diagnosed condition, thereby preventing the further neurological decline.

**Materials and Methods**

This is a hospital based, cross sectional case study conducted on all alcohol dependence syndrome patients. Study was conducted in in victoria hospital, attached to Bangalore medical college and research institute. Based on previous study by Somasubhra Chattopadhyay, Mona Srivastava, Arvind Srivastava [6]. Write finding of samaprubha *et al.* study [5]. The sample size estimation to be around 55 calculated using the formula:

$$n = \frac{Z^2 \sigma^2}{d^2}$$

Patients aged between 18 to 50 yrs who have been diagnosed with alcohol dependence syndrome according to the International Classification of Disease criteria (ICD-10) were included in the study.

We excluded patients with history of major medical, neurological illness and psychiatric illness, with a history of seizure disorder, with contraindication for MRI scans such as Pacemakers, metallic implants or metallic foreign body, with a history of other substance abuse (except nicotine).

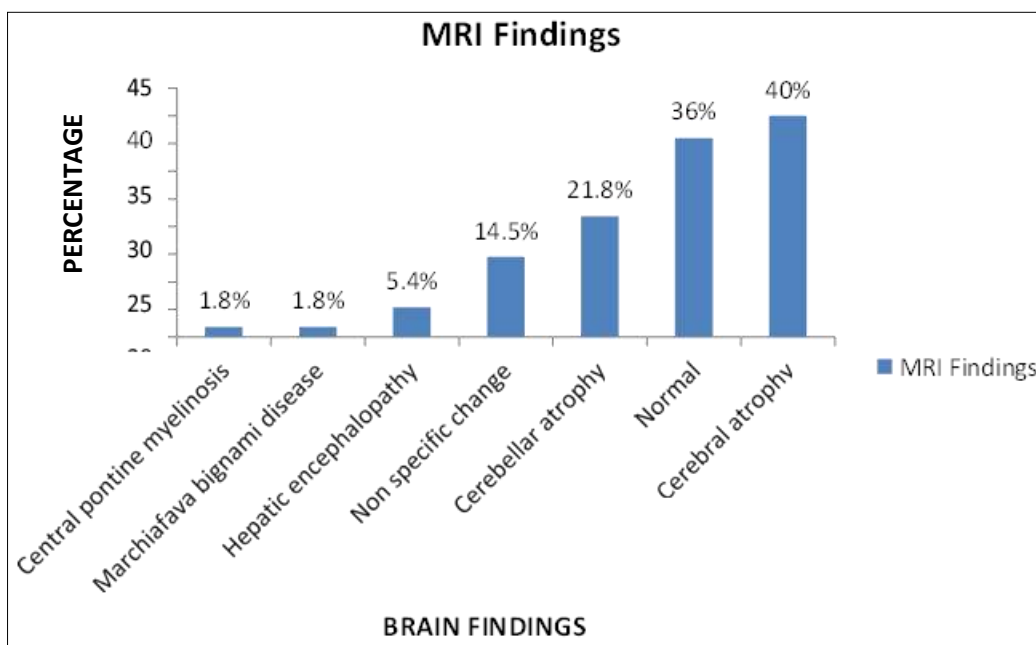
Data was entered into Microsoft excel data sheet and was analyzed using SPSS 22 version software. Categorical data was represented in the form of Frequencies and proportions. Chi-square test was used as test of significance for qualitative data. Continuous data was represented as mean and standard deviation.

The study was done by taking informed consent of the patients and also by taking certificate of clearance by ethics committee.

**Results**

**Table 1:** Various MRI finding distribution among subjects:

MRI Findings	Count	%
Central pontine myelinosis	1	1.8%
Marchiafava Bignami disease	1	1.8%
Hepatic encephalopathy	3	5.4%
Non specific findings	8	14.5%
Cerebellar atrophy	12	21.8%
Normal MRI brain	20	36%
Cortical atrophy	22	40%

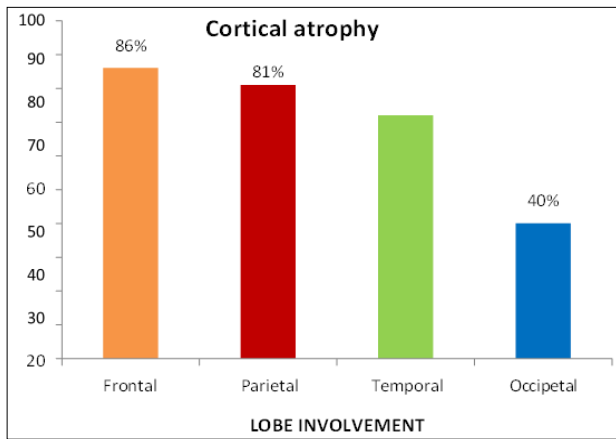


**Chart 1:** Bar diagram showing various MRI brain finding distribution in study subjects.

**Table 2:** Cortical atrophy distribution among four lobes.

Lobes	Cortical atrophy (%)
Frontal	86%
Parietal	81%
Temporal	72%
Occipital	40%

19/22 (86%) patients of cortical atrophy showed atrophy of frontal lobe. 18/22 (81%) patients of cortical atrophy showed parietal lobe atrophy. Similarly temporal lobe involvement were seen in 16/22 (72%) and occipital lobe involvement were seen in 9/22 (40%) cortical atrophy patients.



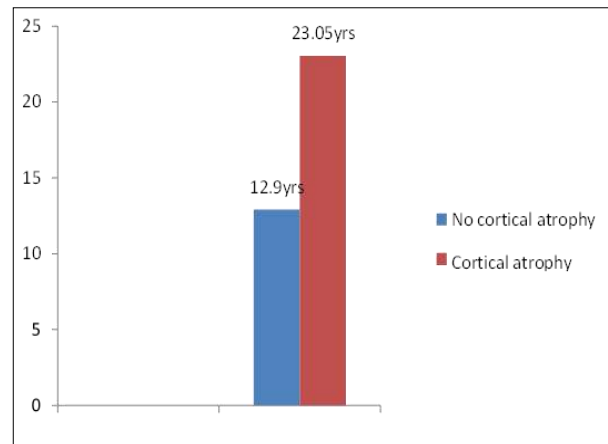
**Chart 2:** Bar diagram showing cortical atrophy among 4 lobes.

**Table 3:** Mean duration of problem drinking in patients with cortical atrophy compared to those without cortical atrophy.

	Numbers	Mean duration of problem drinking
No cortical atrophy	33	12.91
Cortical atrophy	22	23.05

There is a definite difference in the duration of problem drinking between those who were normal and those with cortical atrophy, namely 12.9 years versus 23.05 years for those with cortical atrophy. The statistical significance of

this difference by t test is  $t = 8.7$ , significant at  $< 0.05$  level of probability.

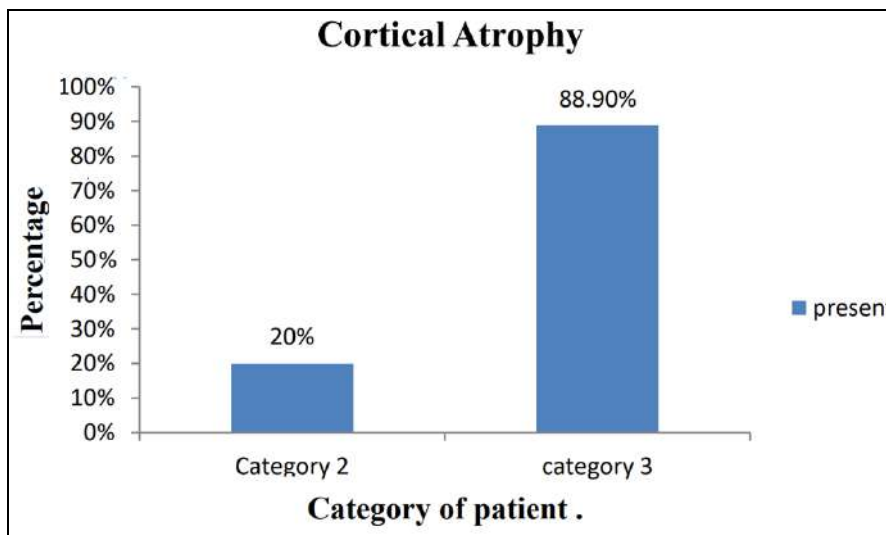


**Chart 3:** Bar chart showing mean duration of drinking in years among subjects showing cortical atrophy and those without atrophy changes.

**Table 4:** Cortical atrophy distribution among category 1, category 2 and category 3 patients.

Cortical atrophy	Category 1	Category 2	Category 3
Present	0%	20%	88.9%
Absent	100%	80%	11.1%

$X^2 = 27.593$ ,  $p$  value = 0.002



**Chart 4:** Bar chart showing cortical atrophy distribution among category 2 and category 3 patients.

**Discussion**

72.7% of the atrophy changes were seen in category 3 patients compared to 27.3% atrophy changes seen in category 2 patients. There was a positive association noted between duration of drinking and atrophic changes and the results were statistically significant ( $P$  value  $< 0.005$ ). This association was similar to the John *et al.* study [6]. Global cortical atrophy scale score of 2 which indicates moderate amount of atrophy were seen only in frontal and parietal lobes. In our study Frontal lobes showed more severe atrophy changes when compared to parietal lobe. There was a positive association noted between duration of drinking and frontal lobe atrophic changes and the results were statistically significant ( $P$  value  $< 0.005$ ). Most of the patients who showed score 2 cerebral atrophy changes belonged to patients who had history drinking for greater

than 20 years. One study conducted by Kubota *et al.* [7] showed increased incidence of frontal lobe shrinkage in chronically heavy drinkers [7]. There is a definite difference in the duration of problem drinking between those who were normal and those with cortical atrophy, namely 12.9 years versus 23.05 years for those with cortical atrophy. The statistical significance of this difference by t test is  $t = 8.7$ , significant at  $< 0.05$  level of probability. This result was similar to study done by John *et al.* [6]

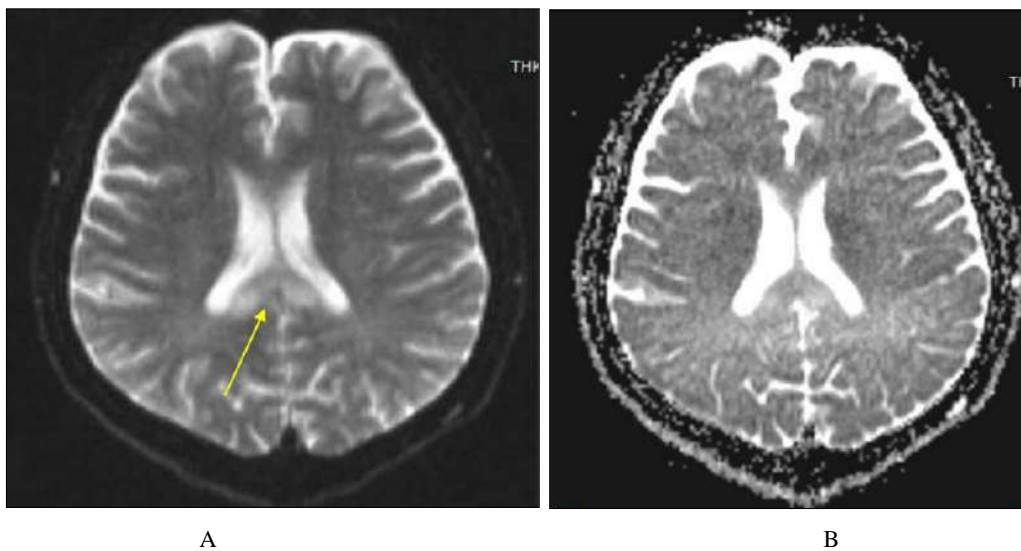
Both temporal and occipital lobes showed atrophy score of 1 indicative of mild atrophy. (40.9%) and (72.7%) patients show cortical atrophy score of 1 in occipital lobe and temporal lobe respectively. Atrophy score of 2 was not seen in both temporal and occipital lobes. Thus there is less severe involvement of both temporal and occipital lobes compared to frontal and parietal lobes. But the results of

association between duration of drinking with parietal, temporal and occipital lobes were not statistically significant with P value >0.005.

Most common finding seen in our study subjects was cerebral atrophy which was seen in 22/55 (40%) patients. Most of the atrophic changes were seen in group 3. 16/18 (88.9%) patients of group 3 showed changes of cerebral atrophy. 6/30 patients of group 2 showed atrophy changes. No atrophy changes were seen in group 1 patients. In a similar study done by John *et al.* [6] which was a cross sectional study of 50 patients, 29/50(58%) patients showed cerebral atrophy. In another cross-sectional study done by Somsubhra Chattopadhyay *et al.* [5], cortical atrophy changes were seen in 60% of alcohol dependence patients. In patients with cerebral atrophy most common lobe to show

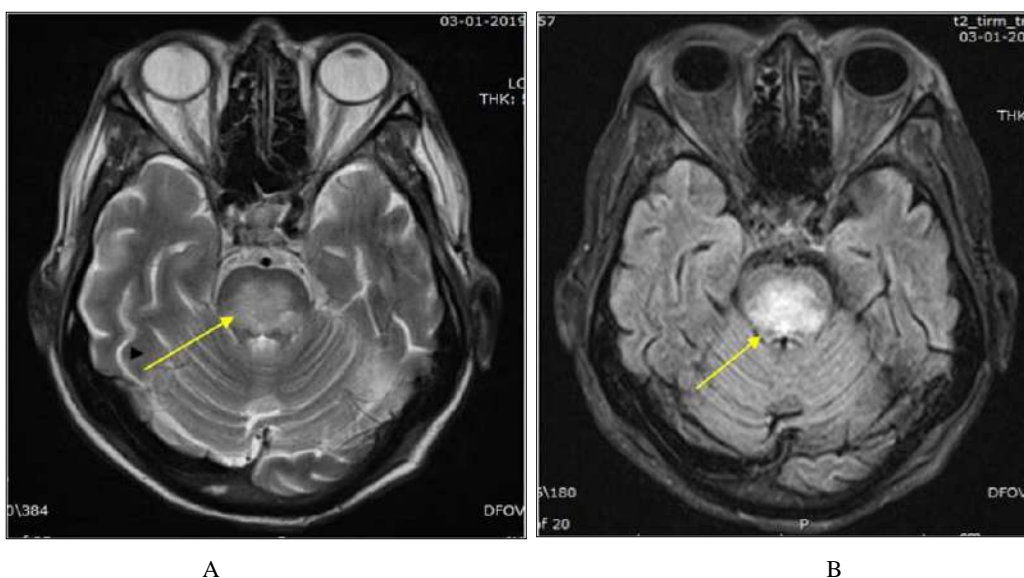
changes of atrophy was frontal lobe. 19/22 (86%) patients of cortical atrophy showed atrophy of frontal lobe. Next common lobe to be involved was parietal lobe. 18/22 (81%) patients of cortical atrophy showed parietal lobe atrophy. Similarly temporal lobe involvement were seen in 16/22 (72%) and occipital lobe involvement were seen in 9/22 (40%) cortical atrophy patients. Our study findings were consistent with similar study done by Sullivan *et al.* [8], which showed that cortical volume loss are more in frontal lobes, followed by parietal, temporal and occipital lobes respectively. Another study done by Somsubhra Chattopadhyay *et al.* [5] also showed frontal and parietal lobes to be the predominantly involved lobes, with temporal and occipital lobes being less involved.

**Case 1: Marchiafava Bignami Disease**

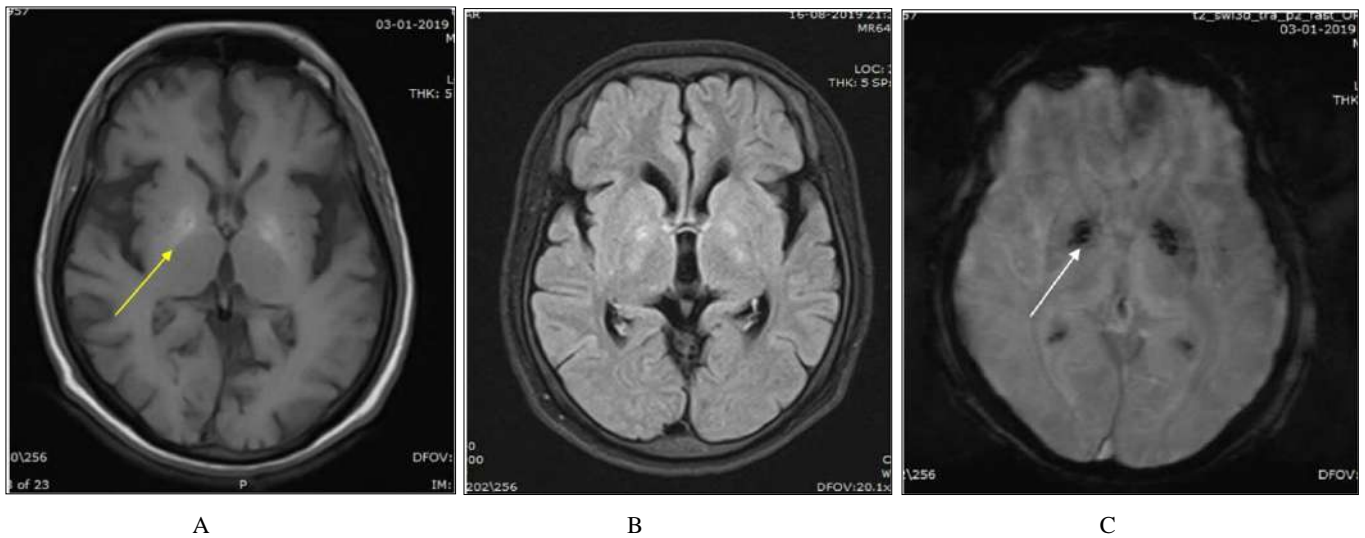


**Fig 1:** Axial sections of brain A. DWI image and B. corresponding ADC image shows areas of diffusion restriction in the region of body and splenium of corpus callosum (yellow arrow).

**Case 2: Central pontine Myelinosis**

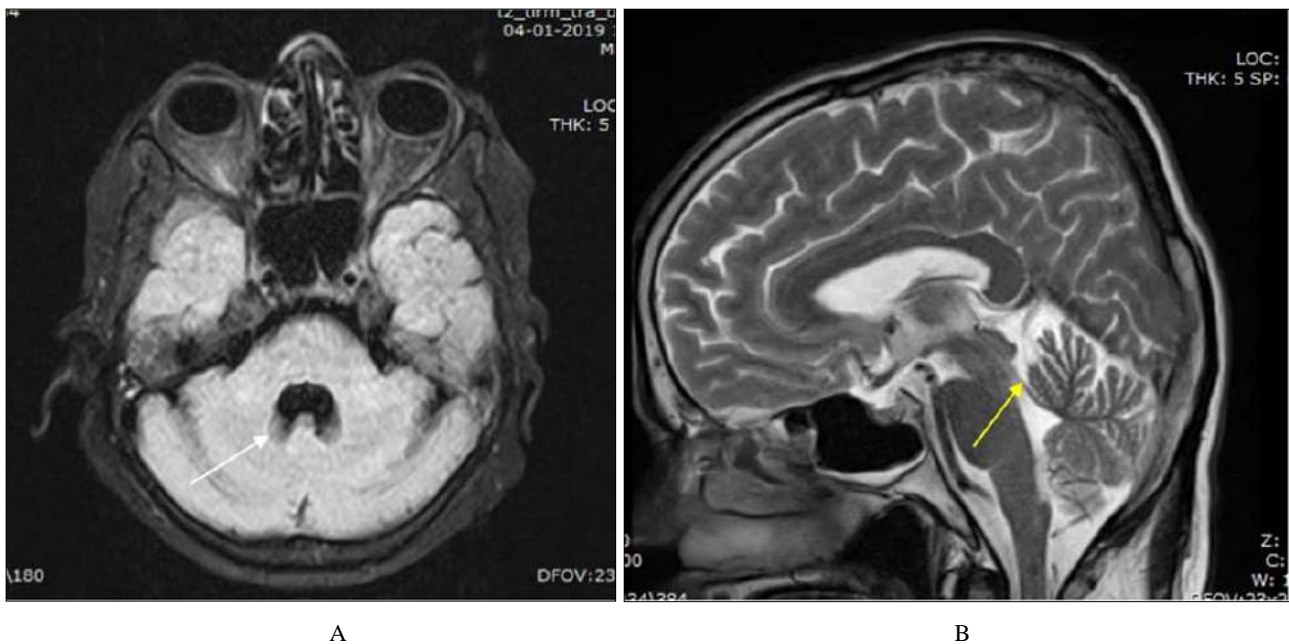


**Fig 2:** Axial sections of the brain A. T2 weighted image, B. FLAIR image, shows T2/FLAIR hyperintensities (yellow arrow) noted in pons and middle cerebellar peduncle sparing peripheral pons with no contrast enhancement on post contrast study (white arrow)



**Fig 3:** Axial sections of the brain A.T1 weighted image, B. FLAIR image, C. SWI images show areas of T2/FLAIR hyperintensities (yellow arrow) noted in the bilateral globus pallidus showing blooming on SWI (white arrow)and show no diffusion restriction (not shown in the image).

**Case 4: Cerebellar Atrophy**



**Fig 4:** Axial sections of the brain A.FLAIR image, B. T2 weighted image and C. Sagittal T2 weighted images show atrophy of cerebellum and vermis (Anterior and superior portion ) (yellow area) with prominence of foliae with dilatation of IV ventricle (white arrow).

**Conclusions**

In our study, a total of 55 alcohol dependence patients were referred to the department of radiodiagnosis. Majority of study subjects belonged to 41-50 age groups (49.2%). The majority of subjects had alcohol dependence for more than 10 years duration (87.2%). All the subjects were male. They were evaluated using our 1.5T MRI machine. MRI was able to detect brain changes in alcohol dependence syndrome patients like cerebral atrophy [9] (40%), cerebellar atrophy [10] (21.8%), hepatic encephalopathy (5.4%), central pontine myelinosis [11] (1.8%) and marchiafava bignami disease [12] (1.8%), non-specific T2 hyperintensities (14.5%). Few of the study subjects showed normal MRI brain study (36%). In patients with cerebral atrophy most, common lobe to show changes of atrophy was frontal lobe. (86%) patients of cortical atrophy showed frontal lobe atrophy [8]. 72.7% of

the atrophy changes were seen in patients who had history of alcohol intake of more than 20 years. There was a significant association between cortical atrophy changes and duration of drinking and the results were statistically significant. Knowledge of normal anatomy and pathological imaging appearance of alcohol encephalopathy is essential in the interpretation of MRI. MRI is the most sensitive imaging modality to identify various neuroimaging findings in chronic alcoholic patients. Alcohol related encephalopathies can be life threatening conditions, so early diagnosis can prevent further neurological outline.

**References**

1. Osborn A, Salzman K, Hedlund G. Toxic encephalopathy. In: Osborn's brain imaging pathology and anatomy. 2<sup>nd</sup> ed. Philadelphia; Saunders Elsevier,

- 2017, 920-927.
2. Simon Davies JC, Smita Pandit A. Is There Cognitive Impairment In Clinically Healthy Abstinent Alcohol Dependence, Alcohol and Alcoholism. 2005;40(6):498-503.
  3. Topiwala A, Allan C, Valkanova V, Zsoldos E, Filippini N, Sexton C, *et al.* Moderate alcohol consumption as a risk factor for adverse brain outcomes and cognitive decline: the longitudinal cohort study. *BMJ*, 2017, 2353.
  4. Zuccoli G, Siddiqui N, Cravo I, Bailey A, Gallucci M, Harper C. Neuroimaging Findings in Alcohol-Related Encephalopathies. *American Journal of Roentgenology*. 2010;195(6):1378-1384.
  5. Somsubhra Chattopadhyay, Mona Srivastava, Aya Shanker Srivastava, Arvind Srivastava. Structural changes in insular cortex in alcohol dependence, *Iran psychiatry*. 2011;6:133-137.
  6. Lusins J, Zimberg S, Smokler H, Gurley K. Alcoholism and cerebral atrophy: A study of 50 patients with CT scan and psychologic testing. *Alcohol Clin Exp Res*. 1980 Oct;4(4):406-11.
  7. Kubota M. Alcohol consumption and frontal lobe shrinkage: a study of 1432 non- alcoholic subjects. *Journal of Neurology, Neurosurgery & Psychiatry*. 2001;71(1):104-106.
  8. Sullivan EV, Zahr NM, Sassoon SA, Thompson WK, Kwon D, Pohl KM, *et al.* The Role of Aging, Drug Dependence, and Hepatitis C Comorbidity in Alcoholism Cortical Compromise. *JAMA Psychiatry*. 2018 May 1;75(5):474-483.
  9. Cala LA, Jones B, Mastaglia FL, Wiley B. Brain atrophy and intellectual impairment of heavy drinkers: a clinical, psychometric computerized tomographic study. *Aust NZJ Med*. 1978;8:147-53.
  10. Lee JH, Heo SH, Chang DI. Early-stage Alcoholic Cerebellar Degeneration: Diagnostic Imaging Clues. *J Korean Med Sci*. 2015;30(11):1539.
  11. Ruzek KA, Campeau NG, Miller GM. Early diagnosis of central pontine myelinolysis with diffusion-weighted imaging. *American journal of neuroradiology*. 2004 Feb1;25(2):210-3.
  12. Kumar S, Challam R, Naveen J, Singh WJ. Marchiafava-bignami disease: A case report. *Journal of clinical and diagnostic research: JCDR*. 2014 Aug;8(8):RD01.