

International Journal of Radiology and Diagnostic Imaging



E-ISSN: 2664-4444
P-ISSN: 2664-4436
IJRDI 2018; 1(1): 25-32
Received: 02-06-2018
Accepted: 27-06-2018

Dr. Pathapati Deepthi
Assistant Professor,
Department of Radio
Diagnosis, Shadan Institute
of Medical Sciences,
Hyderabad, Telangana, India

A study on role of high frequency ultrasonography in the correlative study of thyroid diseases with histopathology report

Dr. Pathapati Deepthi

DOI: <https://doi.org/10.33545/26644436.2018.v1.i1.a.262>

Abstract

Introduction: Thyroid swelling is one of the most common clinical problems seen in the outpatient department. Thyroid clinical evaluation is not always conclusive. As a result, the clinician must rely on other diagnostic modalities such as ultrasonography, FNAC, and others to make a definitive diagnosis.

Aims and Objectives: To evaluate high frequency sonographic pattern of clinically significant thyroid diseases and to study the pathological pattern of thyroid lesions in correlation with histopathologic report.

Methodology: Cross-sectional, hospital-based study was carried out in Department of Radio Diagnosis, Shadan Institute of Medical Sciences, Hyderabad, Telangana, India for patients presenting for USG investigation of thyroid.

Results: Study found a 1:4 male-to-female ratio. Females have more thyroid lesions. Patients with sonogram-detected lesions. 12.5% of 40 instances 62.5% cystic, 42.5% mixed echotexture lesions. Sonographic lesions are seen above. 27 benign solid lesions out of 32 were malignant. We found 4 FNAC-proven lesions. FNAC confirmed just 6 of 10 colloid goitre diagnoses. FNAC confirmed the erroneous positives as multinodular goitre. FNAC confirmed only 5 of 7 cases of multinodular goitre. FNAC confirmed the erroneous positives as Hashimoto's thyroiditis. FNAC confirmed 14 cases of Hashimoto's thyroiditis. FNAC confirmed the erroneous positives as multinodular goitre. All 10 colloid goitres with cystic degeneration were accurately diagnosed. 90% of colloid goitres were correctly identified. FNAC confirmed the misdiagnosis as multinodular goitre. 9 multinodular goitre cases were appropriately diagnosed (100%). FNAC confirmed one misdiagnosed case as Hashimoto's thyroiditis. Ultrasound properly diagnosed 2 cases of haemorrhagic cysts (100 percent). Ultrasonography found two cases of papillary thyroid cancer, and one of them (50%) was successfully diagnosed. In 8 of 10 cases of Hashimoto's thyroiditis (diffuse thyroid disease), the proper diagnosis was multinodular goitres.

Conclusion: There is a high degree of agreement between ultrasound diagnosis and histopathologic diagnosis. So Ultrasound is a very effective and valuable tool in in diagnosing thyroid lesions.

Keywords: Thyroid, ultrasound, FNAC, benign, malignant

Introduction

The thyroid gland is an important component in the body's ability to control metabolic processes, including heart rate and output, lipid catabolism, skeletal growth, and production of heat. One of the most prevalent clinical issues that are seen on a regular basis in the outpatient department is enlargement of the thyroid. The majority of them are caused by diffuse swelling of the thyroid gland, also known as diffuse colloid goitre, which is typically observed during puberty, lactation, and other stages of life [1]. The term "Himalayan goitre belt" refers to an area that is badly impacted on the Indian subcontinent. Other types of malignant growths, such as thyroid neoplasms, can also manifest as an enlarged thyroid mass or a thyroid nodule. Enlargement of the thyroid can be a symptom of a number of immunological conditions affecting the thyroid, including hypothyroidism and hyperthyroidism. Clinical assessment of the thyroid is not always able to provide definitive results [2]. Because of this, the clinician needs to rely on a variety of additional diagnostic modalities in order to arrive at a conclusive diagnosis. Some examples of these modalities include ultrasonography and FNAC. Despite all of the benefits listed above, ultrasonography is only able to correctly differentiate between benign and malignant tumours in a small percentage of cases. As a result, it needs to be correlated with FNAC in order to arrive at a diagnosis that is 100% accurate. FNAC has a high overall sensitivity for the diagnosis of malignancy, with a range that can go anywhere from 90 to 100 percent depending on the

Correspondence

Dr. Pathapati Deepthi
Assistant Professor,
Department of Radio
Diagnosis, Shadan Institute
of Medical Sciences,
Hyderabad, Telangana, India

type of tumour being examined (cystic or solid) ^[1,3].

Aims & Objectives

- To evaluate high frequency sonographic pattern of clinically significant thyroid diseases.
- To study the pathological pattern of clinically significant thyroid lesions in correlation with histopathologic report.
- To study the role of ultrasound in differentiating benign from malignant lesions.

Materials and Methods Source of Data

Patients presenting to the Department of Radiodiagnosis for USG investigation of thyroid in Shadan Institute of Medical Sciences, Hyderabad, Telangana, India.

Study Design

Cross-sectional, hospital-based study.

Method of Collection of Data

This study was carried out in Department of Radiodiagnosis, SIMS, Hyderabad.

Longitudinal and transverse scans of the thyroid gland were done with the patient in supine position and head in hyper-extension using a Philips Color Doppler HD-6system and PHILIPS HD-11 XE ultrasound machine with a multi-frequency linear 3 to 12 MHz probe. The entire gland including the isthmus was examined. The examination has also been extended laterally to include the region of the carotid artery and the jugular vein in order to identify enlarged jugular chain lymph nodes, superiorly to visualize submandibular adenopathy and inferiorly to define any supraclavicular lymphadenopathy. FNAC was done and the smears were read by the pathologist after conducting appropriate staining techniques whenever necessary. Sonographic examination particulars were noted under the following headings:

1. Location: Right or Left lobe.
Diffuse.
2. Number: Single / Multiple.
3. Appearance: Size.
Shape
Margins: Regular/ Irregular.
4. Internal contents: Solid /Cystic /Mixed.
5. Cystic lesions with septations or echogenic foci.
6. Echotexture: Hyper/Hypo/Iso/Anechoic.
7. Parenchymal interface: Invisible.
Echogenic rim
Hypoechoic halo
8. Calcification: Absent.
Present:
a) Egg shell
b) Coarse
c) Micro calcification.
9. Posterior sound transmission: Enhancement
Shadow: No change.
10. Muscle and vascular invasion: Present /Absent.
11. Cervical lymphadenopathy: Present /Absent.
12. Distant metastasis: Present /Absent.

Results of the examination were interpreted on the basis of these findings and diagnosis was proposed after considering history and physical examination. The results were given as whether the lesion is benign or

malignant and has solid, cystic or mixed characteristics. If cystic: Simple.

Hemorrhagic.

Colloid goiter with cystic degeneration.

If mixed: Benign Malignant

If solid: Benign Malignant

Results of Ultrasonographic examination & cytopathology were analyzed and correlated.

Study period: 12 months, with minimum sample of 40 patients.

Plan for data analysis

Data collected shall be analyzed statistically using descriptive statistics namely mean and standard deviation. Comparative statistics may also be used. The depiction of results shall be in the form of percentages and diagrams.

Inclusion Criteria

- Patients with undiagnosed palpable thyroid masses.
- Patients with complaint of thyroid diseases.

Exclusion Criteria

- Patient who are unwilling to undergo ultrasound examination or further histopathologic evaluation of thyroid masses after ultrasound examination.
- Patient with history of bleeding disorders.

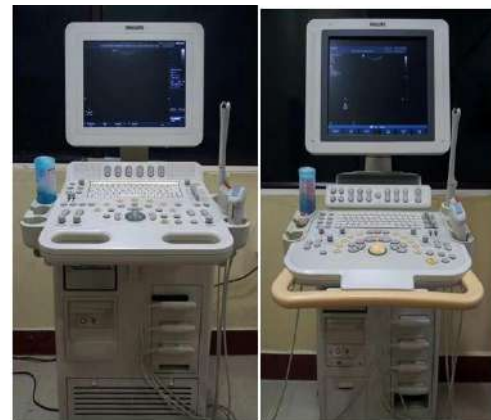

Fig 1: Instruments used
Philips HD-6 Ultrasound machine
Philips HD-11 XE Machine

Results

The present study includes 40 patients referred to our department for ultrasonographic examination of various thyroid swellings.

Table 1: Age Wise Distribution of Cases

Age in years	No. of cases
0-10	0
11-20	2
21-30	11
31-40	15
41-50	8
51-60	3
61-70	1
71-80	0
Total	40

This table shows the distribution of patients among various age groups. Major affected age group is between 21-40 years.

Table 2: Sex Wise Distribution of Cases

Sex	No. of cases
Male	8
Female	32
Total	40

The above table shows the male and female ratio of the patients referred to us for sonographic examination. In our study, the male to female ratio of 1:4 indicates that the incidence of thyroid lesions is significantly higher in female patients.

Table 3: Incidence of Different Types of Lesions on sonography

Type of lesion on sonographic examination	No. of cases
Cystic	5 (12.5%)
Solid	28 (62.5%)
Mixed	17 (42.5)
Total	40

The above table shows the distribution of patients according

Table 5: Sonographic features of different types of cystic lesions

Sonographic Feature	Colloid goiter with cystic degeneration	Haemorrhagic cyst
Shape	2	
Round Oval	3	- 2
Irregular	0	-
Margins	5	2
Regular Irregular	-	-
Echotexture		
Anechoic Hypoechoic	5	2
Hyperechoic	-	-
Homogeneity		
Homogenous	5	- 2
Heterogenous	1	
Calcification	-	-
Hypoechoic Halo	-	-
Lymphadenopathy	2	-
Vascularity	2	-

Above gives an account of the sonographic features of cystic lesions encountered in our study. Three cases of colloid goiter with cystic degeneration showed round shape and another three showed an oval shape with regular margins. They had anechoic pattern with five cases showing homogenous and another one showing heterogenous echotexture. Calcification was absent in all the cases.

In case of hemorrhagic cyst, it had an oval shape and regular margin with predominantly anechoic echogenicity but heterogenous in nature due to blood inside the cyst. There was no calcification, intracystic septation or hypoechoic halo.

Above table shows distribution of solid lesions on sonographic examination. Among the 32 cases of solid lesions 27 were benign and 2 cases were malignant. We came

to the types of lesions detected on sonographic examination. Out of total of 40 cases, 12.5% of them appeared as cystic and 62.5% as solid and 42.5% as mixed echotexture lesions.

Incidence and Types of Cystic Lesions Observed On Sonographic Examination and Their Correlation with FNAC

Table 4: Type of lesion

Type of lesion	Sonographic diagnosis	FNAC diagnosis
Colloid goiter with cystic degeneration	5	5
Haemorrhagic cyst	2	2
Total	7	8

This table shows the distribution of lesions appearing cystic on sonographic examination. We encountered 2 types of lesions appearing cystic and proved by FNAC. On sonography, 5 lesions were diagnosed as colloid goiter with cystic degeneration which were proved to be the same on FNAC. Sonographically diagnosed two cases, of haemorrhagic cyst was also proved to be correct by FNAC.

across 4 varieties of lesions proved by FNAC. 10 cases were diagnosed as colloid goiter out of which only 6 cases were proved to be correct by FNAC. The false positive cases were proved to be multinodular goitre by FNAC.

7 cases were diagnosed as multinodular goitre out of which only 5 cases were proved to be correct by FNAC. The false positive cases were proved to be Hashimoto's thyroiditis by FNAC.

14 cases were diagnosed as Hashimoto's thyroiditis out of which only 14 cases were proved to be correct by FNAC. The false positive cases were proved to be multinodular goitre by FNAC.

There was two cases diagnosed to be of malignant etiology on ultrasound out of which one case was proved to be correct by FNAC (Papillary carcinoma).

Table 6: Sonographic Features of Different Types of Solid Lesions

	Colloid goiter	Multinodular goitre	Hashimoto's Thyroiditis	Papillary Carcinoma
Shape	4	4		-
Round	6	2	Diffuse	- 2
Oval	-	-		
Irregular	-	-		
Margins	7	5	12	- 2
Regular	-	-	-	
Irregular	-	-		
Echotexture	5	5	6	- 2
Isoechoic	- 5	3	5	-
Hypoechoic		-		
Hyperchoic				
Homogeneity	8	6	09	- 2
Homogenous	-	-	5	
Heterogenous				
Calcification	5	-	-	1
Hypoechoic halo	4	-	-	-
Lymphadenopathy	-	3	2	2
Distant metastasis	-	-	-	-
Vascularity	3	2	1	2

Above table shows the sonographic features of different types of solid lesions.

All the cases of colloid goiter were either round or oval with regular margins. They presented with isoechoic and hyperechoic echotexture. All were homogenous with 5 out of 8 cases presenting with a hypoechoic halo. Calcification was observed in 5 cases and lymphadenopathy was not present in any of the cases.

All the multinodular goitres were round or oval with well defined margins and 3 cases showing hypoechoic echotexture and 5 cases being isoechoic. Hypoechoic halo and calcification was absent. Three cases showed lymphadenopathy.

There was a two case of papillary carcinoma which presented with irregular shape and margins with hypoechoic echotexture and heterogenous echo pattern. Calcification was noted in one of the cases and in both cases cervical lymphadenopathy was present.

All cases (14) of Hashimoto's thyroiditis presented with diffuse thyroid swelling with regular margins. The

echotexture was either isoechoic or hypoechoic but none were hyperechoic. Majority of them had homogenous echo pattern. Calcification and hypoechoic halo were absent. Lymphadenopathy was present in two of the cases.

Table 7: Nature of the Solid Thyroid Lesions

Solid lesion	Hyperchoic	Hypochoic	Isochoic
Colloid goiter	4	0	4
Multinodular goitre	0	3	5
Hashimoto's thyroiditis	0	6	7
Papillary carcinoma	0	1	0
Total	4	10	16

This table shows that 5 of the colloid goiters were hyperechoic, and 4 of them were isoechoic. Out of 8 cases of multinodular goiter, 3 cases were hypoechoic and 5 cases were isoechoic in nature. Both cases of papillary carcinoma was hypoechoic. Pertaining to Hashimoto's thyroiditis, 6 cases were hypoechoic and 7 cases were isoechoic.

Table 8: Incidence and Types Of Mixed Lesions Observed On Sonographic Examination And Their Correlation With FNAC

Type of lesion	Sonographic diagnosis	FNAC diagnosis
Colloid goiter with cystic degeneration	9	7
Multinodular goiter	2	2
Total	11	9

Above table shows that 09 cases of mixed echotexture lesions were diagnosed as colloid goiter with cystic degeneration and 7 cases were proved to be correct on

FNAC. 2 cases were diagnosed as multinodular goitre and were proved to be correct on FNAC.

Table 9: Sonographic Features of Various Mixed Lesions

Sonographic feature	Colloid goiter With cystic degeneration	Multinodular goiter
Shape	4	- 2
Round	2	-
Oval		
Irregular	1	
Margins		
Regular	5	2
Irregular	2	-
Echotexture		
Mixed echotexture	8	2
Homogeneity	- 1	- 2
Homogenous	2	
Heterogenous		
Calcification	3	-
Hypoechoic halo	2	-

Lymphadenopathy	2	-
Distant metastasis	-	-
Vascularity	2	-

Table 10: Incidence of Calcification Found With The Lesion

Lesion	No. of cases	No. of cases showing calcification
Colloid goiter	22	6 (27.27%)
Multinodular goitre	09	2 (22.22%)
Hashimoto’s thyroiditis	12	0 (0%)
Papillary carcinoma	2	1 (50%)
Hemorrhagic cyst	2	0(0%)

Above table shows the number of cases with calcification and distribution of calcification among benign and malignant lesions. In our study the rate of calcification was 27.27% for colloid goiter and none (0%) of the Hashimoto’s

thyroiditis and hemorrhagic cyst demonstrated calcification. 22.22% of cases of multinodular goiter showed calcification in our study. One out of two (50%) cases of papillary carcinoma showed calcification.

Table 11: Agreement between the Ultrasonographic Diagnosis With Histopathological Diagnosis

	Ultrasonographic diagnosis	Histopathological diagnosis
Colloid goitre	8 (20%)	7 (17.5%)
Colloid goitre with cystic degeneration	10 (25%)	11 (70%)
Hemorrhagic cyst	2 (5%)	2 (5%)
Hashimoto’s thyroiditis	10 (25%)	8 (20%)
Multinodular goitre	9 (22.5%)	9 (22.5%)
Papillary carcinoma	1 (2.5%)	2 (5%)
Hashimoto’s thyroiditis	-	1 (2.0%)
Total	40	40

Out of 10 cases of colloid goiter with cystic degeneration, all 10 cases (100%) were diagnosed correctly. Out of 10 cases of colloid goiter, 10 cases (90%) were correctly diagnosed. The one misdiagnosed cases were proved to be multinodular goitre by FNAC. Out of 9 cases of multinodular goitre, 09 cases (100%) were correctly diagnosed. The one misdiagnosed cases were proved to be Hashimoto’s thyroiditis by FNAC.

There was 2 case of haemorrhagic cyst which was correctly diagnosed on ultrasound (100%). Out of the 2 cases (50%) of malignant etiology of thyroid (papillary) suggested on ultrasound one cases was correctly diagnosed as papillary carcinoma of thyroid. Out of 10 cases of Hashimoto’s thyroiditis (diffuse thyroid disease), 8 cases were correctly diagnosed and the one misdiagnosed cases proved to be multinodular goiters.

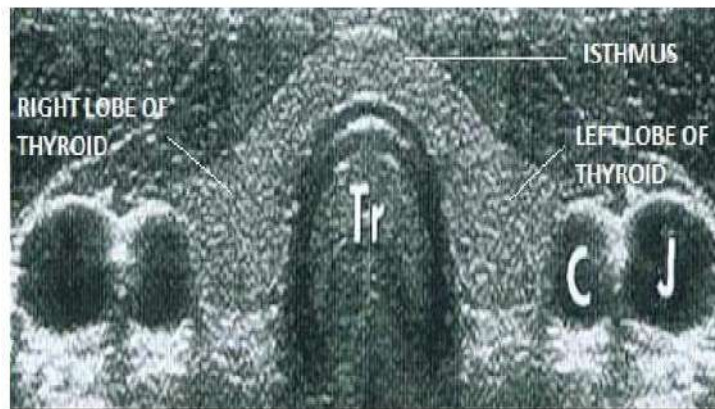

Fig 2: US picture of Normal thyroid
[C –Common carotid artery and J – Jugular vein]

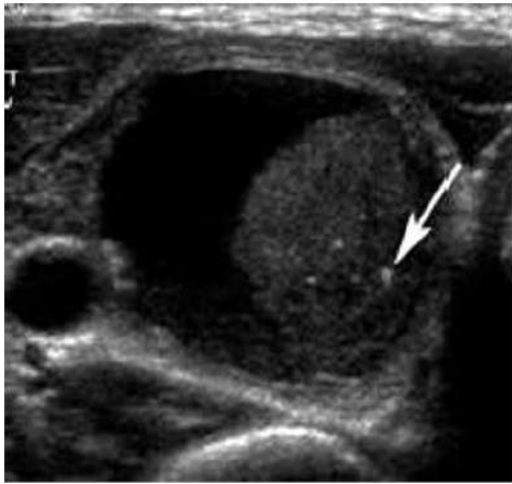


Fig 3: Colloid nodule with cystic degeneration showing comet tail appearances

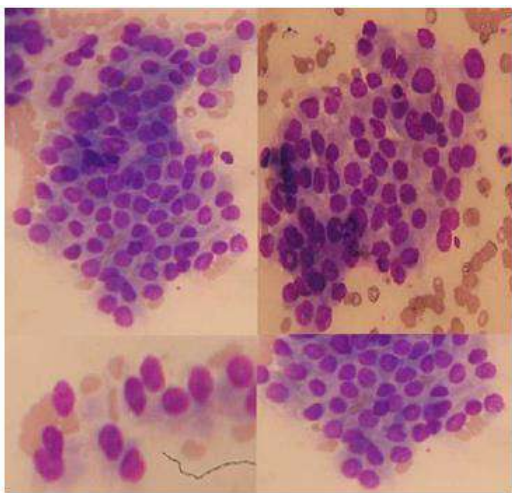


Fig 4: Photomicrograph of papillary carcinoma showing discohesive clusters of cells with anisokaryocytosis; some exhibit intranuclear inclusions

Discussion

The study includes a total of 40 patients presenting with a palpable thyroid mass, referred to our department from the departments of Surgery, Medicine and ENT. Cytopathological correlation has been obtained for every case. The study was conducted from January 2016 to January 2017.

Due to the superficial location of thyroid gland, high-resolution real time gray scale and color Doppler sonography can demonstrate normal thyroid anatomy and pathological conditions with remarkable clarity. This technique being non invasive, economical and without radiation hazards has come to the fore as an appropriate study in the diagnostic evaluation of thyroid diseases.

Ultrasound scan was performed extension using a Philips Color Doppler HD-6 system and PHILIPS HD-11 XE ultrasound machine with a multifrequency linear 3 to 12 MHz probe, which provides excellent image details of thyroid anatomy and various pathological conditions of thyroid gland.

This is a prospective study of only a small group of patients, referred to us with brief clinical history, physical examination and provisional clinical diagnosis. All the patients were examined sonographically and the results were made using various sonological parameters and the findings

were then subsequently correlated with histopathology.

Age

The study comprised of 40 patients between age group 11 to 80 years. The youngest patient in our study was 12-year-old female and the eldest was 62 year old female. Majority of the cases (67%) affected were in the age group of 21 to 40 years.

Watters DA *et al* [6] reported their experience with 120 patients whose age group was between 13 to 84 years. Yokozawa T *et al.* [7] reported their experience with 678 patients in which case the mean age was 52.2 ± 11.9 years.

Sex Distribution

Of the 40 patients in our study group, females constituted 80% and males 20%. Rojeski MT *et al.* [8] in their study on nodular thyroid disease concluded that females are much more frequently affected than males.

Nature of the Lesion

Differentiation of a mass lesion into cystic, solid or mixed is probably the most important application of US evaluation of thyroid. Our yield was 100% in this respect. Out of 40 patients, we categorized 8 cases as cystic, 28 as solid and 17 cases as mixed lesions which were later proved to be correct by FNAC. The solid lesions were more in our study group than the cystic or mixed lesions.

In a study by Rosen IB *et al.* [9], out of 174 cases, an accuracy rate of 96% was observed. Our accuracy of 100% may be because of lesser number of cases.

Cystic Lesions

We encountered 2 types of cystic lesions namely colloid goiter with cystic degeneration and the hemorrhagic cyst. Out of these, majority of the cases were constituted by colloid goiter with cystic degeneration. There were 7 cases presenting with cystic lesions and 5 cases were diagnosed as colloid goiter with cystic degeneration and 2 case as hemorrhagic cyst. All these cases were proved by FNAC. Hence, the accuracy in diagnosing the type of cystic lesions was 100%. Sonographically the cystic degeneration in colloid goiter presented as an anechoic lesion with some internal echoes in the 2 cases.

Solid Lesions

We encountered 28 (62.5%) solid lesions in our study. Among the solid lesions, 16 cases (27%) were sonographically diagnosed as Hashimoto's thyroiditis, 10 cases (16.6%) as colloid goiters, 9 cases (15%) as multinodular goitre and 2 cases (3.33%) as papillary carcinoma. Out of the 10 cases of colloid goiters 9 cases were proved to be correct by FNAC but one case was proved to be multinodular goitre. This was due to the sonographic similarities and lack of any definite sonographic criteria. Sonographic misinterpretation was also one of the causes.

One case of papillary carcinoma was correctly diagnosed out of the two cases. This case also presented with cervical lymphadenopathy. In the case of solid lesions, our accuracy rate was 86.48%.

Rosen IB *et al.* [9] reported 100% accuracy rate for solid lesions. They studied 174 cases out of which 130 (75%)

were solid both by sonography as well as FNAC. Out of these 130 cases 26 (20%) were carcinomas, 68 (52%) were adenomas, 2 (1.5%) were cystadenoma, 16 (12.5%) were colloid nodule, 7 (5.3%) were thyroiditis and 11 (8.5%) were diagnosed as goiter.

Mixed Lesions

We encountered 17 cases of mixed (both solid and cystic) lesions in our study group. 7 cases were diagnosed by USG as colloid goiter with cystic degeneration, 2 cases of multinodular goiter.

All of the multinodular cases (3) were found to be correct by FNAC but one case of colloid goiter with cystic degeneration was found to be multinodular goiter on FNAC. In our study among mixed lesions, the diagnostic yield was 90.0%.

Rosen IB *et al.* [9] in a study of 174 patients, found 14 cases of mixed echotexture nodules by ultrasound evaluation. All of them were found to be correct by FNAC. 4 cases of mixed lesions were falsely diagnosed as cystic and solid lesions by ultrasound which proved to be of mixed echotexture by FNAC.

Calcification

Calcification within the lesion is very important for characterizing a lesion. In our study we found 3 types of lesions in which calcification was present. Out of 22 cases of colloid goiters, 6 cases (27.27%) were showing calcification. 1 case of papillary carcinoma (50%) showed calcifications out of the two cases. In our study, the incidence of calcification in benign thyroid lesions was 22.22% and in malignant lesions it was 50% (1 out of Solbiati L *et al.* [3] in their study on thyroid gland with low uptake lesions described that calcification may be present in both benign and malignant nodules. In their study the incidence of calcification in benign thyroid lesions was 11% and in malignant lesions it was 17%.

Hypoechoic Halo

Presence and nature of hypoechoic halo is one of the important feature that helps in differentiating benign from malignant lesion.

In our study, 10 cases (18.3%) presented with halo, all of which were benign. Out of these, colloid goiter constituted the maximum (80%) followed by multinodular goitre (18%).

Propper RA *et al.* [1] conducted a study on 28 patients with solitary thyroid masses out of which 10 patients had hypoechoic halo. 8 of these lesions were benign being either adenomas or benign nodules. Two lesions were malignant. They suggested the possibility of pericapsular inflammatory infiltrate as its underlying anatomic correlate. Solbiati L *et al.* [3] concluded in their study that a peripheral sonolucent halo surrounding a thyroid nodule may be present in 40-80% of benign nodules and 15% of thyroid cancers. Incomplete, irregular peripheral halo favours a malignant etiology while a complete "halo" with regular margin mostly; although not exclusively are encountered in benign lesions.

Micronodulation

Micronodulation is highly diagnostic of Hashimoto's thyroiditis and was confirmed by Yeh HC *et al.* [14] in which the positive predictive value for diagnosing Hashimoto's

thyroiditis basing on this characteristic finding was 94.7%. Micronodules are 0.1 to 0.65cm in size, hypoechoic and surrounded by an echogenic rim. In our study 10 cases out of 40 (25%) were diagnosed to be Hashimoto's thyroiditis.

Benign Vs Malignant

Most of the cystic lesions are benign in nature (in our study among 8 cystic lesions all cases proved to be benign). In our study 95.8% of solid lesions were benign and rests were malignant. Among mixed lesions 100% were benign. Total benign lesions constitute 96% and malignant lesions constitute 4%.

Our study includes 40 patients presenting with various thyroid masses which were evaluated with ultrasound and the findings were subsequently correlated with FNAC. Hence, an overall account of cases includes 9 cases of colloid goiters out of which 7 cases were proved to be correct by FNAC and one case were proved to be multinodular goitre.

Conclusion

In diagnosing thyroid lesions, ultrasound is a cost-effective, non-invasive, easily accessible, and valuable diagnostic tool with nearly equal sensitivity and specificity to FNAC. In the diagnosis of thyroid lesions, ultrasound and FNAC are complementary. Ultrasound can reveal the number of nodules in a goitre, whether they are solitary or multiple. Ultrasound can detect secondary degenerative changes in thyroid lesions such as cystic changes, calcifications, haemorrhages, and so on. Ultrasound can help distinguish between benign and malignant lesions.

Acknowledgment

The author is thankful to Department of Radiodiagnosis for providing all the facilities to carry out this work.

Conflict of Interest

None

Funding Support

Nil

References

1. Propper RA, Skolnick ML, Weinstein BJ *et al.* The non-specificity of the thyroid halo sign. *J Clin Ultrasound.* 1980;8:129-32.
2. Katz JF, Kane RA, Reyes J *et al.* Thyroid nodules: sonographic-pathologic correlation. *Radiology.* 1984;151:741-45.
3. Solbiati L, Volterrani L, Rizzato G *et al.* The thyroid gland with low uptake lesions: evaluation by ultrasound. *Radiology.* 1985;155:187-91.
4. Hayashi N, Tamaki N, Konishi J *et al.* Sonography of Hashimoto's thyroiditis. *J Clin Ultrasound.* 1986;14:123-6.
5. McConahey WM, Hay ID, Wollner LB *et al.* Papillary thyroid cancer treated at the Mayo clinic, 1946 through 1970: initial manifestations, pathologic findings, therapy and outcome. *Mayo Clin Proc.* 1986;61:978-96.
6. Watters DA, Ahuja AT, Evans RM *et al.* Role of ultrasound in the management of thyroid nodules. *Am J Surg.* 1992;164: 654-7.
7. Yokazawa T, Fukata S, Kanji K *et al.* Thyroid cancer

- detected by ultrasound guided FNAC. *World J Surgery*. 1996;20:848-53.
8. Rojeski MT, Gharib H. Nodular thyroid disease: evaluation and management. *N Engl J Med*. 1985;313:428-436.
 9. Rosen IB, Walfish P, Miskin M *et al*. The ultrasound of thyroid masses. *SCNA*. 1975;59:19-33.
 10. Yeh HC, Futterweit W, Gilbert P. Micronodulation: ultrasonographic sign of Hashimoto thyroiditis. *J Ultrasound Med*. 1996;15:813-9.