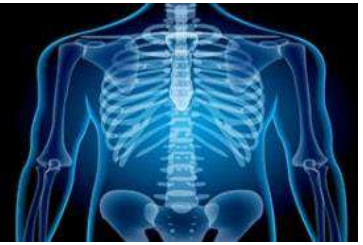

# International Journal of Radiology and Diagnostic Imaging



E-ISSN: 2664-4444  
P-ISSN: 2664-4436  
[www.radiologypaper.com](http://www.radiologypaper.com)  
IJRDI 2022; 5(4): 113-118  
Received: 23-08-2022  
Accepted: 28-09-2022

**Dr. Harshana Subramaniam,**  
PGJR3, Radiodiagnosis  
Mahatma Gandhi Medical  
College & Research Institute,  
Sri Balaji Vidyapeeth  
University, Puducherry,  
Puducherry Union Territory,  
India

**Dr. Prabhu CS**  
Professor, Radiodiagnosis  
Mahatma Gandhi Medical  
College & Research Institute,  
Sri Balaji Vidyapeeth  
University, Puducherry,  
Puducherry Union Territory,  
India

**Dr. Raju**  
Assistant Professor,  
Radiodiagnosis Mahatma  
Gandhi Medical College &  
Research Institute, Sri Balaji  
Vidyapeeth University,  
Puducherry, Puducherry  
Union Territory, India

**Dr. Colonel Sudhir Sachar**  
Professor & HOD,  
Radiodiagnosis Mahatma  
Gandhi Medical College &  
Research Institute, Sri Balaji  
Vidyapeeth University,  
Puducherry, Puducherry  
Union Territory, India

**Corresponding Author:**  
**Dr. Harshana Subramaniam,**  
PGJR3, Radiodiagnosis  
Mahatma Gandhi Medical  
College & Research Institute,  
Sri Balaji Vidyapeeth  
University, Puducherry,  
Puducherry Union Territory,  
India

## A comparative study of conventional magnetic resonance sequences with 2D time of flight sequence versus contrast enhanced magnetic resonance venography in diagnosing cerebral venous sinus thrombosis

**Dr. Harshana Subramaniam, Dr. Prabhu CS, Dr. Raju and Dr. Colonel Sudhir Sachar**

**DOI:** <http://dx.doi.org/10.33545/26644436.2022.v5.i4b.295>

### Abstract

**Background:** The present study aimed to compare the accuracy between conventional MRV with 2D Time of Flight sequence versus contrast enhanced MRV in Cerebral venous sinus thrombosis.

**Materials and methods:** This was a hospital based ambispective study that was conducted from Jan 2021 to Jun 2022 in Department of Radiodiagnosis in Mahatma Gandhi Medical College and Research Institute (MGMCRI), Pondicherry after obtaining approval from Ethical Committee. Patients admitted in MGMCRI as clinically suspected cases of CVT was included for the study. It was an ambispective study, so included records of patients retrospectively from JAN 2019 to DEC 2020 and prospectively from JAN 2021 to MAY 2022 in Mahatma Gandhi Medical College and Research Institute.

**Results:** The study was conducted as a hospital based ambispective study comprising 30 patients of either sex.

Majority of the study participants were in the age group of less than 25 years and were females (73.3%). Majority of the female study participants were in puerperium. Majority of the study patients had headache on presentation (73.3%). Sensitivity and specificity of MR TOF in diagnosing SSS thrombosis was 92.31% and 50% respectively. Sensitivity and specificity of MR TOF in diagnosing LS thrombosis was 79.17% and 33.33% respectively. Sensitivity and specificity of MR TOF in diagnosing STS thrombosis was 100% and 34.78% respectively.

**Conclusion:** Multicentric large scale studies involving patients from different backgrounds of variable demography was required to clearly establish the accuracy of MRI investigations. The performance of contrast enhanced 3D MRV was superior in terms of picture quality and evaluation of all sinuses and veins. The findings of our study contributed to the body of data supporting the advantages of contrast enhanced 3D MR venography over 2D TOF MR Venography in the routine clinical diagnosis or exclusion of acute CVT.

**Keywords:** MRV, time of flight sequence, cerebral venous sinus thrombosis, dural sinuses, cerebral veins

### Introduction

Cerebral venous sinus thrombosis is relatively uncommon condition. In the general population, three to four people per million experience. Dural venous sinus thrombosis (DVST), which can cause a variety of non-specific clinical symptoms, from headache to coma.

The development of ultrasound elastography (USE) aimed to increase the precision with which breasts were recognized and categorized. Shear wave elastography is a non-invasive method for determining tissue stiffness by measuring the rate of shear wave propagation through the patient's body (elasticity). When a focused ultrasound beam enters the breast, shear waves (also known as transverse waves) are created as a result of the beam's acoustic radiation force [1].

Even though clinical palpation is the most straightforward assessment technique, it is of limited utility owing to its low sensitivity and accuracy. Clinical examination alone is sometimes insufficient for detecting tiny and early-stage malignancies in many cases. As a result, we were able to establish a link between the Ultrasonographic characteristics of breast masses and the results of histopathology [2].

It was an ambispective study, so it included records of patients retrospectively from Jan 2019 to Dec 2020 and prospectively from Jan 2021 to May 2022 in Mahatma Gandhi Medical College and Research Institute.

**Inclusion criteria**

1. Acute or sub-acute neurological illness with clinical condition whose features were suggestive of cerebral venous sinus thrombosis irrespective of sex.
2. All pregnant female patients aged > 18 years and aged < 45 years with C/O severe headache in the postpartum period.
3. Patients who were initially subjected to CT for other indication and diagnosed as CVT.

**Exclusion criteria**

1. Patients with Radiological features inconclusive of CVT.
2. Hemorrhagic arterial stroke.
3. Claustrophobia.
4. Renal failure with creatinine > 3.
5. Pt C/I to contrast.
6. Non compatible Metallic implants and Cardiac pacemakers.

**Procedure**

Out of 30 patients, for 15 patients retrospective reports were collected. Another 15 patients were subjected to machine Philips MRI of 1.5 TESLA field strength for confirmation of the diagnosis of CVT. Conventional magnetic resonance sequences which includes sequences TIW SE, T2W TSE, T2 FLAIR, T2FFE Trans, T1 TSE W Sagittal, T2W Flair coronal sections DWI and MRVTOF and contrast enhanced MRV were taken.

**Data collection**

All data was entered into a Data Collection Performa Sheet and was entered into Excel (MS Excel 2019). Other biographical details were also collected including age.

**Statistical Methods**

Statistical analysis was carried out using SPSS version 19.0 (IBM SPSS, US) software with Regression Modules installed.

**Results**

A total of 30 cases were investigated. The majority of the study's participants were under 25 years old. (Table 1). Majority of the patients were females (73.3%) (Table 2) and most of them were in puerperium. (Table 3).

Majority of the study patients had headache on presentation (73.3%). Nearly one fourth of the study patients had seizure at the time of presentation (23.3%). Altered sensorium was present in 13.3% of the patients at the time of presentation. Significantly higher proportion of patients with altered sensorium had poor outcomes. (Table 4).

Majority of the patients had Superior sagittal sinus (86%) thrombosis followed by lateral sinus (80%) Straight sinus is least affected. (23%), (Table 5).

Cytotoxic edema with hemorrhage was the most common parenchymal finding noted in this study. (Table 6). Sensitivity and specificity of MR TOF in diagnosing SSS thrombosis was 92.31% and 50% respectively. (Table 7). Sensitivity and specificity of MR TOF in diagnosing LS

thrombosis was 79.17% and 33.33% respectively. (Table 8). Sensitivity and specificity of MR TOF in diagnosing STS thrombosis was 100% and 34.78% respectively. (Table 9).

**Table 1:** Age distribution

Age	Frequency	Percentage
< 25	18	60.0%
26-35	5	16.7%
36-45	4	13.3%
> 46	3	10.0%
Total	30	100.0%

**Table 2:** Gender distribution

Gender	Frequency	Percentage
Male	8	26.7%
Female	22	73.3%
Total	30	100%

**Table 3:** Puerperal status in female subjects

	Frequency	Percentage
Puerperium	14	63.6%
Non-Puerperium	8	36.4%
Total	22	100%

**Table 4:** Clinical presentation

Clinical Feature	Frequency	Percentage
Headache	22	73%
Seizure	23	76.70%
Altered sensorium	4	13%
FND	6	20%

**Table 5:** Sinuses involved

Sinus Involved	Frequency	Percentage
Superior Sagittal Sinus	26	86%
Lateral Sinus	24	80%
Straight Sinus	7	23%

**Table 6:** Parenchymal changes in MRI.

Parenchymal Findings	Frequency	Percentage
Cytotoxic edema with hemorrhage	15	50%
Vasogenic edema with hemorrhage	7	24%
Cytotoxic edema without hemorrhage	4	13%
Vasogenic edema without hemorrhage	4	13%

**Table 7:** Accuracy of MR TOF venography against Contrast enhanced MR venography in diagnosing SSS thrombosis

MR TOF	Contrast enhanced MR venography		Total
	Positive(Diseased)	Negative (Non-diseased)	
Positive	24	2	26
Negative	2	2	4
Total	26	4	30

Statistic	Value	95% CI
Sensitivity	92.31%	74.87% to 99.05%
Specificity	50.00%	6.76% to 93.24%
Positive Likelihood Ratio	1.85	0.69 to 4.95
Negative Likelihood Ratio	0.15	0.03 to 0.80
Disease prevalence (*)	86.67%	69.28% to 96.24%
Positive Predictive Value (*)	92.31%	81.74% to 96.99%
Negative Predictive Value (*)	50.00%	16.07% to 83.93%
Accuracy (*)	86.67%	69.28% to 96.24%

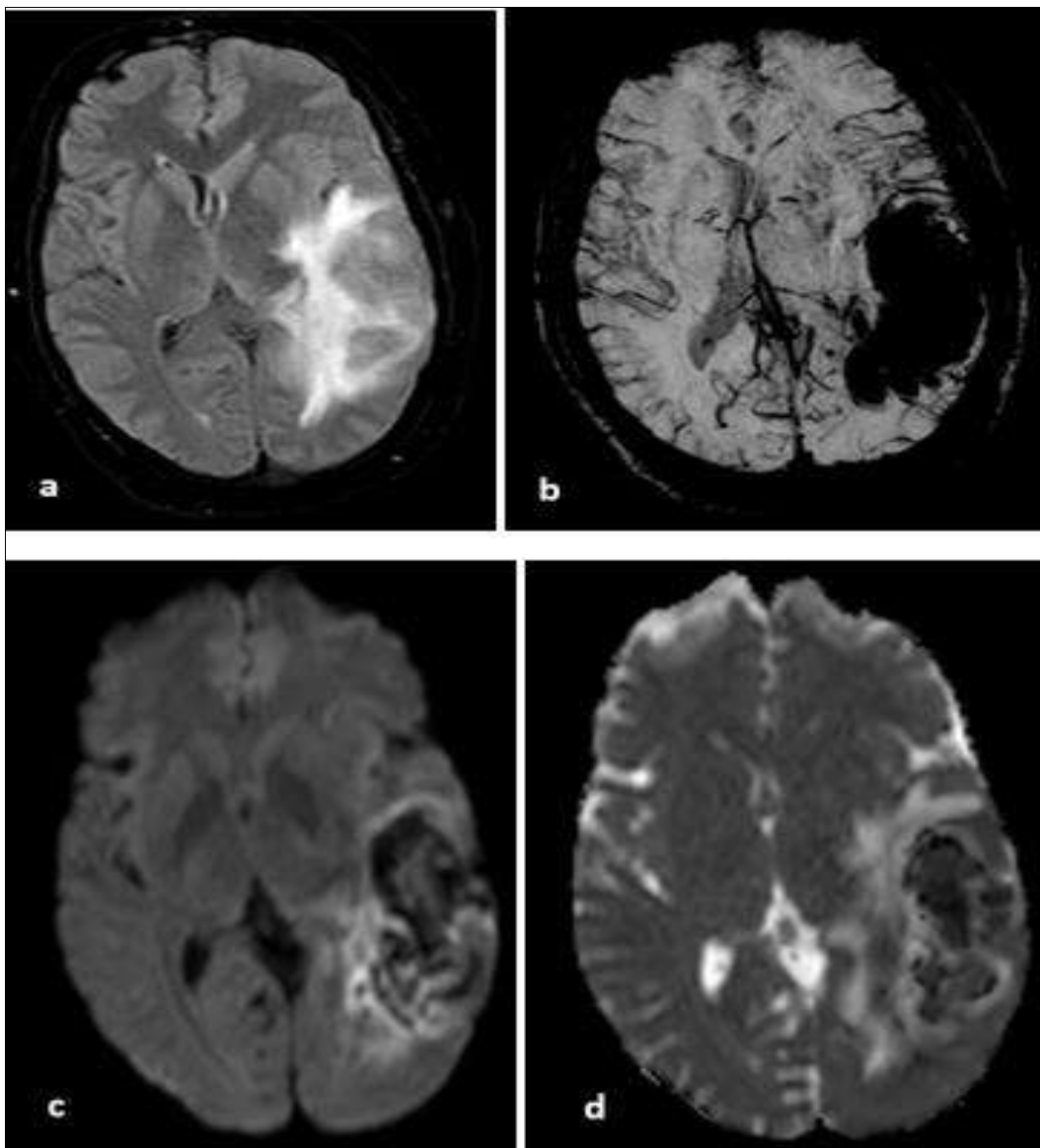
**Table 8:** Accuracy of MR TOF venography against Contrast enhanced MR venography in diagnosing LS thrombosis

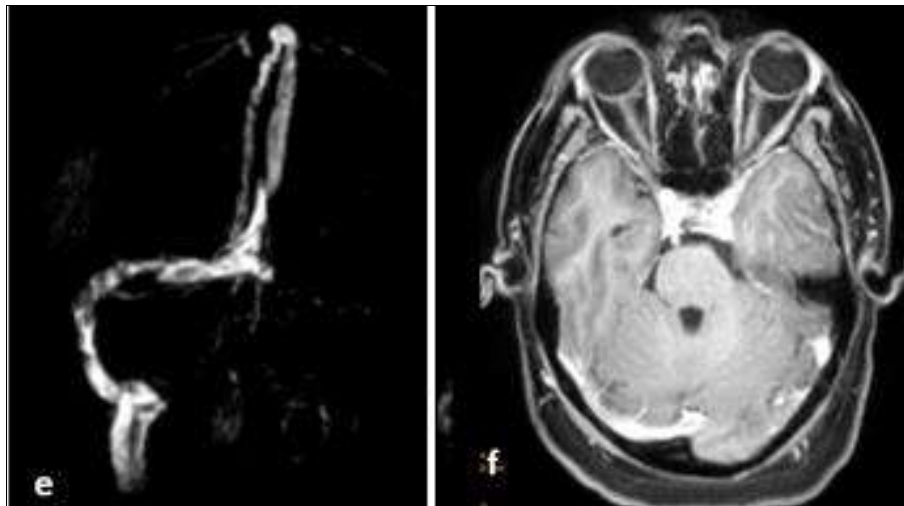
MR TOF	Contrast enhanced MR venography		Total
	Positive Diseased	Negative (Non-diseased)	
Positive	19	4	23
Negative	5	2	7
Total	24	6	30

Statistic	Value	95% CI
Sensitivity	79.17%	57.85% to 92.87%
Specificity	33.33%	4.33% to 77.72%
Positive Likelihood Ratio	1.19	0.65 to 2.17
Negative Likelihood Ratio	0.63	0.16 to 2.47
Disease prevalence (*)	80.00%	61.43% to 92.29%
Positive Predictive Value (*)	82.61%	72.24% to 89.66%
Negative Predictive Value (*)	28.57%	9.19% to 61.25%
Accuracy (*)	70.00%	50.60% to 85.27%

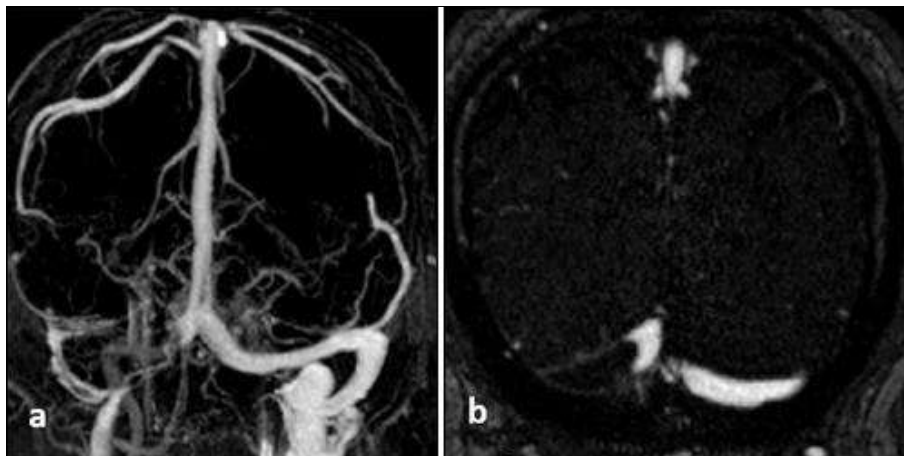
**Table 9:** Accuracy of MR TOF venography against Contrast enhanced MR venography in diagnosing STS thrombosis

MR TOF	Contrast enhanced MR venography		Total
	Positive(Diseased)	Negative (Non-diseased)	
Positive	7	15	22
Negative	0	8	8
Total	7	23	30

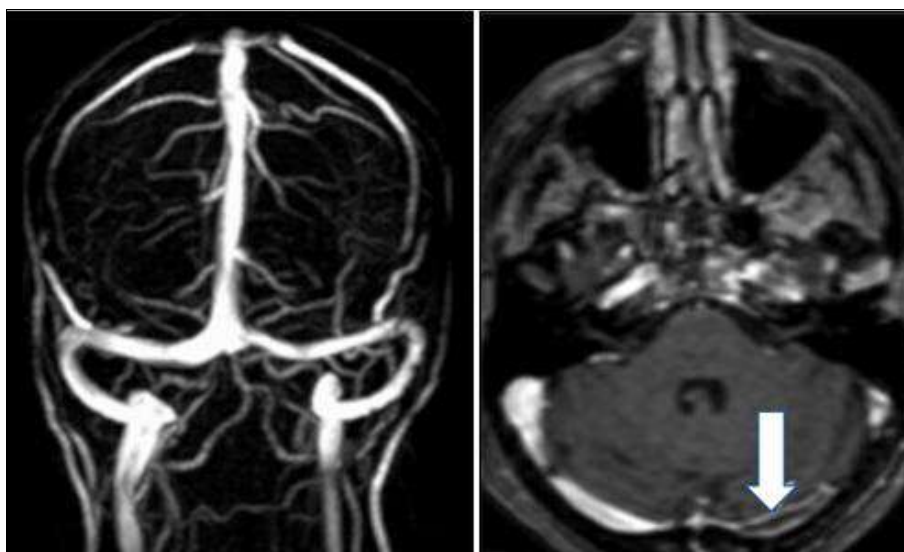




**Fig 1:** Cerebral venous thrombosis involving left transverse and sigmoid sinuses with acute haemorrhagic infarct. (a) FLAIR showed hyper intensities noted in left temporo parieto-occipital region, left capsule-ganglionic region.(b) SWI showed blooming (c) DWI showed areas of restricted diffusion and (d) ADC showed corresponding signal drop.(e) TOF image showed non visualisation of transverse and sigmoid sinuses (f) Post contrast showed filling defect in left transverse and sigmoid sinuses.



**Fig 2:** A case of proximal right transverse sinus thrombosis.(a) TOF image showed absence of proximal portion of the right lateral sinus (b) CE-MRV showed intraluminal filling defect in right lateral sinus.



**Fig 3:** (a) TOF MRV appears normal (b) CE MRV showed intraluminal filling defect in left proximal transverse sinus.

**Discussion**

The present study was carried out with an aim to compare the accuracy between conventional MRV with 2D time of flight sequence versus contrast enhanced MRV in Cerebral

venous sinus thrombosis as a hospital based ambispective study comprising 30 patients.

The majority of the study's participants were under 25 years old. Khaladkar SM *et al.* observed in their study that most of

the patients with cerebral venous sinus thrombosis were in the age group of 21-40 years. These findings were comparable to that of the demographic characteristics of the study participants in the present research work [3].

Majority of the patients were females (73.3%) and most of them were in puerperium. Data from the International Study by Coutinho *et al.* on Cerebral Vein and Dural Sinus Thrombosis showed a female to male ratio of 3:1 and median age was 34 years [4].

Majority of the study patients had headache on presentation (73.3%). Altered sensorium was present in 13.3% of the patients at the time of presentation. This was like previous studies.

Issar P, *et al.* study of fifty cases of cerebral venous thrombosis, observed that majority of their patients presented with headache (78%) followed by seizures (32%). Similar and concordant clinical presentation was noted in the present study findings as well [5].

Hemanandani VN, *et al.* study results stated that Hyperhomocysteinemia in males and puerperium in females were found to be the most frequent etiologies, followed by DM in both sexes. Over 70% of cases of cerebral venous thrombosis are in women because it is linked to hormonal factors (primarily oral contraceptives) and pregnancy. The third trimester and the first month after giving birth are the times when cerebral venous sinus thrombosis is most likely to occur, with the puerperium accounting for 73% of cerebral venous sinus thrombosis in women. Identically majority of the study participants in the present study was puerperal women [6].

Canedo Antelo *et al.* studied that only 40-60% of individuals with cerebral venous thrombosis had parenchymal problems. Parenchymal changes could be found close to the sinus's discharge. Intraparenchymal hemorrhage and vasogenic and cytotoxic oedema, which are occasionally detected simultaneously, are the most often seen abnormalities in the parenchyma [3]. In our study all patients showed parenchymal changes.

Hemanandani VN, *et al.* reported in their study that Superior sagittal sinus (SSS), (n=34) was the most frequently involved sinus in thrombosis in the 46 cases out of 100 cases that had cerebral venous sinus thrombosis. 23 cases had venous infarcts, and 10 of those cases had both transverse and superior sagittal sinus thrombosis [2]. Issar P *et al.* study also documented that out of the total 50 cases, superior sagittal sinus were involved in 24 cases, left transverse sinus in 22 cases, right transverse in 12 cases, left sigmoid in 20 cases, right sigmoid in 13 cases, left internal jugular vein in 12 cases, right internal jugular vein in 7 cases, straight sinus in 5 cases, superficial cortical veins in 6 cases, vein of Galen in 3 cases and internal cerebral veins in 2 cases [6]. Khaladkar SM, *et al.* research article documented that the deep venous system was affected in seven (17.5%) patients, and superficial venous system affected in 2.5% of cases [3]. These proportion and pattern in the above discussed study was similar to that of the present study.

Fu JH, *et al.* in their study on comparison of the areas under the receiver operating characteristic curves revealed that 3D GEC MRV was superior to 2D TOF MRV (0.91) by 0.53 points. The percentage of complete visualization of venous structures was also higher for 3D GEC (95.8%) than for 2D TOF (62.1%) MRV in the remaining 31 healthy patients [7].

Comparable proportions were noted in the present research work also, however, post contrast MRV was used for comparison in our study.

Contrast-enhanced MRI was superior to non-contrast enhanced flow-related and native contrast thrombus MR sequences for diagnosing cerebral sinus thrombosis when Digital Subtraction Angiography (DSA) was employed as the reference standard, with a sensitivity and specificity of 83% and 100% versus 8-51% and 80-93%, respectively [8].

Other studies employed contrast-enhanced MRV<sup>4</sup> or numerous imaging modalities combined with final clinical outcome as a reference. Contrast-enhanced MRI performed better in these latter studies than non-contrast-enhanced MRI in terms of cerebral venous sinus thrombosis sensitivity and specificity, scoring 86-97% and 52-100% versus 55-97% and 28-95%, respectively. These works by various authors in the past substantiate the use of CE MRV as reference standard for calculating the measures of accuracy for MR TOF sequence in assessing various parameters in the diagnosis of cerebral venous sinus thrombosis.

Sensitivity and specificity of MR TOF in diagnosing various sinus thrombosis ranged from 42% to 100% and 30% to 50%, respectively in the present study.

Hemanandani VN, *et al.* [6] study results noted that among the Non- cerebral venous sinus thrombosis cases, 3 patients underwent contrast-enhanced MRIs of the brain, which were found to be negative. As a result, this study's CE-MRI brain's sensitivity and specificity were both determined to be 100%.

In the study by Renard D, *et al.* [9], 25 cerebral venous sinus thrombosis patients were studied and blinded analysis reduced the 3D-TOF sequences' sensitivity to 80% while only achieving a 65% specificity. Comparable measures of accuracy were documented in the results of the present study also.

Imaging enables comprehension of the primary pathophysiological hemodynamic changes brought on by venous thrombosis and allows for outcome prediction. The range of pathophysiological alterations that follow venous blockage are reflected in this variability. The diagnosis and management of cerebral venous sinus thrombosis are primarily handled by clinical neuroradiology. To minimise potential hazards, care should be taken while interpreting MR images. If the radiologist is aware of important diagnostic problems, MRI or MRI venography (MRV) are effective procedures. In certain circumstances, cerebral digital subtraction angiography (DSA) can help with diagnosis and trans catheter thrombolytic/anticoagulant therapy, which can improve clinical result.

## Conclusion

Multicentric large scale studies involving patients from different backgrounds of variable demography is required to clearly establish the accuracy of MRI investigations. The performance of contrast enhanced 3D MRV was superior in terms of picture quality and evaluation of all sinuses and veins. The findings of our study contribute to the body of data supporting the advantages of contrast enhanced 3D MR venography over 2D TOF MR Venography in the routine clinical diagnosis or exclusion of acute CVT.

Conventional MRI brain FLAIR sequence can be strongly recommended in CVT cases to know the parenchymal changes [6].

When compared to PC MR Venography and standard MR images, contrast-enhanced 3D GE T1-weighted MR images had the highest sensitivity, specificity, and accuracy for diagnosing dural sinus and/or cortical venous thrombosis. These images can be obtained in about 5 minutes. However, in some circumstances, such as those with isolated cerebral venous thrombosis and with early subacute thrombus material that is hyperintense on T1- and hypointense on T2-weighted images, conventional MR sequences and MR venography may offer additional information [6].

The occurrence of isolated or associated cerebral venous thrombosis should be carefully assessed in situations where there is cortical venous thrombosis since infarction and hemorrhage appear to occur more frequently in these cases [6].

### Conflict of Interest

Not available

### Financial Support

Not available

### References

1. Canedo-Antelo M, Baleato-González S, Mosqueira AJ, Casas-Martínez J, Oleaga L, Vilanova JC, *et al.* Radiologic Clues to Cerebral Venous Thrombosis. *Radiogr Rev Publ Radiol Soc N Am Inc.* 2019 Oct;39(6):1611–28.
2. Sadigh G, Mullins ME, Saindane AM. Diagnostic Performance of MRI Sequences for Evaluation of Dural Venous Sinus Thrombosis. *AJR Am J Roentgenol.* 2016 Jun;206(6):1298–306.
3. Khaladkar SM, Thakkar DK, Thakkar DK, Shrotri H, Kulkarni VM. Cerebral venous sinus thrombosis on MRI: A case series analysis. *Med J Dr Patil Univ.* 2014 May 1;7(3):296.
4. Coutinho JM, Ferro JM, Canhão P, Barinagarrementeria F, Cantú C, Bousser MG, *et al.* Cerebral venous and sinus thrombosis in women. *Stroke.* 2009 Jul;40(7):2356–61.
5. Issar P, Chinna S, Issar SK. Evaluation of Cerebral Venous Thrombosis by CT, MRI and MR Venography. *J Assoc Physicians India.* 2017 Nov;65(11):16–21.
6. Hemanandini V.N, Aditi Jain, Ashok Kumar A, Umesh K. Role of magnetic resonance venography in clinically suspected cases of cerebral venous thrombosis. *International Journal of Contemporary Medicine Surgery and Radiology.* 2021;6(4):D53-D58.
7. Fu JH, Lai P Hong, Hsiao CC, Li SC, Weng MJ, Wang PC, *et al.* Comparison of Real-time Three-dimensional Gadolinium-enhanced Elliptic Centric-ordered MR Venography and Two-dimensional Time-of-flight MR Venography of the Intracranial Venous System. *J Chin Med Assoc JCMSA.* 2010 Mar 1;73:131–8.
8. Liang L, Korogi Y, Sugahara T, Onomichi M, Shigematsu Y, Yang D, *et al.* Evaluation of the intracranial dural sinuses with a 3D contrast-enhanced MP-RAGE sequence: prospective comparison with 2D-TOF MR venography and digital subtraction angiography. *American Journal of Neuroradiology.* 2001 Mar 1;22(3):481-92.
9. Renard D, Le Bars E, Arquizan C, Gaillard N, De Champfleury NM, Mourand I. Time-of-flight MR angiography in cerebral venous sinus thrombosis. *Acta*

Neurol Belg. 2017 Dec;117(4):837–40.

### How to Cite This Article

Dr. Harshana Subramaniam, Dr. Prabhu CS, Dr. Raju and Dr. Colonel Sudhir Sachar. A comparative study of conventional magnetic resonance sequences with 2D time of flight sequence versus contrast enhanced magnetic resonance venography in diagnosing cerebral venous sinus thrombosis. *International Journal of Radiology and Diagnostic Imaging* 2022; 5(4): 113-118.

### Creative Commons (CC) License

This is an open access journal, and articles are distributed under the terms of the Creative Commons Attribution-NonCommercial-ShareAlike 4.0 International (CC BY-NC-SA 4.0) License, which allows others to remix, tweak, and build upon the work non-commercially, as long as appropriate credit is given and the new creations are licensed under the identical terms.