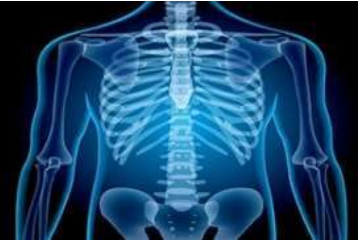

# International Journal of Radiology and Diagnostic Imaging



E-ISSN: 2664-4444  
P-ISSN: 2664-4436  
[www.radiologypaper.com](http://www.radiologypaper.com)  
IJRDI 2023; 6(1): 20-24  
Received: 01-10-2022  
Accepted: 05-11-2022

**Dr. Palachuru Sandeep Anirudh**  
Post Graduate, Department of Radiodiagnosis, Mahatma Gandhi Medical College and Research Institute, Sri Balaji Vidyapeeth University, Puducherry, India

**Lokesh Kumar T**  
Associate Professor, Department of Radiodiagnosis, Mahatma Gandhi Medical College and Research Institute, Sri Balaji Vidyapeeth University, Puducherry, India

**Ilamaran V**  
Professor, Department of Paediatrics, Mahatma Gandhi Medical College and Research Institute, Sri Balaji Vidyapeeth University, Puducherry, India

**Col Sudhir Sachar**  
Professor & HOD, Department of Radiodiagnosis, Mahatma Gandhi Medical College and Research Institute, Sri Balaji Vidyapeeth University, Puducherry, India

**Corresponding Author:**  
**Dr. Palachuru Sandeep Anirudh**  
Post Graduate, Department of Radiodiagnosis, Mahatma Gandhi Medical College and Research Institute, Sri Balaji Vidyapeeth University, Puducherry, India

## Magnetic resonance volumetric analysis of hippocampal lobe in children aged 6 years or younger presenting with seizures

**Dr. Palachuru Sandeep Anirudh, Lokesh Kumar T, Ilamaran V and Col Sudhir Sachar**

**DOI:** <http://dx.doi.org/10.33545/26644436.2023.v6.i1a.300>

### Abstract

**Background:** Magnetic Resonance (MR) imaging studies are sufficient for detection of gross Hippocampal Atrophy (HA), subtle HA that may characterize early disease is often missed. Quantitative MR imaging/ MR volumetry can depict the presence and laterality of HA in epilepsy with accuracy rates that may exceed those achieved with visual inspection of clinical MR imaging studies.

**Materials and Methods:** The study comprised of Children at or below 6 years of age admitted in pediatric ward for seizure from July 2019 to December 2020 in Mahatma Gandhi Medical College Hospital and Research Institute presenting with seizures, admitted to pediatric department, and referred to radiodiagnosis for MRI. Complete case history including the socio-demographic data and other medical conditions of the patient was recorded.

**Results:** The maximum no of patients were recorded in the age range of 13-24 years, with a slight male predominance. 44.76% patients suffering from generalized seizures, followed by 35.24% with focal seizures & 20% with undetermined form of seizures. Mean right & left hippocampal volume was found to be 2.572 & 2.4168 respectively. The mean right hippocampal volume in patients suffering from focal, generalized & undetermined patients was found to be 2.56, 2.53 & 2.67, & on left side it was 2.34, 2.42 & 2.45 respectively. The mean right hippocampal volume in patients as per the frequency/episode of 1-3, 4-6, 1-9 & 10 & above per month was found to be 2.6, 2.48, 2.41 & 2.685 & on left side it was 2.44, 2.33, 2.35 & 2.65.

**Conclusion:** The use of MRI has been well-established as a reliable marker for the assessment of the mean volume of the hippocampus which is commonly seen to be involved in patients with seizures. We found a correlation between the mean hippocampal volume against the frequency of seizures wherein there was an increase in the volume with an increase in the frequency of seizures. We recommend more studies to understand these associations as there are deficit in terms of these parameters.

**Keywords:** Magnetic resonance imaging, hippocampus, epilepsy, seizures, hippocampal volume, focal seizures

### 1. Introduction

The hippocampus is a bilaminar gray matter structure located medially in the temporal lobe that protrudes over the temporal horn of the lateral ventricle and occupies the medial region of its floor. The hippocampus consists of two interlocking gray matter folds, the cornu ammonis and the dentate gyrus <sup>[1]</sup>.

A seizure is a paroxysmal electrical discharge of neurons in the brain resulting in an alteration of function or behaviour. The area of cortical involvement, the direction and speed of the electrical impulse, and the age of the child all contribute to the clinical manifestations of the seizures. Seizures occur in approximately 4% to 10% of children. Children under 3 years of age have the highest incidence of seizures <sup>[2]</sup>.

Partial seizures originate in one cerebral hemisphere. A simple partial seizure has no impairment of consciousness, and most commonly manifests as abnormal motor activity. When an alteration of consciousness is present, the seizure is classified as a complex partial seizure. Generalization occurs in approximately 30% of children. A generalized seizure involves both cerebral hemispheres and may involve a depressed level of consciousness <sup>[2]</sup>. Although most clinical Magnetic Resonance (MR) imaging studies are sufficient for detection of gross Hippocampal Atrophy (HA), subtle HA that may characterize early

disease is often missed. To facilitate clinical interpretation, quantitative volumetric methods have been developed and these methods correlate well with manual tracings and histologically confirmed hippocampal cell loss<sup>[3]</sup>.

Smaller hippocampal lobe volumes have been reported in epilepsy. This study is done to determine the association of hippocampal volume with childhood seizures. To measure the values of right and left hippocampal lobe volumes in children aged 6 years or younger presenting with seizures using MR volumetric analysis. To assess correlation of hippocampal volume with type of seizures and seizure frequency.

## 2. Materials & Methods

After obtaining approval from institutional review and human ethics committee, this cross sectional analytical study was conducted in Mahatma Gandhi Medical College Hospital and Research Institute. Study subjects will be children aged 0-6yrs presenting with seizures, admitted to pediatric department and referred to radiodiagnosis for MRI from Jul 2019 to Dec 2022. Children aged 0-6 years were recruited retrospectively from July 2019 to Dec 2020 and prospectively from Jan 2021 to Dec 2022.

### 2.1 Inclusion criteria

- Children aged 0 – 6 years diagnosed with seizures clinically and referred to department of Radiodiagnosis for MRI brain.
- Follow up children of same age group with seizures (focal, febrile, non febrile, cryptogenic)

### 2.2 Exclusion criteria

- Children having claustrophobia
- Children having history of metallic implants insertion, cardiac pacemaker and metallic foreign body in-situ.
- Children clinically unstable.
- Children presenting with secondary seizure and other causes of Hippocampal atrophy like Cushing's disease, survivors of low birth weight, Herpes simplex encephalitis, Turner's syndrome, Down's syndrome, PTSD.

The source of retrospective data will be the archives of the Radiodiagnosis department and medical records from pediatric department. Children presenting to pediatric OPD/Emergency with new onset seizure or for follow up and advised for MRI will be enrolled prospectively by sequential sampling. After obtaining informed and written consent from the patient. The patients underwent MRI to obtain hippocampal volumes using specific sequences.

### 2.3 Procedure

MRI examinations will be performed for all the children enrolled prospectively using a Philips ACHIEVA 1.5 Tesla MRI scanner. The child will be sedated and monitored by the pediatrician who will be referring the patient to radiology for MRI.

To sedate the child the pediatrician will first give Pedicloryl 0.5ml/kg of syrup as an initial effort to make the child drowsy and cooperative. Wherever possible sleep deprivation will be done previous night. If there is no affect another 0.5 ml/kg (total maximum dose - 10 ml) of the syrup is given. If syrup does not cause the intended level of sedation Midazolam injection intravenous 0.1mg/kg/dose

will be given with adequate back up for respiratory support in case of adverse event. In cases when that does not work Ketamine will be given intravenously slowly, (dose - 1.5 – 2 mg/kg) under the supervision of an anesthetist. Child will be monitored and in case of adverse event will be managed by pediatrician and anesthetist with the help of all the emergency care aids present in the department.

Brain and temporal lobe series MRI will be performed for all the children enrolled prospectively. MRI of brain will be performed consisting of sagittal T1, axial T1, T2 and Fluid Attenuation Inversion Recovery. These sequences will be performed with 5 mm thickness and a 2 mm gap. The temporal lobe series will be consisting of coronal T2, FLAIR, IR, and 3D fast spoiled gradient-recalled echo (SPGR). All coronal series will be perpendicular to the long axis of the temporal lobe with 4 mm thickness and a 1 mm gap, except the 3D SPGR, which will be carried out with 2 mm thickness and a 1 mm gap. The T1-weighted series will use an echo time of 11 ms, repetition time of 420 ms, 20 mm \* 20 mm field of view, and 2.0 NEX. The hippocampal volume will be measured on coronal IR, and ICV will be measured on the T1-weighted sagittal view. HCVs will be measured from the oblique coronal MR images perpendicular to the long axis of HC. MRI sequences and parameters will be presented in the table.

**2.3.1 Hippocampal volume measurement:** HCVs will be manually delineated on successive coronal slices using a modified protocol based on previously published methods. The left and right parts of HCV will be obtained using manual tracing. A slice volume will be calculated by multiplying the area outlined by the slice thickness. The whole volume will be calculated by adding all the slice volumes. The total average time required for a trained individual to segment and calculate the HCV will be approximately 1 hour.

### 2.4 Data collection

All data was entered into a Data Collection Proforma Sheet and was entered into Excel (MS Excel 2019). Other biographical details were also collected including age.

### 2.5 Statistical methods

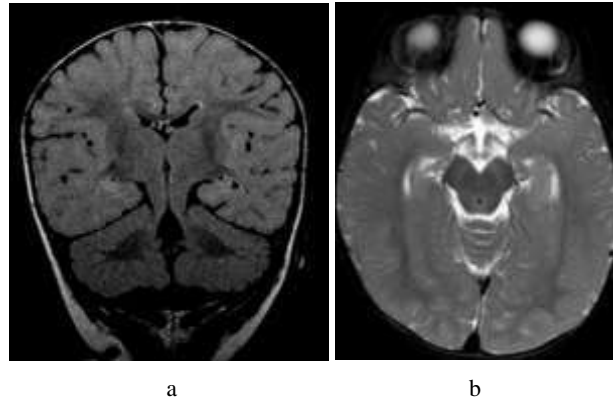
Qualitative data will be expressed as frequency and percentage. The variables like right and left hippocampal volumes were compared with normative data. Statistical analysis was carried out using SPSS version 22.0 (IBM SPSS, US) software.

## 3. Results

- The maximum no of patients were in the age range of 13-24, followed by 0-12, 37-47 in the frequency of 19.05%, 18.12% & 17.15% respectively.
- We had 53 male & 52 female subjects as a part of our study.
- 44.76% patients suffered from generalized seizures, followed by 35.24% with focal seizures & 20% with undetermined form of seizures.
- The majority of the patients accounting for 50.48% suffered from 1-3 episodes of seizures, followed by 29.52% having 4-6 episodes, 11.43% having 7-9 episodes and 8.57% having 10 episodes or more.
- Mean right & left hippocampal volume was found to be 2.572 & 2.4168 respectively, which was found to be

- statistically significant.
- Mean right hippocampal volume in patients suffering from focal, generalized & undetermined patients was found to be 2.56, 2.53 & 2.67 respectively, while it was 2.34, 2.42 & 2.45 on the left side.

- The mean right hippocampal volume in patients as per the frequency/episode of 1-3, 4-6, 1-9 & 10 & above per month was found to be 2.6, 2.48, 2.41 & 2.685 respectively, while it was 2.44, 2.33, 2.35 & 2.65 on the left side.



**Fig 1:** (A) FLAIR Coronal showing subtle hyperintense signal in Left hippocampus which appears, (B) T2 SPAIR Axial showing edematous left hippocampus

**Table 1:** Frequency of Seizure (Per Month)

Frequency (Per Month)	Number	Frequency
1-3	53	50.48
4-6	31	29.52
7-9	12	11.43
10 & ABOVE	9	8.57

**Table 1:** Comparison of Left & Right Hippocampal Volume

Hippocampal Volume	Right	Left
Mean	2.572	2.4168
S.D	0.4725	0.4067
Ratio	1.064	
P	0.005723	

The result is significant at  $p < 0.05$

**Table 3:** Correlation of Right & Left Hippocampal Volume with Type of Seizure

Type of seizure	Mean Volume	S.D	P
Focal	2.567	0.469	0.521984
Generalised	2.5309	0.4646	
Undetermined	2.6729	0.5037	

Type of seizure	Mean	S.D	P
Focal	2.395	0.4307	0.867025
Generalised	2.417	0.394	
Undetermined	2.455	0.4084	

**Table 4:** Correlation of right & left hippocampal volume with frequency of seizure

Frequency (Per Month)	Mean Volume	S.D	P
1-3	2.642	0.4795	0.024254
4-6	2.4806	0.4269	
7-9	2.4133	0.4917	
10 & Above	2.6856	0.5245	

The result is significant at  $p < 0.05$

Frequency (Per Month)	Mean Volume	S.D	P
1-3	2.4396	0.4402	0.0181386
4-6	2.3335	0.3402	
7-9	2.3517	0.4485	
10 & Above	2.6556	0.2821	

The result is significant at  $p < 0.05$

#### 4. Discussion

Individuals suffering from seizures have a compromised lifestyle which has an overwhelming effect on the physical, mental, social as well as professional upfront and hence early, detection and assessment helps to prevent as well as improve the lifestyle of the individual.

Amongst the various parameters, hippocampal volumetry is a common tool used by the diagnosticians for detection and lateralization of the mesial temporal lobe epilepsy, which is alleged to be the most common assessment parameter [1].

There are a plethora of diagnostic tests which are used to assess the volume of the hippocampus wherein MRI has been found to have the upper hand in reaching a final diagnosis which can clearly define the sclerotic changes as well as the atrophic changes in the hippocampus, making it the choice of imaging diagnostic modality [6].

Conventionally hippocampus is defined by segmenting the hippocampus across the serial sections of a T1-weighted magnetic resonance imaging (MRI) scan which is found to have attained in the line perpendicular to the long axis of the hippocampus [1].

Hippocampal sclerosis has been deemed as the primary cause for the intractable temporal lobe epilepsy, which is of refractory origin. Herein, the patient suffers from complex-focal, prolonged or repetitive-febrile seizures (CFS) in infancy or early childhood. Even though diagnosis by other techniques is possible, the use of MRI is highly recommended [6-10].

We recorded the maximum no of patients in the age range of 13-24 accounting for 19.05%, followed by 0-12 & 37-47 months age group, then 25-36, 48-60 & 61-72 months. Across all the age groups we found a negligible change of 1% each in a descending pattern.

The detection of seizures as early as 13-24 months was suggestive of early stage changes, which required further diagnostic assessment.

Similar pattern was observed by Szabo CA et al., [6] who recorded the majority of the patients of the study that is 40% in the age range of 13-24 years to be affected, with the other age groups being 1-12 months, 37-47 months & 61-72 months (20% patients in each group)

However, Obeanus et al.,<sup>[11]</sup> recorded only 1 patient each in age group 16.66% patients to be affected in the age range of 13-24 years & 25-36 years and 66.65% of patients in the age range of 48-60 years age to be affected.

Utsunomiya et al.,<sup>[12]</sup> consisted of 42 subjects aged 3 weeks to 14 years, wherein they recorded the mean age to be 5 years.

There is substantial evidence that is present which proves that the volume of hippocampus increases continuously until the age of 2 years & then attains a more controlled growth. They have also found that toddlers and preschool children there is an indiscrete change in the hippocampal volume in the left & right hippocampus with progressive age<sup>[4,6]</sup>.

We had a slight male predominance against the female gender with 50.48% male patients.

MR-based hippocampal volume (HCV) is most commonly used to assess any changes in the hippocampus, as there are reports suggestive of changes in TLE which are responsible for unilateral HS, with approximately 65% of the patients showing lesions in the hippocampus. Thus the volume of hippocampus provides an insight into the changes that are observed within the hippocampus which helps to provide an accurate diagnosis of the disease process as well as its progression, and the outcome in the initial phases itself<sup>[15,16]</sup>.

We recorded the mean right & left hippocampal volume to be 2.572 & 2.4168 respectively, which was found to be statistically significant. The right hippocampus was slightly more in volume in comparison to the left one. Further, we recorded the total volume of both hippocampal lobe volume to be 4.9888, with the ratio of right: left lobe being 1.064. This was in agreement with the study results of other researchers.

Grunewald et al.,<sup>[10]</sup> recorded the right hippocampal & left hippocampal value to be 2.353 & 2.274, with a ratio of 1.12. Similarly, Szabo et al.,<sup>[6]</sup> found the mean right & left hippocampal volume in their study to be 3.60 & 3.08 and on further correlation with other parameters found that children with CFS had more right hippocampal volumes than the left one. Mulani SJ et al.,<sup>[4]</sup> also found the mean RHV to be 2.75 cm<sup>3</sup> and mean LHV to be 2.49 cm<sup>3</sup>.

Jack CR. et al.,<sup>[17]</sup> also found the RHV to be larger than LHV. There is convincing data that the mean hippocampal volume below 1.83 cm<sup>3</sup> is considered as abnormal & also that hippocampal volumes increases with age until adulthood.<sup>6</sup> The changes in the hippocampal volume has also been attributed to the asymmetry which is caused due to developmental immaturity.<sup>6</sup>

It is also hypothesized that the higher right to left hippocampal asymmetry is probably associated with the smaller total hippocampal volumes in children with CFS, which in turn may be partly due to their younger mean age.

Zhang et al.,<sup>[18]</sup> The mean LHCV was 2.07 & RHCV to be 2.09 respectively, which also was in agreement with our study results.

As per our analysis in terms of the type of seizures suffered in our study, we recorded 44.76% patients suffering from generalized seizures, followed by 35.24% with focal seizures & 20% with undetermined form of seizures.

We further correlated the form of seizure against the hippocampal values and found that the mean right hippocampal volume in patients suffering from focal, generalized & undetermined patients was found to be 2.56, 2.53 & 2.67 respectively, whereas it was 2.34, 2.42 & 2.45

on the left side.

Seizure onset can be focal (seizures arising in one hemisphere of the brain), generalized (seizures originating in both hemispheres simultaneously), and unknown. Focal seizures are classified according to whether awareness (a marker for consciousness) is intact or impaired<sup>[19,20]</sup>.

Hippocampal injury after febrile or afebrile convulsive status have been reported in individual cases: unilateral or bilateral hippocampal edema in the acute stage, followed by hippocampal atrophy and sclerosis within months to years.<sup>6</sup>

We had a predominance of generalized seizure cases with the mean hippocampal value in the both the quadrants that is the right & the left was found to be median to that observed in the focal or the undetermined type of cases. In both the hippocampal lobes we found that there was an increased volume in case of undetermined cases of epilepsy, whereas it was decreased in the focal form. It is usually observed that seizures are more commonly focal in nature but the cause remains undetermined in about 60% of the cases.

There are high chances that MR imaging alone can sometimes be misleading in terms of detection of atrophy of the hippocampus, which is like that observed in the tertiary epilepsy program wherein the neurologists missed out the atrophic changes on the normal MR imaging, however this can be overcome by MR volumetric assessment of the hippocampus. Therefore, the term expert "eye" has been assigned to MR volumetric imaging<sup>[22]</sup>.

It has been suggested that the mean volume of hippocampus is more in the western world in terms of the global scale and in INDIA, it is more also in the northern region in comparison to the other parts, which is subject to variation as per their demographic location<sup>[23]</sup>.

Amongst the three types of seizures, the undetermined type of seizure showed the highest volume of mean hippocampal values, followed by the generalized type of seizure and the least volume in focal type of seizure.

Thus, the correlation of these parameters in terms of the mean hippocampal volume on both the sides against the type of seizures was concreted.

Most of the patients accounting for 50.48% suffered from 1-3 episodes of seizures, followed by 29.52% having 4-6 episodes, 11.43% having 7-9 episodes and 8.57% having 10 episodes or more.

The mean right hippocampal volume in patients as per the frequency/episode of 1-3, 4-6, 7-9 & more than 10 seizures per month was found to be 2.6, 2.48, 2.41 & 2.685 respectively, whereas it was 2.44, 2.33, 2.35 & 2.65 respectively.

The mean hippocampal levels on both sides were found to be the highest in patients with more than 10 seizures per month, followed by those suffering from 1-3 seizures per month. However, patients with 4-9 seizures per month recorded lesser hippocampal volume.

However, in comparison to mean hippocampal volume, we found that the mean intracranial volume was highest in patients with 7-9 seizures per month, followed by more than 10 seizures per month. Therefore, there exists a correlation between with increased frequency of seizures which can be detected & assessed in terms of mean hippocampal volume.

However, there exist certain limitations such as that MRI cannot be always performed in patients with idiopathic epilepsy or known symptomatic causes for their seizures are questionable & only required when clinical deterioration is doubted.



Our study was well planned with an effective sample size; however, the lack of a control group along with periodic follow-up of the patients were the drawbacks of our study. The follow-up of such a large sample size for a long period of time was difficult & was the main reason for not making it a part of the study protocol.

## 5. Conclusion

The use of MRI has been well-established as a reliable marker for the assessment of the mean volume of the hippocampus which is commonly seen to be involved in patients with seizures. We found a correlation between the mean hippocampal volume against the frequency of seizures wherein there was an increase in the volume with an increase in the frequency of seizures. We recommend more studies to understand these associations as there are deficit in terms of these parameters.

## 6. Acknowledgments

My deepest gratitude and sincere thanks to my Guides, Dr. Lokesh Kumar. T, Professor, Department of Radiodiagnosis, Dr. Ilamaram. V, Professor, Department of Pediatrics and Prof. Dr. Col. Sudhir Sachar, Professor and HOD, Department of Radiodiagnosis, Mahatma Gandhi Medical College and Research Institute, Pondicherry for their constant support, encouragement and guidance which helped me to complete my work.

## 7. References

- Bernasconi N. Mesial Temporal Damage in Temporal Lobe Epilepsy: A Volumetric MRI Study of the Hippocampus, Amygdala and Parahippocampal Region. *Brain*. 2003;126(2):462-469.
- Quantification of Hippocampal Volume and Signal in Mesial Temporal Lobe Epilepsy Improves Detection of Hippocampal Sclerosis. *American Journal of Neuroradiology*. 2014;35(1):77-83.
- Cook MJ, Fish DR, Shorvon SD, Straughan K, Stevens JM. Hippocampal Volumetric And Morphometric Studies in Frontal and Temporal Lobe Epileps. *Brain*. 1992;115(4):1001-1015.
- Pardoe, Heath R, Gaby S Pell, David F Abbott, Graeme D Jackson. Hippocampal Volume Assessment in Temporal Lobe Epilepsy: How Good Is Automated Segmentation? *Epilepsia*. 2009;50(12):2586-2592.
- Pfluger, Thomas, Sabine Weil, Serge Weis, Christian Vollmar, Dirk Heiss, *et al*. Normative Volumetric Data of the Developing Hippocampus in Children Based on Magnetic Resonance Imaging. *Epilepsia*. 1999;40:414-423.
- Theodore WH, Bhatia S, Hatta J, Fazilat S, DeCarli C, Bookheimer SY, *et al*. Hippocampal atrophy, epilepsy duration, and febrile seizures in patients with partial seizures. *Neurology*. 1999;52(1):132-136.
- Mulani SJ, Kothare SV, Patkar DP. Magnetic resonance volumetric analysis of hippocampi in children in the age group of 6-to-12 years: A pilot study. *Neuroradiology*. 2005;47(7):552-527.
- Jalaluddin WM, Mat Jusoh N, Ali Basahai IA, Abdullah MS, Abdul Karim AH, Gazali AK. Normalised MRI Volumetry of the Hippocampus among Normal Malay Children and Adolescents. *Malays J Med Sci*. 2013;20(1):31-38.
- Szabó CA, Wyllie E, Siavalas EL, Najm I, Ruggieri P, Kotagal P, *et al*. Hippocampal volumetry in children 6 years or younger: assessment of children with and without complex febrile seizures. *Epilepsy Res*. 1999;33(1):1-9
- Babb TL, Brown WJ. Pathological findings in epilepsy. In: J Engel Jr, ed. *Surgical treatment of the epilepsies*. New York: Raven Press; c1987. p. 520-524.
- DeGiorgio CM, Tomiyasu U, Gott PS, *et al*. Hippocampal pyramidal cell loss in human status epilepticus. *Epilepsia* 1992;33:23-27.
- Dam AM. Epilepsy and neuron loss in the hippocampus. *Epilepsia*. 1980;21:617-629.
- Grünewald RA, Jackson GD, Connelly A, *et al*. MR detection of hippocampal pathology in epilepsy: factors influencing T2 relaxation time, *AJNR Am J Neuroradiol*. 1994;15:1149-1156.
- Obenaus A *et al*. A Reliable Method for Measurement and Normalization of Pediatric Hippocampal Volumes. *pediatric research*, 2001, 50(1).
- Utsunomiya H, Takano K, Okazaki M, Mitsudome A. Development of the temporal lobe in infants and children: analysis by MR-based volumetry. *AJNR Am J Neuroradiol*. 1999;20:717-723.
- Daley M *et al*. Hippocampal volume in childhood complex partial seizures. *Epilepsy Research*. 2006;72:57-66.
- Wallace SJ. Prognosis after prolonged unilateral febrile convulsions. In: Akimoto H, Kazamatsur H, Seino M, eds. *Advances in Epileptology XIIIth Epilepsy International Symposium*. New York: Raven; c1992. p. 97-99.
- Gonçalves Pereira PM, Oliveira E, Rosado P. Relative localizing value of amygdalo-hippocampal MR biometry in temporal lobe epilepsy. *Epilepsy Res*. 2006;69:147-64.
- Fuerst D, Shah J, Shah A, Watson C. Hippocampal sclerosis is a progressive disorder: A longitudinal volumetric MRI study. *Ann Neurol*. 2003;53:413-416.
- Jack CR, Twomey CK, Zinsmeister AR, Sharborough FW, Petersen RC, Cascino GD. Anterior temporal lobes and hippocampal formations: normative volumetric measurements from MR images in young adults. *Radiology*. 1989;172:549-554.
- Zhang Y, Li W, Gao Y, Li Y, Wu J, Li W. Hippocampal volume in children with temporal lobe epilepsy compared to healthy children: A magnetic resonance imaging study. *Neurol India*. 2012;60:29-35.
- Beghi E. The epidemiology of epilepsy. *Neuroepidemiology*. 2020;54:185-191.
- Fisher RS, Cross JH, French JA, Higurashi N, Hirsch E, Jansen FE, *et al*. Operational classification of seizure types by the International League Against Epilepsy: Position Paper of the ILAE Commission for Classification and Terminology. *Epilepsia*. 2017;58(4):522-530.

### How to Cite This Article

Anirudh PS, Lokesh Kumar T, Ilamaram V, Col Sudhir Sachar. Magnetic resonance volumetric analysis of hippocampal lobe in children aged 6 years or younger presenting with seizures. *International Journal of Radiology and Diagnostic Imaging*. 2023;6(1):20-24.

### Creative Commons (CC) License

This is an open access journal, and articles are distributed under the terms of the Creative Commons Attribution-NonCommercial-ShareAlike 4.0 International (CC BY-NC-SA 4.0) License, which allows others to remix, tweak, and build upon the work non-commercially, as long as appropriate credit is given and the new creations are licensed under the identical terms.