

International Journal of Radiology and Diagnostic Imaging



E-ISSN: 2664-4444
P-ISSN: 2664-4436
www.radiologypaper.com
IJRDI 2023; 6(2): 12-17
Received: 07-01-2023
Accepted: 16-02-2023

Dr. Dhaval Kumar Solanki
Junior Resident, Department
of Radiology, JJM Medical
College, Davanagere,
Karnataka, India

Dr. Trupthi Das
Junior Resident, Department
of Radiology, JJM Medical
College, Davanagere,
Karnataka, India

Dr. Jeevika MU
Professor, Department of
Radiology, JJM Medical
College, Davanagere,
Karnataka, India

Dr. Siddesh MB
Professor, Department of
Radiology, JJM Medical
College, Davanagere,
Karnataka, India

Corresponding Author:
Dr. Dhaval Kumar Solanki
Junior Resident, Department
of Radiology, JJM Medical
College, Davanagere,
Karnataka, India

Sonographic morphology of gynaecological pelvic masses and its correlation with the histopathological diagnosis

Dr. Dhaval Kumar Solanki, Dr. Trupthi Das, Dr. Jeevika MU and Dr. Siddesh MB

DOI: <https://doi.org/10.33545/26644436.2023.v6.i2a.319>

Abstract

Aim: The aim of the present study was to evaluate the sonographic morphology of pelvic masses and to correlate with the histopathological diagnosis of the patients who underwent surgical intervention.

Methods: This observational study was conducted in the Department of Radiology of JJM Medical College, Davanagere Karnataka, India for a period of 1.5 years. 100 patients with complaints suggestive of a pelvic mass were included in this study. The final diagnosis was correlated with histopathological diagnosis. The histopathological diagnosis was considered as the final diagnosis.

Results: USG scan was performed in 100 female patients who presented with history, symptoms, and signs of a pelvic mass. Majority of the patients were in the age group of 40-50 years with mean age of 34.6 years. The minimum number was in the age group of below 20 and below 60 years. The most common chief complaint of female patients enrolled in our study was pain in pelvic cavity 35 (35%) followed by pain and palpable mass 16 (16%). Menstrual irregularity, menorrhagia, post-menopausal bleeding, infertility, and amenorrhea were the other less common complaints in the female patients of our study.

Conclusion: USG is the most commonly preferred imaging tool to evaluate gynaecological masses. It is important to differentiate gynaecological and non-gynaecological masses on sonography for accurate management of the patient.

Keywords: Gynaecological pelvic mass, uterus, ovary, adnexa, ultrasonography, Histopathological diagnosis

Introduction

Pelvic ultrasonography to visualize the adnexa and the uterus is commonly performed in symptomatic and asymptomatic women of reproductive and menopausal age. Although pelvic ultrasound is highly sensitive in detecting adnexal masses, its specificity in detecting malignancy is lower. In addition, the differentiation between functional ovarian masses that will resolve over time and nonfunctional masses has tremendous implications for patients' counseling and management. Other types of adnexal cysts (such as endometrioma, mature cystic teratoma, and Para ovarian cysts) are also important to diagnose correctly since they may affect patients' fertility, may be associated with significant pelvic disease, or put the patient at risk for ovarian torsion. Thus, the correct use of pelvic ultrasonography has become an integral part of the gynecologic evaluation and exam^[1, 2] The space occupying lesions in female pelvis are very common over a wide age range. Many pathological conditions give rise to pelvic mass. It is difficult to arrive at an accurate diagnosis on clinical examination alone. Trans-abdominal and Trans-vaginal ultrasonography are precisely helpful to determine the origin of a mass from uterus or ovarian or adnexal or extra genital structures. Information about the internal anatomy and physiology of the ovary or uterus is frequently obtained during ultrasonography that would not be evident even by direct visualization of the pelvic organs at laparoscopy or laparotomy^[3].

The aim of the present study was to evaluate the sonographic morphology of pelvic masses and to correlate with the histopathological diagnosis of the patients who underwent surgical intervention.

Materials and Methods

This observational study was conducted in the Department of Radiology of JJM Medical College, Davangere for the period of 1.5 years. 100 patients with complaints suggestive of a pelvic mass include in this study. The final diagnosis was correlated with histopathological diagnosis. The histopathological diagnosis was considered as the final diagnosis.

Inclusion criteria

Female patients of all age groups with clinical suspicion of pelvic mass or chronic pelvic pain and gave written consent

Exclusion criteria

Post-operative patients and non-gynaecological female pelvic masses.

The current methods of pelvic sonography in use are transabdominal real time scanning and transvaginal real time scanning, in transabdominal scanning most often uterus and ovaries are visualized by using 3 MH transducer at a depth 10-15 cm through urinary bladder whereas with transvaginal sonography the same structures are visualized at depth 1-8 cm and 5-7 MH transducers are used. In every case, Transabdominal sonography was done and, in some cases, findings are correlated with Transvaginal sonography. In almost every case proper sonographic evaluation of uterus, endometrium, both adnexas, ovaries, bladder and anterior pelvic structure, pelvic walls, cul de sac, rectum, small bowel and posterior pelvic structures was done. Sonographic findings of each lesion were designed to assess echogenicity, shape, borders, size, composition, calcifications, septation, locularity, laterality, presence of invasion of capsule and fixation of mass. The presence or absence of ascites or other metastatic lesions were also noted in every case. Echogenicity categories included markedly hypoechoic, isoechoic, hyperechoic and anechoic. Size was defined as the maximal dimensions of the lesion. Composition was defined as solid, cystic and mixed. Borders were defined as smooth and irregular. Calcifications were divided into those located centrally within the nodule, peripherally, and none. Posterior shadowing of at least one of the suspected calcifications was required to consider the finding present. The detailed clinical history was taken and general and local pelvic examination was performed for all patients with various palpable pelvic masses on bimanual pelvic examination. Pathological evaluation was performed on all the lesions.

Results

Table 1: Patient details

Variables	N%
Age group	
Below 20	3 (3)
20-30	7 (7)
30-40	25 (25)
40-50	55 (55)
50-60	8 (8)
Above 60	2 (2)
Patients	
Premenopausal	70 (70)
Postmenopausal	30 (30)
Symptoms	
Pain in pelvic cavity	35 (35)
Pain and palpable mass	16 (16)
Pain and bleeding PV	10 (10)
Menorrhagia and menstrual irregularity	13 (13)
Post-menopausal bleeding	7 (7)
Primary amenorrhea	7 (7)
Infertility	12 (12)

USG scan was performed in 100 female patients who presented with history, symptoms, and signs of the pelvic mass. Majority of the patients were in the age group of 40-50 years with mean age of 34.6 years. The minimum number was in the age group of below 20 and below 60 years. The most common chief complaint of female patients enrolled in our study was pain in pelvic cavity 35 (35%) followed by pain and palpable mass 16 (16%). Menstrual irregularity, menorrhagia, post-menopausal bleeding, infertility, and amenorrhea were the other less common complaints in the female patients of our study.

Table 2: Different types of cases among study participants

Types of cases	N%
Ovarian/adnexal masses	30 (30)
Uterine masses	45 (45)
Fallopian tube pathologies	20 (20)
Vaginal pathologies	5 (5)

Out of 100 patients evaluated by ultrasonography 30 (30%) were having ovarian pathologies and 45 (45%) were having uterine pathologies. 20% patients presented with localized collection in to the fallopian tube pathologies. Few cases there were involvement 5 (5%) of vagina.

Table 3: Percentage wise distribution of pelvic masses and their histopathological diagnosis

Types of Lesion	USG Diagnosis	Histopathological Diagnosis
Uterine		
Fibroid	76	74
Fibroid with pregnancy	3	3
Adenomyosis	4	6
Adenocarcinoma of uterus	5	5
Carcinoma of cervix	4	4
Ovarian		
Benign		
Follicular cyst	10	10
Luteal cyst	4	4
Serous cystadenoma	4	4
Mucinous cystadenoma	4	4
Benign cyst teratoma	3	4

Hydrosalpinx	0	2
Ovarian cyst torsion	0	2
Tubo-ovarian masses	15	13
Malignant Lesion		
Serous cystadenocarcinoma	14	14
Mucinous cystadenocarcinoma	5	5
Endometrial sinus tumor	5	5

In our study, the most common female gynaecological masses were that of uterine, followed by ovary/adnexa, fallopian tubes and vagina. Fibroids were the most common uterine masses in our study. Thus, uterine fibroid is one of the most important and common cause of female gynaecological pelvic masses. Majority of ovarian lesions were benign cystic lesion 40 (40%) in which Tubo-ovarian masses 15 (15%) and follicular cyst were most common 10 (10%), followed by luteal cyst, serous cystadenoma, mucinous cystadenoma. In malignant ovarian masses serous cystadenocarcinoma most common followed by mucinous cystadenocarcinoma and endometrial sinus tumor.

Discussion

The evaluation of pelvic masses assumes importance due to the fear and anxiety driven by the potential of missing a malignancy. This study focused on the clinicopathological spectrum of gynecological pelvic masses - both uterine and adnexal. A major problem in diagnostic clarification of incidental findings on ultrasound is the characterization of the malignant potential of the lesions. Ovarian cancer, being a heterogeneous disease, is composed of different types of tumors derived from different cell lines with different behaviours and clinical-pathological characteristics [4]. Several scoring systems based on ultrasound morphology of adnexal cysts have been proposed to differentiate benign lesions from malignant adnexal masses [5-6].

These scoring systems are based on specific parameters such as surface, thickness of the wall, and cyst echogenicity, cyst volume, presence, thickness and number of septa, presence, size and number of vegetation, and presence and size of solid areas within the cyst. Fibroid was the most common overall uterine pathology in our study. Fibroid show distinct well-defined margin (Fig 1). A false diagnosis of fibroid in two cases was corrected as adenomyosis after postsurgical biopsy. Walsh *et al* described characteristics features of adenomyosis but these cases of our study only showed enlargement of uterus with loss of endo-myometrial junction and without any definite mass (Fig 2) [7]. The common sonographic findings of adenomyosis in our study were globular uterine enlargement, cystic anechoic spaces in the myometrium, uterine wall thickening, heterogeneous echotexture and thickening of the transition zone [8]. Adenomyoma usually has indistinct margin form adjacent myometrium unlike leiomyoma or fibroid which show distinct well-defined margin [9]. According to Bezjian *et al*. Leiomyoma are one of the most common pelvic masses countered during pregnancy [10].

Lesions with echogenic solid areas, irregular walls, thick septations, mural nodule, papillary excrescences, bilaterality and ascites along with evidence of neoangiogenesis on colour doppler are features suggestive of a possible malignancy [11]. Adenocarcinoma of uterus was diagnosed in 2 cases in our study (Fig 3), in which uterus was normal in size, it showed bulbar type of configuration of uterus with heterogenous pattern and endometrial echo was prominent.

Postsurgical histopathology confirmed the diagnosis as adenocarcinoma stage II. In the identification of the uterine pathology, 90.48% (38/42) of fibroid, 75% (3/4) of fibroids were diagnosed as adenomyosis correctly by ultrasonography after post-surgical histopathological examination. Accuracy of ultrasonography in the diagnosis of uterine and cervical malignancies was 100% in the presenting study.

All ovarian cystadenoma were anechoic with well-defined walls (Fig 4). Fleischer *et al*. [12] found septation in all of their 18 cases of serous cystadenomas. Mucinous cystadenoma may in addition contain low level echoes due to their mucin content (Fig 5). This finding was observed in our case. Similarly, Walsh, Taylor *et al*. [13] also found week internal echoes occasionally in cases of mucinous cystadenomas. Hence it suggests that a cystic ovarian mass with septation and internal echoes is more likely to be a mucinous cystadenoma. 11 cases of ovarian malignancy were reported on USG; however, 11 cases were confirmed to be malignant on HPE. In presenting study, all malignant ovarian tumors were showing cystic mass with ill-defined walls and solid component (Fig 6). All cases present with ascites. Out water EK *et al*. [14] suggested that irregular and solid component in a cystic mass suggested gross malignant change. None of the malignant ovarian tumor was purely cystic.

So, accuracy of diagnoses of malignant ovarian masses and tubo-ovarian masses were found to be 100% and 73.33% respectively, in presenting study. The low specificity of ultrasound is due to the overlap in the sonographic characteristics of benign pelvic masses like endometriomas, pedunculated leiomyomas, borderline tumours and ovarian malignancies. Serial monitoring was helpful in these cases, which shows resolution of the lesion on subsequent sonographic examination. Luteal cyst appeared as an anechoic mass with well-defined walls. In our study we were found

8 follicular and 4 luteal cysts were identified which was consistent with the findings of Fleischer *et al*. [12] Ovarian teratoma show solid cystic lesion with echogenic spherical floating balls with echogenic bands showing 'dot and dash' pattern and Rokitansky nodule which gives posterior acoustic shadowing (Fig 7). Our findings were consistent with study of Lawson *et al*. [15] Fleischer *et al*. [12] and Walsh *et al*. [18] reported accuracy of 91%, 91% and 94% respectively. In the present study, fibroids were the most common uterine masses in our study accounting for nearly 42%, i.e. Thus, uterine fibroid is one of the most important and common cause of female gynecological pelvic masses. USG, both transabdominal and transvaginal have a well-established role in the initial evaluation of a pelvic mass. USG has many advantages being easily available, relatively inexpensive and non-ionizing. Leiomyomas are easily diagnosed on USG. In study by Shobha S. Pillai. [16] 38 cases of leiomyomas were diagnosed preoperatively by physical examination and USG and 44 cases were

confirmed by histopathological examination (HPE), showing a sensitivity of 95.5% and specificity of 61.4%. Study by Eze JC *et al.* showed sensitivity of transvaginal scan (TVS) for diagnosis of uterine leiomyomas to be 94.5%, and specificity of 62.5%. [17] Accuracy of ultrasonography in the diagnosis of uterine and cervical malignancies was 100% in the presenting study. Due to the low likelihood of ovarian cancer in incidental findings of adnexal pelvic masses, and because of the high rates of spontaneous resolution, ultrasound monitoring can be performed with good early diagnosis rates for borderline and type I tumors. The frequency of these reevaluations

should be established individually and according to the routine of each service. However, early screening of type II tumors remains a challenge. Pelvic masses that are overlooked on physical examination will be identified by Ultrasonographic examination. Conversely the identification of small myomas, ovarian enlargement and physiological cysts may lead to increased patient concern and even operations that might be unnecessary. However, the drawbacks of sonography include technical limitation caused by patient habitues, operator dependence and techniques inability to provide specific characterization.

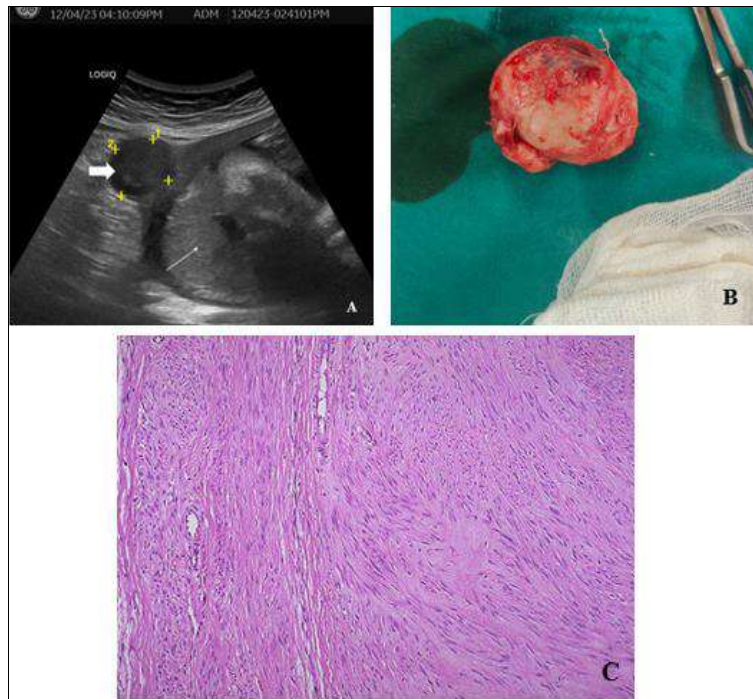


Fig 1: Fibroid with pregnancy

Longitudinal USG image (A) showing a well-defined subserosal homogenous iso to hypoechoic fibroid (box arrow) and placenta (line arrow) in a pregnant woman. Post-delivery myomectomy specimen (B). H and E stained 200x microscopy showing intersecting fascicles of monotonous spindle cells with eosinophilic cytoplasm and cigar shaped nuclei.

Transvaginal ultrasound image (A) showing globular enlargement of the uterus with Venetian blind artefacts. Post hysterectomy specimen showing globular enlargement of the uterus. H and E stained 200x microscopy showing endometrial glands and stroma deep in the myometrium.

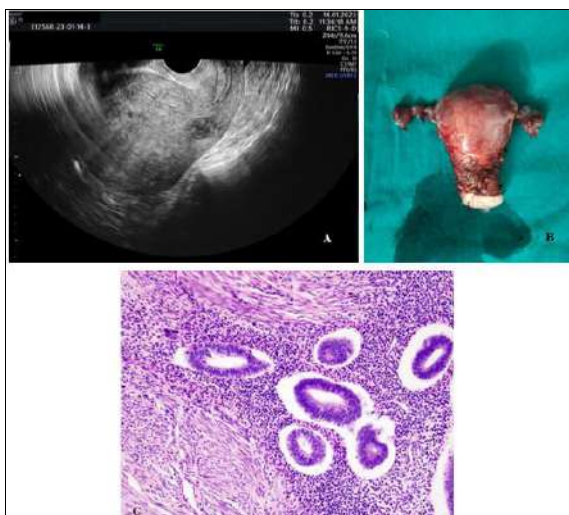


Fig 2: Adenomyosis

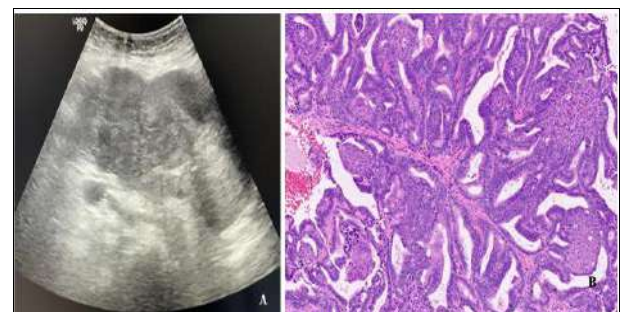


Fig 3: Uterine adenocarcinoma

Transverse USG image (A) showing ill-defined heterogenous mass arising from the posterior wall of uterus. H and E stained 200x microscopy showing confluent and back-to-back glands lacking intervening stroma with atypical cells.

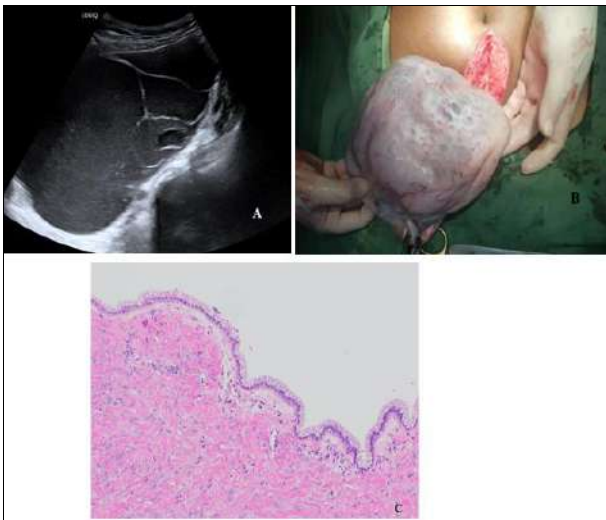

Fig 4: Ovarian mucinous cystadenoma

Longitudinal USG image (A) showing a large multilocular cystic lesion from left ovary with low level internal echoes and multiple septations. Post-operative cystectomy specimen (B). H and E stained 200x microscopy showing cyst wall lined by simple, non-stratified mucinous epithelium without atypia.

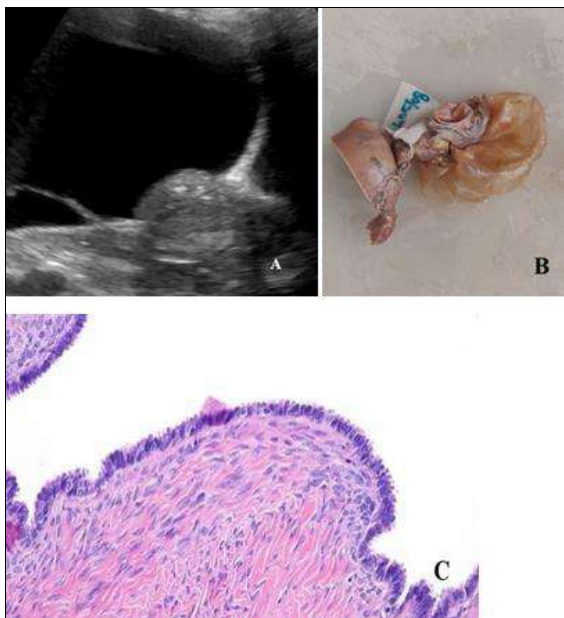


Fig 5: Ovarian serous cystadenoma

Longitudinal USG image (A) showing a large unilocular anechoic cystic lesion from right ovary. Post-operative cystectomy specimen (B). H and E stained 200x microscopy showing cyst wall lined by ciliated pseudostratified cuboidal epithelium without atypia and with fibrous stroma.

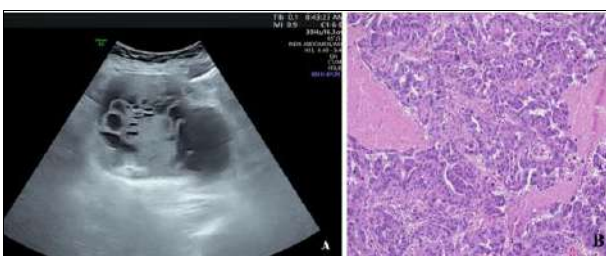

Fig 6: Serous cystadenocarcinoma

Transverse USG image (A) showing a large solid cystic lesion from right ovary. H and E stained 200x microscopy showing solid masses of columnar to cuboidal epithelium with significant nuclear atypia.

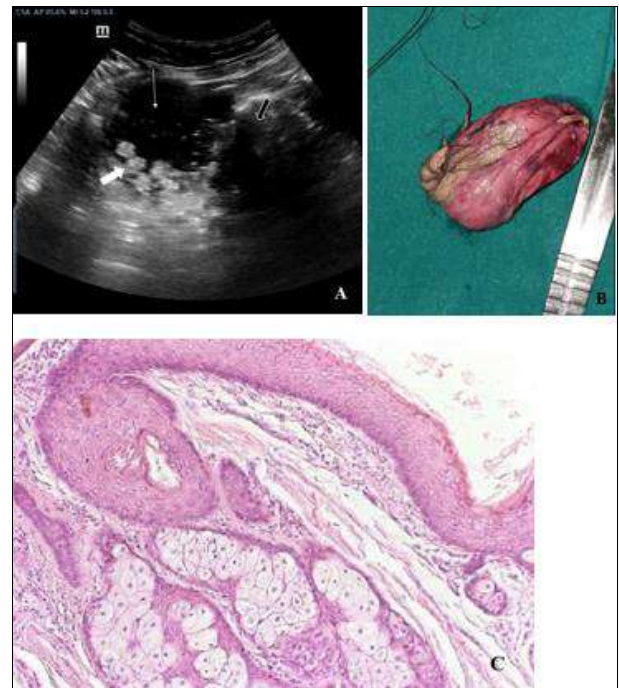

Fig 7: Ovarian teratoma

Transverse USG image (A) showing a well-defined solid cystic lesion with echogenic spherical floating balls (box white arrow), echogenic bands showing ‘dot and dash’ pattern (line arrow) with Rokitansky nodule (black box arrow) giving posterior acoustic shadowing. Post cystectomy specimen (B) showing cyst with hair as content. H and E stained 200x microscopy showing stratified squamous epithelium and adnexal structures.

Conclusion

The US is highly accessible, relatively inexpensive, does not use ionizing radiation, and is generally well tolerated by patients. Use of endovaginal US improves the diagnostic accuracy in the assessment of gynaecological masses by better resolution of the image. By studying the various features of histopathology specimen of particular gynaecological mass and correlating with imaging features of sonography we can classify, diagnose and evaluate various female gynaecological diseases presenting as mass lesion and increased the diagnostic accuracy of sonographic examination. Serial sonographic monitoring of the function lesions were helpful in the management and helps to avoid unnecessary surgical procedures. Hence sonography is real time, non-invasive, safe, easy, quick, devoid of any radiation hazard and high accuracy; it must be use as a first line modality for the evaluation of gynaecological pathologies.

Acknowledgements

We would like to acknowledge The Department of Obstetrics and Gynaecology and The Department of Pathology, JJM Medical College, Davangere for their valuable support. We would also like to extend our thanks to Dr. Neelam Solanki and Dr. Ashwini Suruthy for their

valuable support and encouragement. We are also grateful to all the patients and volunteers who were part of this study.

Author's Contribution

Not available

Conflict of Interest

Not available

Financial Support

Not available

References

1. Patel MD. Pitfalls in the sonographic evaluation of adnexal masses. *Ultrasound Quarterly*. 2012 Mar 1;28(1):29-40.
2. Smorgick N, Maymon R. Assessment of adnexal masses using ultrasound: A practical review. *International journal of women's health*. 2014 Sep 23;857-63.
3. Liu J, Xu Y, Wang J. Ultrasonography, computed tomography and magnetic resonance imaging for diagnosis of ovarian carcinoma. *European journal of radiology*. 2007 Jun 1;62(3):328-34.
4. Kurman RJ, Shih Ie M. The origin and pathogenesis of epithelial ovarian cancer: A proposed unifying theory. *Am J Surg Pathol*. 2010; 34(3):433-43.
5. Finkler NJ, Benacerraf B, Lavin PT, Wojciechowski C, Knapp RC. Comparison of serum CA 125, clinical impression, and ultrasound in the preoperative evaluation of ovarian masses. *Obstet Gynecol*. 1988;72(4):659-64.
6. Lerner JP, Timor-Tritsch IE, Federman A, Abramovich G. Transvaginal ultrasonographic characterization of ovarian masses with an improved, weighted scoring system. *Am J Obstet Gynecol*. 1994; 170(1-1):81-5.
7. Walsh JW, Taylor KJ, Wasson JF, Schwartz PE, Rosenfield AT. Gray-scale ultrasound in 204 proved gynecologic masses: accuracy and specific diagnostic criteria. *Radiology*. 1979 Feb;130(2):391-7.
8. Sakhel K, Abuhamad A. Sonography of adenomyosis. *Journal of Ultrasound in Medicine*. 2012 May;31(5):805-8.
9. Bergeron C, Amant F, Ferenczy A. Pathology and physiopathology of adenomyosis. *Best practice & research Clinical obstetrics & gynaecology*. 2006 Aug 1;20(4):511-21.
10. Bezjian AA, Carretero MM. Ultrasonic evaluation of pelvic masses in pregnancy. *Clinical Obstetrics and Gynecology*. 1977 Jun 1;20(2):325-38.
11. Kinkel K, Hricak H, Lu Y, Tsuda K, Filly RA. US characterization of ovarian masses: a meta-analysis. *Radiology*. 2000 Dec;217(3):803-11.
12. Fleischer AC. Differential diagnosis of pelvic masses by gray scale sonography. *Am. Jr. of Roentology*. 1978; 131:469-76.
13. Walsh JW, Taylor KJ, Wasson JF, Schwartz PE, Rosenfield AT. Gray-scale ultrasound in 204 proved gynecologic masses: accuracy and specific diagnostic criteria. *Radiology*. 1979 Feb;130(2):391-7.
14. Outwater EK, Siegelman ES, Hunt JL. Ovarian teratomas: tumor types and imaging characteristics. *Radiographics*. 2001 Mar;21(2):475-90.
15. Lawson TL. Ectopic pregnancy: criteria and accuracy

- of ultrasonic diagnosis. *American Journal of Roentgenology*. 1978 Jul 1;131(1):153-6.
16. Pillai SS. Clinicopathological spectrum of gynecological pelvic masses: A cross-sectional study. *Int J Reprod Contracept Obstet Gynecol*. 2017 May 1;6(5):1915.
17. Eze JC, Ugwu AC, Ohagwu CC. The value of ultrasonography in the diagnosis of leiomyomas in Southeast Nigeria. *J Asian Scient Res*. 2013;3(2):151-6.

How to Cite This Article

Solanki DK, Das T, Jeevika MU, Siddesh MB. Sonographic morphology of gynaecological pelvic masses and its correlation with the histopathological diagnosis. *International Journal of Radiology and Diagnostic Imaging* 2023; 6(2): 12-17.

Creative Commons (CC) License

This is an open access journal, and articles are distributed under the terms of the Creative Commons Attribution-NonCommercial-ShareAlike 4.0 International (CC BY-NC-SA 4.0) License, which allows others to remix, tweak, and build upon the work non-commercially, as long as appropriate credit is given and the new creations are licensed under the identical terms.