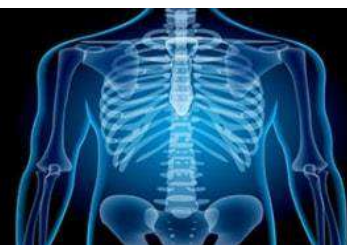

International Journal of Radiology and Diagnostic Imaging



E-ISSN: 2664-4444
P-ISSN: 2664-4436
IJRDI 2019; 2(2): 20-22
Received: 14-05-2019
Accepted: 18-06-2019

Sheeza Imtiaz
MBBS, FCPS, EDIR
Consultant Radiologist,
Department of Radiology,
Dr. Ziauddin University
Hospital Karachi, Pakistan

Kamran Hameed
MBBS, MCPS, FCPS
Assistant Professor,
Department of Radiology,
Dr. Ziauddin University
Hospital Karachi, Pakistan

Invasive micropapillary breast carcinoma in a young lactating woman: A rare entity

Sheeza Imtiaz and Kamran Hameed

DOI: <http://dx.doi.org/10.33545/26644436.2019.v2.i2a.34>

Abstract

Breast carcinoma is the most common malignancy in women with high mortality rates if diagnosed in advanced stages. Breast carcinoma is not uncommon in pregnant and lactating women but is usually diagnosed late due to physiological hormonal changes. Invasive micropapillary breast carcinoma is a rare variant. Here we describe a case of this rare entity in a young lactating woman.

Keywords: Breast carcinoma, micropapillary, lactating women

Introduction

Invasive micropapillary breast carcinoma is a clinically aggressive rare histological variant of invasive breast carcinoma. It was first described in breast by Fisher *et al.* in 1980^[1] where it was described as an exfoliative pattern. Later after 13 years the term invasive micropapillary carcinoma was proposed by Peterson^[2] and Siriaunkgul^[3]. It was included in World Health Organization classification of breast cancer in 2003. It accounts for about 0.7-3% of breast cancers. It is associated with poor clinical outcome with early lymphatic invasion and frequent recurrence. It usually occurs in old age during fifth and sixth decade of life. Here we present a case of invasive micropapillary breast carcinoma in a young lactating woman, which up to author's knowledge has not been reported before.

Case report

A 26 year old lactating mother came in our department for ultrasound breast examination with complain of pain and swelling of left breast since last six months. Initially, she ignored the swelling as she thought it was due engorgement of the breast secondary to lactation. But it increased with passage of time so then she consulted a physician who advised her to get ultrasound done.

Ultrasound of right breast was normal except for prominence of intramammary ducts compatible with lactational status. Left breast was grossly enlarged and edematous showing heterogenous hypoechoic breast parenchyma with interstitial edema and diffuse skin thickening of 7mm. No definite solid or cystic mass lesion was identified. Findings were likely suggestive of infective / inflammatory pathology and follow up after proper antibiotic treatment was suggested. Multiple enlarged axillary lymph nodes were also present bilaterally but on left side, lymph nodes were showing increased cortical thickness with displaced fatty hilum, largest one was measuring 2.1 x 1.5cm with a cortical thickness of 6mm. As the patient had positive family history for breast carcinoma, findings were suspicious and biopsy of the lymph node was suggested for histopathological confirmation. Biopsy of the lymph node was then done that confirmed invasive micropapillary breast carcinoma.

Patient went for 4 cycles of chemotherapy and then MRI breast was done for pre operative evaluation and to localize breast lesion. MRI showed enlarged left breast showing gross architectural distortion, edematous changes with diffuse skin retraction and thickening measuring 1.8cm. Multiple small lesions of varying sizes are seen in central breast parenchyma of left breast. These appear isointense on T1 weighted images [figure 1], faintly hyperintense on T2 weighted images [figure 2] and showed homogenous enhancement following contrast administration [figure 3]. Post contrast time signal intensity curve showed intense uptake and rapid wash out pattern that is type 3 graph representing malignant lesion

Corresponding Author:
Sheeza Imtiaz
MBBS, FCPS, EDIR
Consultant Radiologist,
Dr. Ziauddin University
Hospital Karachi, Pakistan

[Figure 4]. Findings were compatible with multicentric malignant neoplastic mass lesions. No abnormal enhancement was seen in chest wall and in pectoralis muscles to suggest chest wall invasion.

Discussion

Micropapillary breast cancers are distinct variant with pseudopapillary arrangement of tumor cells in an inside out growth pattern. Mostly invasive micropapillary cancers are of mixed type, pure IMPC is rare [4]. The most common clinical manifestation is a palpable mass [5].

To our knowledge many studies have done focusing on the pathological findings of this variant however only few studies have been done to elaborate the radiological features [6]. Mammographically, the most common presentation is an irregular, spiculated, high density mass [7]. It may also present with a circumscribed mass with or without calcification, focal asymmetry or gross architectural distortion. Microcalcification, skin thickening and nipple inversion has also been reported. Differentials for mammographic appearance may include invasive ductal carcinoma, medullary or colloid carcinoma, angiofibroma, benign cyst or hematoma.

Sonographically, it mostly presents with an irregular hypoechoic mass with spiculated margins [8]. Architectural distortion or focal parenchymal heterogeneity can also be seen. However, in our case, ultrasound was decisive as no definite mass lesion was detected instead there was diffuse interstitial edema and skin thickening with ectatic intramammary ducts mimicking an inflammatory / infective pathology.

Angiolymphatic invasion is an independent poor prognostic factor and a marker of lymph node metastasis in breast cancer. Zekioglu *et al.* [9] reported in 75% of the cases and Adrada *et al.* [7] reported in 55% of the cases. Ultrasound is most helpful in detecting lymph nodes that may demonstrate lymph node enlargement, cortical thickening and displaced or loss of central fatty hilum. These imaging findings are suspicious of lymphatic invasion and nodal metastasis. Sentinel lymph node trucut biopsy / Fine needle aspiration should be done to confirm lymphatic involvement. Our patient also presented with lymphatic invasion which was detected as a suspicious axillary lymph node on initial ultrasound examination and then was confirmed by trucut biopsy.

Only few studies have been previously conducted demonstrating the MRI features of IMPC. It mostly presents as an irregular spiculated mass lesion with early rapid enhancement and plateau or rapid washout pattern on dynamic contrast enhanced breast MRI. Kubota *et al.* [10] in his study demonstrated that all the patients with invasive micropapillary breast carcinoma showed an irregular mass with rapid initial washout kinetics on Breast MRI examination. Some patients may also show diffuse heterogenous non mass enhancement of whole breast parenchyma as demonstrated by Adrada *et al.* [7]

Hormone receptor status is one of the important prognostic factors for breast cancer and it has an important role in determining postoperative adjuvant therapy. Most of the patients of IMPC are ER and PR positive which generally is considered as a good prognostic factor and is associated with better tumor differentiation. Zekioglu *et al.* [9] reported the percentages of ER, PR, C-erbB-2 and p53 proteins positivity to be 68%, 61%, 54% and 48% respectively, for

IMPCs that are surprisingly higher than those observed for IDCs. But IMPCs seem to be an exception to this. Tumors with positive hormone receptors and negative HER2 tend to have more nodal metastasis as compared to their counterparts. CD24 has also been associated with increase nodal metastasis [11]. Our patient was positive for ER and PR and negative for HER2.

The prognosis of IMPC is worse than other invasive carcinomas of scirrhous types with a 5 year survival rate of 50.5% compared with 85.6% in scirrhous type [12]. According to Nassar *et al.* nodal status and skin involvement are the only parameters that predict poor prognosis in IMPC [13].

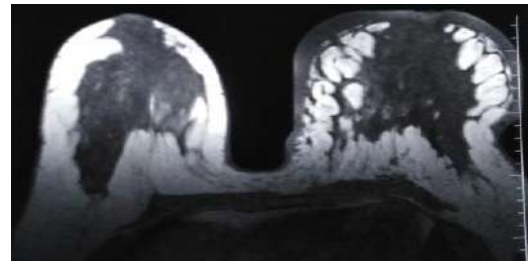


Fig 1: Axial section of T1W MRI breast showing enlarge left breast with diffuse edematous changes, skin thickening and ill defined hypointense lesions in centre of left breast

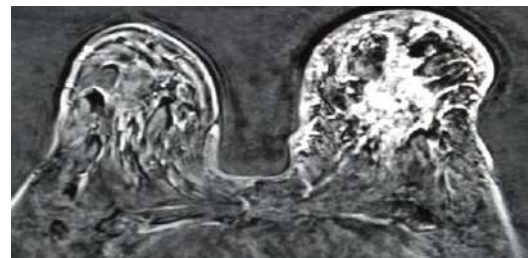


Fig 2: Axial section of T2W MRI breast showing ill defined hyperintense lesions in left breast parenchyma with diffuse edematous changes

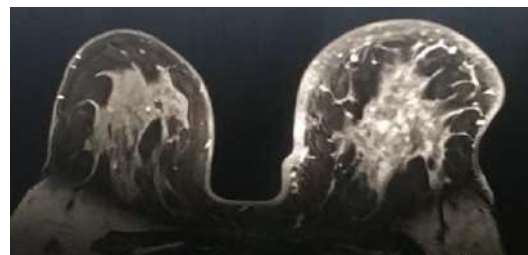

Fig 3: Axial section of T1W post contrast FAT SAT MRI breast showing multiple small enhancing lesions in central breast parenchyma of left breast with trabecular and overlying skin thickening

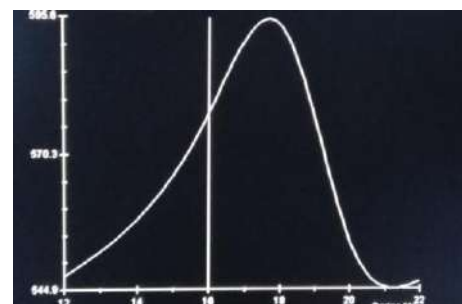


Fig 4: Time signal intensity curve showing rapid initial uptake and washout representing Type 3 curve suggesting malignant disease

Conclusion

Invasive ductal carcinoma with micropapillary features is a rare breast tumor with non specific clinical and radiological manifestations. It has a propensity for early lymphatic involvement with lymph node metastasis and loco-regional recurrence. The radiologist must be aware of the radiological manifestations of this rare tumor. Core needle biopsy of the breast lesion and sentinel lymph node biopsy should be done in these patients for early diagnosis.

Visscher D. Clinicopathologic analysis of invasive micropapillary differentiation in breast carcinoma. *Modpathol.* 2001; 14(9):836-41. DOI:10.1038/modpathol.3880399.

References

1. Fisher ER, Palekar AS, Redmond C, Barton B, Fisher B. Pathologic findings from the National Surgical Adjuvant Breast Project (protocol no. 4): VI, invasive papillary cancer. *Am J Clin Pathol.* 1980; 73(3):313-22
2. Petersen JL. Breast carcinomas with an unexpected inside-out growth pattern: rotation of polarization associated with angioinvasion. *Pathol Res Pract.* 1993; 189:A780
3. Siriaunkgul S, Tavassoli FA. Invasive micropapillary carcinoma of the breast. *Mod Pathol.* 1993; 6(6):660-62.
4. Shi WB *et al.* Clinico-Pathological Features and Prognosis of Invasive Micropapillary Carcinoma Compared to Invasive Ductal Carcinoma: A Population-Based Study from China. *Plos One.* 2014; 9:e101390. doi: 10.1371/journal.pone.0101390
5. Kim DS, Cho N, Ko ES, Kim DY, Yang SK, Kim SJ *et al.* Imaging and the clinical-pathologic features of invasive micropapillary carcinoma of the breast. *J Korean Radiol Soc.* 2007; 56:497-503.
6. Invasive micropapillary carcinoma of the breast: clinical, mammographic, and sonographic findings with histopathologic correlation. Günhan-Bilgen I, Zekioglu O, Ustün EE, Memis A, Erhan Y. *AJR Am J Roentgenol.* 2002; 179(4):927-31.
7. Adrada B, Arribas E, Gilcrease M, Yang WT. Invasive micropapillary carcinoma of the breast: mammographic, sonographic, and MRI features. *AJR* 2009; 193:272.
8. Günhan-Bilgen I, Zekioglu O, Ustün EE, Memis A, Erhan Y. Invasive micropapillary carcinoma of the breast: clinical, mammographic, and sono-graphic findings with histopathologic correlation. *AJR.* 2002; 179:927-931
9. Zekioglu O, Erhan Y, Ciris M, Bayramoglu H, Ozdemir N. Invasive micropapillary carcinoma of breast: high incidence of lymph node metastasis with extranodal extension and its immunohisto-chemical profile compared with invasive ductal carcinoma. *Histopathology.* 2004; 44:18-23.
10. Kubota K, Ogawa Y, Nishioka A *et al.* Radiological imaging features of invasive micropapillary carcinoma of breast and axillary lymph nodes. *Oncol Rep.* 2008; 20:1143-47.
11. Ide Y, Horii R, Osako T, Ogura K, Yoshida R, Iwase T *et al.* Clinicopathological significance of invasive micropapillary carcinoma component in invasive breast carcinoma. *Pathol Int.* 2011; 61:731-36.
12. Tsumagari K, Martin SG, Akiyama F, Kasumi F. The clinicopathological study of invasive micropapillary carcinoma of the breast. *Jpn J Breast Cancer.* 2001; 16:341-348.
13. Nassar H, Wallis T, Andea A, Dey J, Adsay V,