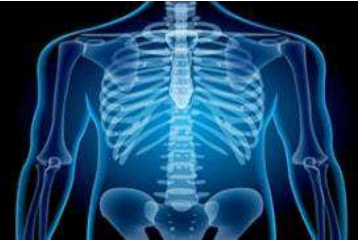

# International Journal of Radiology and Diagnostic Imaging



E-ISSN: 2664-4444  
P-ISSN: 2664-4436  
IJRDI 2018; 1(1): 10-12  
Received: 12-11-2017  
Accepted: 17-12-2017

**Dr. Vandna Devnath**  
Department of Radiology,  
R.G. Kar Medical College and  
Hospital, Kolkata, India

## Ultrasonography in the diagnosis of cases of Ascites

**Dr. Vandna Devnath**

**DOI:** <http://dx.doi.org/10.33545/26644436.2018.v1.i1a.4>

### Abstract

**Background:** Ascites, the collection of fluid in the peritoneal cavity, occurs with a variety of disease states. The present study was to assess cases of Ascites with USG.

**Materials & Methods:** This study was conducted on of 90 patients with Ascites. All underwent USG Scan with Aloka SSD-500 with frequency convex probe, and Honda SSD-500 with frequency (3.5 MHz) convex probe.

**Results:** Out of 90 patients, males were 50 and females were 60. Common causes were inflammatory (31), tumor (10), renal diseases (16), liver diseases (10), cardiac disease (8) and portal hypertension (15). The difference was significant (P- 0.01). Normal patients had total protein 8.1 g, total albumin 3.5 g and serum ascites albumin gradient was 0.2. Moderate had, 7.6 g, 2.7g and 0.8 respectively. The SAAG ratio was significant (P- 0.01).

**Conclusion:** Ultrasonography is a reliable aid in detection of Ascites. Common causes were inflammatory, tumor, renal diseases, liver diseases, cardiac disease and portal hypertension.

**Keywords:** Ascites, cirrhosis, ultrasonography

### Introduction

Ascites, the collection of fluid in the peritoneal cavity, occurs with a variety of disease states. It is one of the earliest and most common complication of chronic liver disease. In cirrhosis, it is associated with circulatory dysfunction characterized by arterial vasodilatation, high cardiac output and stimulation of vasoactive systems. Ascites turn out to be clinically evident when no less than 1500 ml of liquid needs to a mass as regularly around 50 ml of liquid is available in the peritoneal depression. As meager as 10 ml of free liquid can be recognized <sup>[1]</sup>. Chronic liver disease with portal hypertension, congestive cardiac failure, tuberculosis and malignancy are important causes of ascites. However, it can occur secondary to a number of pathological conditions <sup>[2]</sup>. In a large number of patients, cirrhosis of liver is the cause of ascites. Several factors contribute to the development of ascites in chronic liver disease. Kidney plays a central role and is responsible for sodium and water retention, through complex mechanisms. The mechanism by which the diseased liver affects renal function is not fully understood <sup>[3]</sup>.

As bedside US has become more widely used in the assessment of ascites, many clinicians have also routinely integrated US guidance into the paracentesis procedure. The anatomy of the liver and spleen can be further defined, so as to avoid these structures during the procedure <sup>[4]</sup>. The present study was to assess cases of ascites with USG.

### Discussion

#### Materials & Methods

This study was conducted in department of Radiodiagnosis. It comprised of 90 patients with ascites. Ethical approval was obtained prior to start of study. All were informed regarding the study and written consent was obtained.

Data such as name, age, gender etc. was recorded. All underwent USG Scan with Aloka SSD-500 with frequency convex probe, and Honda SSD-500 with frequency (3.5 MHz) convex probe. All scans were evaluated for the evaluation, hepatic recesses and around the peripheral hepatic borders, splenic recesses and around the peripheral splenic borders, right subphrenic space. During scanning the abdomen, the largest ascites pockets or pools were located, the ultrasound images in both transverse and longitudinal planes were taken. Results were subjected to statistical analysis. P value < 0.05 was considered significant.

### Correspondence

**Dr. Vandna Devnath**  
Department of Radiology,  
R.G. Kar Medical College and  
Hospital, Kolkata, India

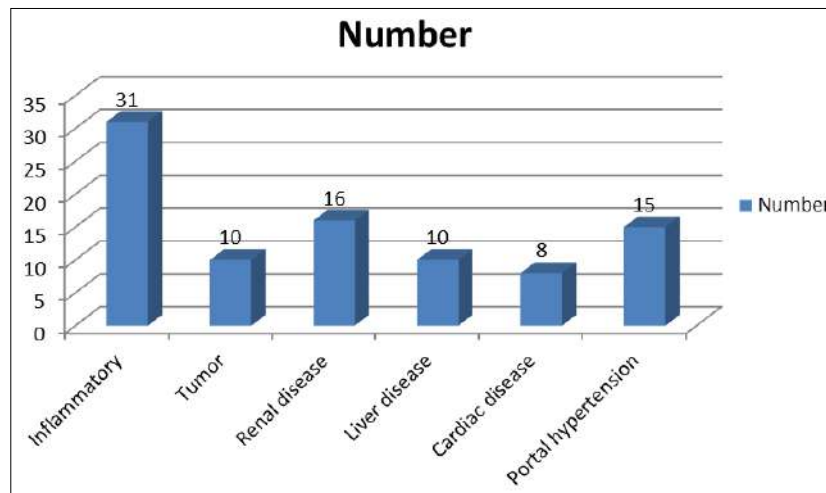
**Results**

**Table 1:** Distribution of patients

Total- 90		
Gender	Males	Females
Number	50	40

Table I shows that out of 90 patients, males were 50 and females were 60.

Graph I shows that common causes were inflammatory (31), tumor (10), renal diseases (16), liver diseases (10), cardiac disease (8) and portal hypertension (15). The difference was significant (P- 0.01).



**Graph 1:** Causes of Ascites

**Table 2:** Analysis of ascites fluid

Fluid	Total protein	Total albumin	SAAG
Normal	8.1	3.5	0.2
Mild	8.3	3.2	0.3
Moderate	7.6	2.7	0.8
Severe	6.7	2.6	1.2
Massive	6.8	2.3	1.8
P value	0.2	0.14	0.01

Table II shows that normal patients had total protein 8.1 g, total albumin 3.5 g and serum ascites albumin gradient was 0.2. Moderate had, 7.6 g, 2.7g and 0.8 respectively. The SAAG ratio was significant (P- 0.01).

**Discussion**

The reasons for ascites are liver cirrhosis, entry hyper strain, heart disappointment, hepatic venous impediment, pericarditis, malignancies, tuberculosis, pancreatitis, renal diseases and other diverse causes [5]. Ascites arrangement in malignancies of the belly and pelvis for the most part has been credited to expanded rates of development intra peritoneal liquid and diminished rates of evacuation [2]. Appraisal of the volume of ascites is fundamental in observing the advance of the infection and in choosing fitting strategies for treatment. Diagnosis of the cause is usually with blood tests, an ultrasound scan of the abdomen, and direct removal of the fluid by needle or paracentesis [6]. The present study was to assess cases of ascites with USG. In present study, out of 90 patients, males were 50 and females were 60. Common causes were inflammatory (31), tumor (10), renal diseases (16), liver diseases (10), cardiac disease (8) and portal hypertension (15). The difference was significant (P- 0.01).

Ultrasound investigation is often performed prior to attempts to remove fluid from the abdomen. This may reveal the size and shape of the abdominal organs, and Doppler studies may show the direction of flow in the portal vein, as well as detecting Budd-Chiari syndrome

(thrombosis of the hepatic vein) and portal vein thrombosis. Additionally, the sonographer can make an estimation of the amount of ascitic fluid, and difficult-to-drain ascites may be drained under ultrasound guidance [7].

Alnumeiri *et al.* [8] conducted a study in which a total of 53 patients with ascites were examined ultrasonographically using 3.5 MHz probe, during the period from 2012 up to 2013. The ascites volume, texture, total protein, total albumin, and Serum Ascites Albumin Gradient (SAAG) levels were evaluated and correlated with the underlying causes. The result of this study showed that the etiology of ascites was liver cirrhosis 23 (43.4%) followed by cancers 10 (18.9%), inflammations 8 (15.1%), renal diseases 7 (13.2%), heart diseases 3 (5.7%), portal hypertension 1.0 (0.53%) and urinary bladder Schistosomiasis 1.0 (0.53%). The ascites was detected in sub hepatic area in one patient, in the hepato renal in 9 patients, in the vesico ureteric in 16 patients and occupying the intra-peritoneal space with fully distention was found in 27 patients. Association between ascites characters, patient diagnostic etiology and paracentesis results were found to be significant.

We found that normal patients had total protein 8.1 g, total albumin 3.5 g and serum ascites albumin gradient was 0.2. Moderate had, 7.6 g, 2.7g and 0.8 respectively. The SAAG ratio was significant (P- 0.01). Abdominal paracentesis and a careful analysis of ascitic fluid is the single most important procedure and should be an early step in evaluating a patient with ascites. It should be performed in all patients with new onset ascites and whenever deterioration occurs in a patient with known ascites. Paracentesis can be performed easily and within minutes. The procedure has been found to be safe with about 1 percent risk of abdominal wall hematoma [9].

**Conclusion**

Ultrasonography is a reliable aid in detection of ascites common causes were inflammatory, tumor, renal diseases, liver diseases, cardiac disease and portal hypertension.

**References**

1. Goldberg BB. Ultrasonic evaluation of intraperitoneal fluid. *JAMA*. 2005; 235:2427-2430.
2. Forsby J, Henriksson L. Detectability of intraperitoneal fluid by ultrasonography. An experimental investigation. *Acta Radiol Diagn (Stockh)*. 1984; 25:375-378.
3. Moore KP, Wong F, Gines P, Bernardi M, Ochs A *et al*. The management of ascites in cirrhosis: report on the consensus conference of the International Ascites Club. *Hepatology*. 2003; 38:258-266.
4. Farahmand N, Sirlin CB, Brown MA, Shragg GP, Fortlage D *et al*. Hypotensive patients with blunt abdominal trauma: performance of screening US. *Radiology*. 2005; 235:436-443.
5. Bijoor AR, Venkatesh T. Value of Ascitic Fluid Cholesterol and Serum - Ascites Albumin Gradient In Differentiating Cirrhotic And Malignancy Related Ascites. *Indian Journal of Clinical Biochemistry*. 2001; 1:106-109.
6. Szkodziak PR, Wozniak S, Czuczwar P, Kludka-Sternik M, Paszkowski M *et al*. Ascites index – a new method of ultrasound evaluation of ascites volume in patients with ovarian cancer, *Ultrasound in Obstetrics & Gynecology*. 2000; 36:289.
7. Edell SL, Geftter WB. Ultrasonic differentiation of types of ascitic fluid. *AJR Am J Roentgenol*. 2001; 133:111-114.
8. Alnumeiri MS, Ayad CE, Ahmed BH, Abdalla EA. Evaluation of Ascites and its Etiology Using Ultrasonography. *J Res Development*. 2015; 3:119.
9. Khalife S, Falcone T, Hemmings R, Cohen D. Diagnostic accuracy of transvaginal ultrasound in detecting free pelvic fluid. *J Reprod Med*. 1999; 43:795-798.