

International Journal of Radiology and Diagnostic Imaging



E-ISSN: 2664-4444
P-ISSN: 2664-4436
IJRDI 2020; 3(1): 31-35
Received: 19-11-2019
Accepted: 21-12-2019

Dr. Sathunuri Veeraswamy
Professor and Head,
Department of Radiology,
MNR Medical College and
Hospital, Sangareddy,
Telangana, India

Dr. Chinta Vittal Prasad
Professor, Department of
Radiology, MNR Medical
College and Hospital,
Sangareddy, Telangana, India

**Dr. Venu Madhav
Muppavarapu**
Associate Professor,
Department of Radiology,
MNR Medical College and
Hospital, Sangareddy,
Telangana, India

Corresponding Author:
Dr. Chinta Vittal Prasad
Professor, Department of
Radiology, MNR Medical
College and Hospital,
Sangareddy, Telangana, India

Staging and diagnosis of carcinoma of the uterine cervix: A MR imaging study

Dr. Sathunuri Veeraswamy, Dr. Chinta Vittal Prasad and Dr. Venu Madhav Muppavarapu

DOI: <http://dx.doi.org/10.33545/26644436.2020.v3.i1a.55>

Abstract

The incidence of carcinoma cervix was 86-90% of all genital cancer of women in India. Estimation of disease extent and staging is crucial in the management of carcinoma cervix. Evaluation of disease staging by cytology, Sigmoidoscopy and pelvic examination provided insufficient information. Hence, MRI and CT has become accurate imaging modalities for clinical staging of carcinoma cervix. Among these, MRI is the accurate imaging modality in the assessment of disease staging and extent. This study was aimed to assess the efficacy of MR imaging in the diagnosis and staging of carcinoma cervix. A total 90 cases newly diagnosed and histo-pathologically confirmed with carcinoma of uterine cervix and treated with chemoradiotherapy were included. International Federation of Gynecology and Obstetrics (FIGO) staging was applied to MRI grading of the tumor. All the study participants were subjected to MRI pelvis performed with 1.5 tesla machine. Suspected masses were seen in 86.84% newly diagnosed cases and in 80.7% recurrent cases. The diagnostic accuracy, sensitivity, specificity, PPV and NPV in newly diagnosed cases was 89.82%, 90.20%, 18%, 93.14% and 95.45% respectively. Whereas in recurrent cases, diagnostic accuracy, sensitivity, specificity, PPV and NPV was 68.54%, 91%, 42%, 72.36% and 76% respectively. MR imaging is the better diagnostic modality than clinical examination in the tumor staging, extension of disease and assessment of treatment response in the carcinoma cervix.

Keywords: Magnetic resonance imaging (MRI), carcinoma cervix, FIGO staging, diagnostic accuracy

Introduction

Uterine cervical cancer is the third foremost cause of cancer related deaths and 2nd commonly diagnosed cancer among women in developing countries between age group 45-50 years. In India, around 72,000 deaths occur every year due to cervical cancers [1, 2]. Most common type of cervical cancers are squamous cell carcinoma and adenocarcinoma with incidence of 69% and 25% respectively [3, 4]. In carcinoma cervix cases within 2 years of post-treatment, disease recurrence was seen in 60-70% cases and recurrence within 5 years in 89-98% cases [5]. Disease management and prognosis depends on grade and histologic subtype of disease. International Federation of Gynecology and Obstetrics (FIGO) staging system is the most accepted and used staging system for carcinoma cervix. The revised FIGO staging suggests that MRI and CT are the better diagnostic imaging modalities for cervical cancer [6].

Studies suggest that MRI is the efficient diagnostic tool in cases with early stage invasive cervical tumors with 94% diagnostic accuracy. It is also the best imaging technique for preoperative assessment of myometrial invasion depth and cervical involvement [7]. National Comprehensive Cancer Network (NCCN) refers MRI only to assess in cases of type II endometrial cancer, whereas The American College of Radiology promotes MRI as the preferred imaging technique for treatment planning and staging of cervical cancers [8, 9]. With the reference of above literature, this study was designed to assess the efficacy of MR imaging in the diagnosis and staging of carcinoma cervix.

Materials and Methods

The present observational study was conducted in Department of Radiology, MNR Medical College and Hospital during April 2018 to September 2019. A total 90 cases newly diagnosed and histo-pathologically confirmed with carcinoma of uterine cervix and treated

with chemoradiotherapy were included. Cases confirmed with carcinoma cervix histo-pathologically, newly diagnosed cases, cases willing to participate, cases with adequate renal and haematological function and cases on post treatment follow up were included. Cases with contraindications to MRI, pregnant or lactating, with cardiovascular complications, psychiatric illness and not willing to participate in this study were excluded. Informed consent was obtained from all the cases and study protocol was approved by institutional ethics committee. Collected detailed history and cases undergone to clinical examination prior to the commencement treatment. International Federation of Gynecology and Obstetrics (FIGO) staging was applied to MRI grading of the tumor. All

the study participants were subjected to MRI pelvis performed with 1.5 tesla machine. Various MRI sequences have been used in multiple planes like T1W FSE axial and sagittal, T2W TSE axial and sagittal and TRUF1 coronal, STIR axial and FST1 WTSE axial, coronal and sagittal planes. The parameters like tumor size, extension, enhancement, invasion of rectal and urinary bladder wall, involvement of parametrial and pelvic wall and post treatment complication were noted. Clinical followup was done once in 3-6 months. The data was collected into Microsoft Office Excel 2010. The processes of exporting the coded data from excel to SPSS version 20.0 was employed.

Results

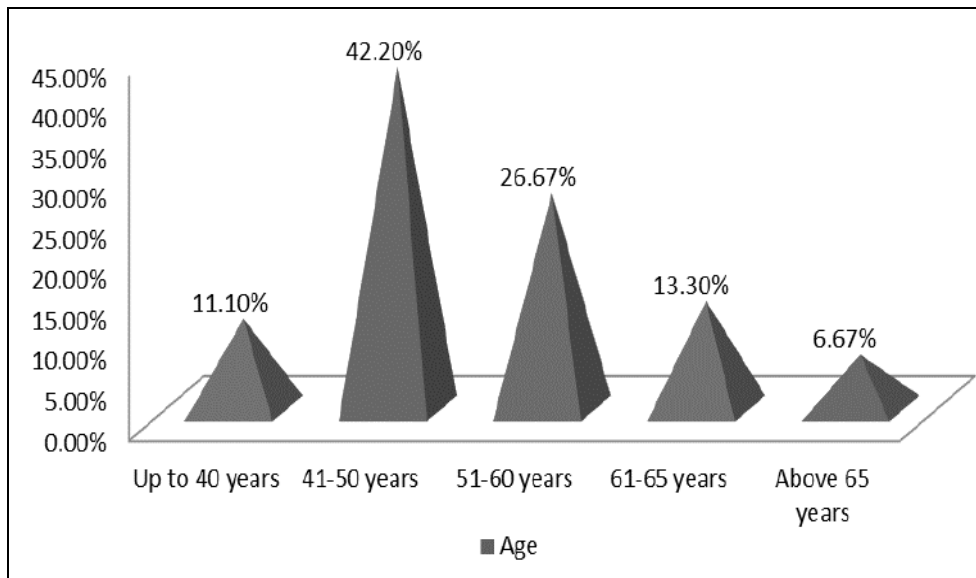


Fig 1: Age wise distribution of study participants

A total 90 cases histopathologically conformed to carcinoma cervix were recruited. Among the study cases majority cases were in between age group 41-50 (42.2%) followed by 51-

60 years (26.67%). Among the study participants, 38 cases (42.2%) were newly diagnosed and 52 cases (57.78%) had recurrent symptoms.

Table 1: Descriptive data of study participants

Parameter	Total cases	
	Number	Percentage
Associated symptoms		
Per vaginal bleeding	31	34.4%
Pain abdomen	59	65.5%
White discharge	38	42.2%
Menstrual status		
Pre-menopausal	32	35.5%
Post-menopausal	48	53.3%
Post hysterectomy	10	11.1%
Duration between radiation therapy and MRI (n=64)		
Up to 6 months	17	26.5%
6-12 months	14	21.8%
13-60 months	25	39.06%
More than 60 months	08	12.5%

Table 2: MRI findings in newly diagnosed cases (n=38).

Parameters	Newly diagnosed cases (n=38)		Recurrent cases (n=52)	
	Number	Percentage	Number	Percentage
HPE findings				
Squamous cell carcinoma	35	92.1%	48	92.3%
Adenocarcinoma	03	7.9%	04	7.6%
Presence of suspected masses				
Not present	05	13.15%	10	19.2%
Present	33	86.84%	42	80.7%
Correlation between MRI and clinical findings				
Correlated	36	94.7%	24	46.1%
Not correlated	02	5.3%	06	11.53%
Involvement of lymph nodes				
Inguinal group	01	2.6%	03	5.7%
Para aortic group	01	2.6%	01	1.9%
Iliac group	07	18.4%	08	15.3%
Obturator group	03	7.89%	03	5.7%
Parametrial group	04	10.52%	05	9.61%
Cystoscopy findings				
Normal	31	81.5%	-	-
Invasion of bladder	05	13.1%	-	-
Nor performed	02	5.26%	-	-
Sigmoidoscopy findings				
Normal findings	32	84.2%	-	-
Sigmoid diverticulitis	02	5.26%	-	-
Rectal invasion	01	2.6%	-	-
Growth rectum	01	2.6%	-	-
Not performed	02	5.26%	-	-

Table 3: Correlation between clinical and MRI FIGO staging

FIGO staging	Clinically diagnosed	MRI diagnosed
IA	03	NIL
IB	02	03
IIA	05	02
IIB	12	11
IIIA	01	NIL
IIIB	06	NIL
IVA	02	10
IVB	NIL	05

Table 3: Post-radiation therapy complication in the study participants

Symptoms	Total cases	
	Number	Percentage
Pelvic lipomatosis	05	5.5%
Pyosalpinx	04	4.4%
Vesico vaginal fistula	02	2.2%
Cystitis	15	16.67%
Bone marrow changes	21	23.3%
Proctitis	18	20%

Table 3: Efficacy of MRI sequences in newly diagnosed and recurrent cases

Findings	New diagnosis (n=38)	Recurrent (n=52)
T2W	92.1%	92.3%
DW1	97.3%	86.5%
Contrast	92.1%	84.6%
T2W+DWI	86.8%	84.6%
T2W+Contrast	81.5%	73.07%

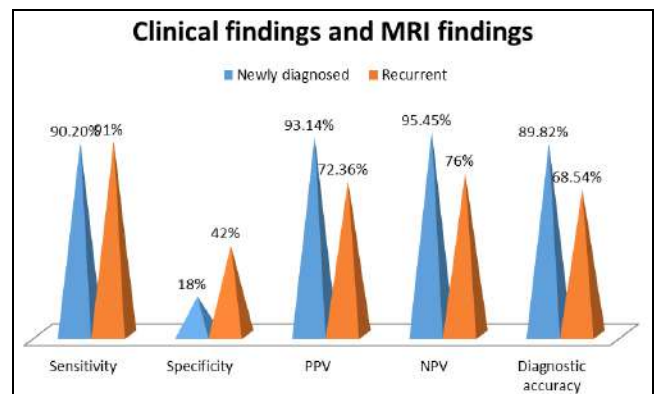


Fig 2: Comparison between clinical findings and MRI findings

Discussion

Carcinoma cervix accounting 9% of newly diagnosed malignancies and 3rd most common gynaecological malignancies in females around globally [10, 11]. Most common type of cervical carcinoma is Squamous cell carcinoma accounts approximately 69% followed by adenocarcinoma, accounting for approximately 25% [3, 4]. In carcinoma cervix cases within 2 years of post treatment, disease recurrence was seen in 60-70% cases and recurrence within 5 years in 89-98% cases [5]. The common sites of recurrence is vaginal vault, parametrium, cervix, pelvic wall and paraaortic lymphnodes [12, 13]. Factors indicating recurrence were size >3cm, LVSI, deep stromal invasion and type of adenocarcinoma [14]. International Federation of Gynecology and Obstetrics (FIGO) staging system is the most accepted and used staging system for carcinoma cervix which suggest investigations for staging carcinoma cervix like tissue biopsy, urine analysis, chest radiographs, cystoscopy, proctoscopy, dilatation and surettage and barium enema studies [15, 16]. This study was designed to assess the efficacy of MRI in the management of cases with

carcinoma cervix.

A total 90 cases, containing 42.2% newly diagnosed and 57.78% recurrent were included. Majority cases were in between age group 41-50 (42.2%) followed by 51-60 years (26.67%) (Figure 1). Study by Narender Reddy P *et al.*, observed incidence of carcinoma cervix was more in between age group 40-65 years with peak incidence between 45-50 years [17]. In majority cases, pain abdomen (65.5%) was commonly associated symptom followed by white discharge (42.2%) and per vaginal bleeding (34.4%). 53.3% cases are post menopausal, 35.5% cases were premenopausal and 11.1% cases underwent hysterectomy. The duration between radiation therapy and MR imaging was between 13-60 months in 39.06% cases, with in 6 months in 26.5% cases and 6-12 months in 21.8% cases (Table 1). Histopathological examination confirms that in newly diagnosed carcinoma cervix cases 92.1% cases had squamous cell carcinoma and 7.9% had adenocarcinoma. In recurrent cases, 92.3% had squamous cell carcinoma and 7.6% had adenocarcinoma (Table 2).

Suspected masses were seen in 86.84% newly diagnosed cases and in 80.7% recurrent cases. The diagnostic accuracy, sensitivity, specificity, PPV and NPV in newly diagnosed cases was 89.82%, 90.20%, 18%, 93.14% and 95.45% respectively. Whereas in recurrent cases, diagnostic accuracy, sensitivity, specificity, PPV and NPV was 68.54%, 91%, 42%, 72.36% and 76% respectively (Figure 2).

Study by Mangal Mahajan *et al.*, found that FIGO stage IA is not visible on MRI. Tumor of stage IB and higher only visible on MRI [18]. Usually stage 1 tumors limited to cervix. In this study, none of stage IA cases found on MRI. Stage 2 tumors are extends beyond the cervix upto upper two third of vagina is seen as segmental loss of the normally seen T2 hypointense vaginal wall and is termed as stage IIA. In stage IIB tumor normally seen hypointense peripheral stroma on T2W images and extends in the parametrium [19, 20]. Stage 3 tumors extends to the lower third of the vagina or lateral pelvic wall associated with hydronephrosis [21, 22]. Parametrial invasion up to the pelvic wall mentioned as stage IIIB. On MRI, stage IIIB is diagnosed as the distance between the tumor and the pelvic wall is <3mm or else partial or complete loss of hyposignal of pelvic wall musculature under T2W sequences. In this study none of cases were diagnosed as stage III tumors [23]. Stage 4 tumors extends to bladder or rectal mucosa. Presence of bladder and rectal invasion was normally seen in stage IVA, Whereas spread of tumor to the liver, spleen, pancreas, kidney, GI tract is referred as stage IVB [24]. Study by Narender Reddy P *et al.*, observed majority cases belong to stage IB (9 cases) followed by IVA (8 cases) [17].

In newly diagnosed cases, primary group of lymphnodes (Iliac, parametrial and obturator) was involved in 14 cases, inguinal nodes in 1 case and paraaortic nodes in 1 case. whereas in recurrent cases primary group of lymphnodes was involved in 15 cases, followed by inguinal nodes in 3 cases and paraaortic nodes in 1 case (Table 2). Lymphnode involvement plays a major role in the tumor diagnosis, staging, treatment and prognosis of cervical cancer [25-27]. In carcinoma cervix, lymphatic spread occurs usually along obturator, external iliac, internal iliac, common iliac, and paraaortic nodes [28].

In newly diagnosed cases, cystoscopy findings showed normal in 81.5% cases, invasion of bladder in 13.1% cases.

In 5.26% cases cystoscopy was not performed. The sigmoidoscopy showed normal findings in 84.2%, sigmoid diverticulitis in 5.26% case, rectal invasion in 2.6% cases and rectal growth in 2.6% cases. In 5.26% cases sigmoidoscopy procedure was conducted (Table 2). In this study, bone marrow changes, proctitis and cystitis are common post radiation therapy complications in 23.3%, 20% and 16.67% cases respectively.

Conclusion

MRI is the useful tool in the staging of disease, tumor spreading to local and distant lymph nodes. The results of this study shown that MR imaging is the better diagnostic modality than clinical examination in the tumor staging, extension of disease and assessment of treatment response in the carcinoma cervix. Studies suggest that MRI-aided radiotherapy planning may reduce the possibility of geographic errors when compared to conventional radiotherapy planning.

Reference

1. Aravindh SA, Mintu MA, Vipin GK. MRI versus clinical assessment in staging and response evaluation in locally advanced cervix cancer patients treated with concurrent chemo-radiation in a tertiary cancer center: a prospective study. *Int J Reprod Contracept Obstet Gynecol.* 2017; 6:392-9.
2. Kaur H, Silverman PM, Iyer RB, Verschraegen CF, Eifel PJ, Charnsangavej C. Diagnosis, staging and surveillance of cervical carcinoma. *Am J Roentgenol.* 2003; 180:1621-32.
3. World Health Organization. Latest world cancer statistics. Available at: https://www.iarc.fr/wp-content/uploads/2018/07/pr223_E.pdf. Accessed 23 Dec 2018.
4. Kurman RJ, Cargangu ML, Herrington S, Young RH. World Health Organization classification of tumours of female reproductive organs. IARC Press. Lyon, 2014.
5. Maria Milagros Otero-Garcia, Alicia Mesa-Alvarez, Olivera Nikolic, Patricia Blanco-Lobato, Marijana Basta-Nikolic, Rafael Menendez de Llano-Ortega, Laura Paredes-Velazquez, Nikola Nikolic and Magda Szewczyk-Bieda. Role of MRI in staging and follow-up of endometrial and cervical cancer: pitfalls and mimickers. Otero-García *et al.* *Insights into Imaging.* 2019; 10(19):1-22.
6. Narayan K, McKenzie AF, Hicks RJ, Fisher R, Bernshaw D, Bau S. Relation between FIGO stage, primary tumor volume, and presence of lymph node metastases in cervical cancer patients referred for radiotherapy. *Int J Gynecol Cancer.* 2003; 13:657-63.
7. Rizzo S, Calareso G, Maccagnoni S, Angileri SA, Landoni F, Raimondi S *et al.* Pre-operative MR evaluation of features that indicate the need of adjuvant therapies in early stage cervical cancer patients. A single-centre experience. *Euro J of Radiology.* 2014; 83(5):858-64
8. Lalwani N, Dubinsky T, Javitt MC *et al.* ACR appropriateness criteria (R) pretreatment evaluation and follow-up of endometrial cancer. *Ultrasound Q.* 2014; 30(1):21-28
9. Koh WJ, Abu-Rustum N, Bean S *et al.* NCCN Clinical Practice Guidelines in Oncology (NCCN Guidelines®). Cervical Cancer Version 1. 2018. Available at:

- https://oncolife.com.ua/doc/nccn/Cervical_Cancer.pdf.
10. Jemal A, Bray F, Center MM, Ferlay J, Ward E, Forman D. Global cancer statistics. *CA Cancer J Clin*. 2011; 61(2):69-90.
 11. World Cancer Research Fund International. 2012 September 22nd, 2015]. Available from: <http://www.wcrf.org/int/cancer-facts-figures/worldwide-data>.
 12. Babar S, Rockall A, Goode A, Shepherd J, Reznik R. Magnetic resonance imaging appearances of recurrent cervical carcinoma. *Int J Gynecol Cancer*. 2007; 17(3):637-645.
 13. Bhatla N, Aoki D, Sharma DN, Sankaranarayanan R. Cancer of the cervix uteri. FIGO Cancer report. *Int J Gynaecol Obstet*. 2018; 143(2):22-36.
 14. Patel-Lippmann K, Robbins J, Barroilhet L, Anderson B, Sadowski E, Boyum J. MR imaging of cervical cancer. *Magn Reson Imaging Clin N Am*. 2017. <https://doi.org/10.1016/j.mric.2017.03.007>.
 15. McCarthy S, Hricak H. The uterus and vagina. In: Higgins CB, Hricak H, Helms CA, eds. *Magnetic resonance imaging of the body*. 3rd ed. New York, NY: Lippincott-Raven, 1997, 761-814.
 16. Togashi K, Morikawa K, Kataoka ML, Konishi J. Cervical cancer. *J Magn Reson Imaging*. 1998; 8:391-397.
 17. Narender Reddy Peddareddy, Santhosh Babu Rendla, Sumalatha Kasturi and Narender Gajula. MR Imaging of Carcinoma Cervix. *Int. J Curr. Microbiol. App. Sci*. 2016; 5(7):619-626.
 18. Mangal Mahajan, Rajesh Kuber, Chaudhari KR, Prashant Chaudhari, Pravin Ghadage, Rushikesh Naik. MR imaging of carcinoma cervix. *Indian J Radiol Imaging*. 2013; 23(3):247-252.
 19. Nicolate V, Carignan L, Bourdon F, Prosmann O. MR imaging of cervical carcinoma: A practical staging approach. *Radio Graphics*. 2000; 20:1539-49.
 20. Okamoto Y, Tanaka YO, Nishida M, Tsunoda H, Yoshikawa H, Itai Y. MR Imaging of the uterine cervix: Imaging-pathologic correlation. *Radio Graphics*. 2003; 23:425-45.
 21. Follen M, Levenback CF, Iyer RB, Grigsby PW, Boss EA, Delpassand ES *et al*. Imaging in cervical cancer. *Cancer Suppl Suppl*. 2003; 98:2028-38.
 22. Pannu HK, Corl FM, Fishman EK. CT evaluation of cervical cancer: Spectrum of disease. *Radio Graphics*. 2001; 21:1155-68.
 23. Pannu HK, Corl FM, Fishman EK. CT evaluation of cervical cancer: spectrum of disease. *Radio-Graphics* 2001; 21:1155-1168.
 24. Feong YY, Kang HK, Chung TW, Seo FF, Park FG. Uterine cervical carcinoma after therapy: CT and MRI imaging findings. *Radio Graphics*. 2003; 23:969-81.
 25. Colombo N, Creutzberg C, Amant F *et al*. ESMO-ESGO-ESTRO consensus conference on endometrial cancer: diagnosis, treatment and follow-up. *Radiation Oncol*. 2015; 117(3):559-581.
 26. Nougaret S, Horta M, Sala E *et al*. Endometrial cancer MRI staging: update guidelines of the European Society of Urogenital Radiology. *Eur Radiol*. 2019; 29:792 <https://doi.org/10.1007/s00330-018-5515-y>.
 27. Patel-Lippmann K, Robbins J, Barroilhet L, Anderson B, Sadowski E, Boyum J. MR imaging of cervical cancer. *Magn Reson Imaging Clin N Am*, 2017. <https://doi.org/10.1016/j.mric.2017.03.007>.
 28. Bhatla N, Aoki D, Sharma DN, Sankaranarayanan R. Cancer of the cervix uteri. FIGO Cancer report 2018. *Int J Gynaecol Obstet*. 2018; 143(2):22-36.