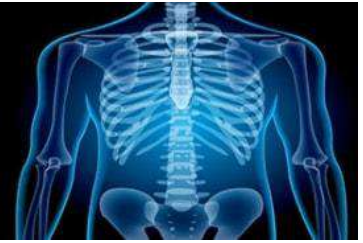

International Journal of Radiology and Diagnostic Imaging



E-ISSN: 2664-4444
P-ISSN: 2664-4436
IJRDI 2020; 3(1): 44-48
Received: 25-11-2019
Accepted: 28-12-2019

Dr. Shantaling Nigudgi
Medical Superintendent,
Consultant Clinical / Radiation
Oncologist, HCG Cancer
Center Kalaburagi,
Karnataka, India

Dr. Donald Fernandes
Proff Unit Chief, Shirdi Sai
Cancer Hospital, Kasturba
Medical College Manipal,
Karnataka, India

Evaluation of therapeutic effect of low-level helium neon laser therapy in the management of concurrent chemoradiotherapy induced mucositis in Oral And ORO-Pharyngeal cancer patients

Dr. Shantaling Nigudgi and Dr. Donald Fernandes

DOI: <http://dx.doi.org/10.33545/26644436.2020.v3.i1a.57>

Abstract

Background and Objective: Every patient receiving radiotherapy experience increasing inflammation of the irradiated mucosa with the progress of treatment. This is especially true in curative treatment regimens. Hence the present study was undertaken with the objective to evaluate the therapeutic effect of low-level helium neon laser therapy in the management of concurrent chemoradiotherapy induced mucositis in Oral and Oro-pharyngeal cancer patients.

Methodology: This prospective, single centered, triple blinded, randomized control trial was carried out from March 2009 till August 2010. 163 Head and Neck Cancer patients were screened of which 109 met the ideal inclusion and exclusion criteria. Blinding was done at three levels i.e. patients, assessor and data analysing statistician. The patients were block randomized into laser (54) and placebo (55) groups using a computer-generated program. Patients' age and site of the primary tumour were matched in each block. All the patients completed the trial, 50 in each group.

Results: The oral mucositis scores were significantly lower in the patients receiving LLLT compared to the placebo group. There was a delay in development of mucositis in the laser group where all were treated with scanning laser. The incidence of grade III and IV mucositis was nearly 50% less in the study arm. At the end of 2nd week, 66% in the laser arm had no mucositis, in contrast to only 42% in the placebo arm. By the end of the 3rd week, 22% of the laser treatment patients were free of mucositis, while 8% were free of mucositis in placebo group. There is divergence of the two arms second week onwards, that is pronounced beyond the 5 weeks. The oral mucositis scores were consistently lower over the course of treatment in the laser arm, and the difference was statistically significant ($p < 0.001$).

Conclusion: The Laser group showed a significant delay in the development of oral mucositis as compared to the Placebo group.

Keywords: Oral mucositis, chemotherapy, laser therapy, therapeutic management, oral and oropharyngeal cancer

Introduction

Patients with locally advanced head and neck cancer (HNC) are frequently treated with concurrent chemoradiotherapy (CCRT) [1]. The rationale for CCRT is that chemotherapeutic agents may act as radiation sensitizers in addition to contributing their own anti-tumor effect [2]. Also, effective chemotherapy may control micro-metastasis outside of the lesions treated with radiotherapy. Growing evidence indicates that more aggressive regimens showed an improvement in overall survival, disease-free survival, loco-regional control of the disease, or a decrease in distant metastasis with CCRT compared to radiotherapy alone [2].

Better treatment outcomes, however, have come at the expense of increased patient morbidity, notably an increase in severe (grades 3–4) mucositis that causes substantial pain, interferes with the patient's ability to chew, swallow and talk, and worsens the patient's quality of life [3]. Oral mucositis significantly impairs quality of life in all spheres, including physical, emotional, functional, and social domains.⁴ Management of mucositis may require feeding tube placement, hospitalization, and intensive supportive care [5].

Low-level laser therapy (LLLT) has been studied as a modality in preventing and alleviating the mucositis in head and neck radiotherapy. Since the 1970s, LLLT was studied as a pain-relieving agent in medicine. Laser was primarily shown to be useful in acute pain in Rheumatoid arthritis, osteoarthritis and other orthopedics ailments. Increased healing

Corresponding Author:
Dr. Shantaling Nigudgi
Medical Superintendent,
Consultant Clinical / Radiation
Oncologist, HCG Cancer
Center Kalaburagi,
Karnataka, India

capacity was also observed in the exposed skin in animal models [6].

A few preclinical, phase II and phase III trials have shown the beneficial results of low-level laser therapy (LLLT) in preventing and decreasing the severity of mucositis and consequently its associated pain in patients receiving chemotherapy/ RT/ Whole body irradiation for Hematopoietic stem cell Transplant (HSCT) [7-13, 14, 15]. Possible mechanism of the healing effects seems to be related to an influence of LLLT on the mitochondria, fibroblasts, and immunological processes [36-38]. Also pain relief potential of LLLT by modification of nerve conduction via the release of endorphins and enkephalins [7-13-15].

Based on this background the present study was undertaken with the objective to evaluate the therapeutic effect of low-level helium neon laser therapy in the management of concurrent chemoradiotherapy induced mucositis in Oral and Oro-pharyngeal cancer patients.

Methodology

Study Design: This was a prospective, single centered, triple blinded, randomized control trial carried out from March 2009 till August 2010. 163 Head and Neck Cancer patients were screened for inclusion and exclusion criteria, and out of them 109 met the ideal inclusion and exclusion criteria. Out of these, 9 were excluded from the final analysis of which 2 patients due to death unrelated to treatment toxicity, 4 patients discharging against medical advice and 3 patients having a change in treatment plan. Blinding was done at three levels i.e. patients, assessor and data analysing statistician. The patients were block randomized into laser (54) and placebo (55) groups using a computer-generated program. Patients' age and site of the primary tumour were matched in each block. All the patients completed the trial, 50 in each group. (Figure No.1) Ethical approval was obtained from Hospital Ethical Committee before commencing the trial and written informed consent was obtained from all patients for participating in the trial. Newly diagnosed patients with primary Oral cavity and Oro-pharyngeal cancers were enrolled in the study.

The inclusion criteria were patients aged 18 years and above who gave consent, with Eastern Cooperative Oncology Group (ECOG) performance Score ≤ 2 and Scheduled to undergo curative concurrent chemoradiotherapy for primary oral cavity and Oro-pharyngeal cancers.

Exclusion criteria included Trismus (due to possible difficulty administering the laser beam), ECOG performance Score > 2 , Medically un-fit, or unwilling for chemotherapy. Medically compromised conditions which could impair wound healing (e.g. diabetes). Presence of distant metastasis. Prior radiation or neo-adjuvant chemotherapy for head and neck cancers. Patients not receiving high dose (>50 Gy) radiation to the oral cavity.

Treatments

Study Intervention Regimens: Every patient was assigned to Active laser group of Placebo Group randomly. Both groups received same standard oral care and oral hygiene protocol. Dental consultation was sought, and necessary oral treatment administered prior to the start of radiation. The oral hygiene measures included frequent mouth washes with Sodium Bicarbonate. Bland, soft diet was prescribed for all

patients. Whenever a patient was found to develop Oro-pharyngeal candidiasis, topical and/or systemic antifungal measures were promptly started. The placebo group received sham treatment (i.e. simple red light) while Laser group patients received LLLT.

Concurrent Chemoradiotherapy Regimen: All patients received concurrent chemotherapy. The patients were either treated with three weekly or weekly chemotherapy schedule. Single agent platinum, either cisplatin or Carboplatin, was used in all patients as the chemotherapeutic agent. Cisplatin was used at the dose of 100 mg/m² administered 3 weekly (Day 1, 22, 43), or at 40 mg/m², administered weekly (Days 1, 8, 15, 22, 29 and 36). Carboplatin was used only in patients who had a creatinine clearance < 60 ml/min. the dosage of Carboplatin was AUC 6 administered 3 weekly, or AUC 2.5 administered weekly. Radiation dosage of 66 Gy was given in 33 fractions, 5 days a week over 45 days. Patients with residual disease were eligible for higher doses of boost radiation, however no patient received more than 72 Gy. All patients were treated on a 6 MV linear accelerator using

3D-Conformal Radiotherapy. The portals were designed to treat the primary tumor, involved lymph nodes, and the relevant areas of lymphatic drainage. Parallel-opposed radiation fields, with a matching lower neck field, were the technique used in all cases. After 40 Gy, Field Size Reduction (FSR) was done to limit the dose to the spinal cord. Matching posterior electrons were added for patients who required further treatment to the posterior cervical region.

LLLT Dose Standardization: We standardized the LLLT doses depending on the tissue response for LLLT at the initial phase of the study. Initial 8 days an energy density of 1.8 Jcm⁻² was delivered which might have acted as a basement cell membrane stabilizer for oral mucosa. Once grade 1 mucositis was evident, an energy density of 1.8-3 Jcm⁻² was delivered which was expected to act as both basement cells membrane stabilizer and as a pain gate mechanism. Once grade 2-4 mucositis was evident an energy density of 1.8-3 Jcm⁻² was delivered at the periphery of the lesions and a dose of 4 to 5 Jcm⁻² was delivered at the center of the lesion which might have acted as an antimicrobial agent.

Low level Laser Therapy Protocol: A single operator who was experienced in the delivery of LLLT field treated all the patients. Patients in Laser group were treated with Low Level Helium-Neon Laser ($\lambda = 655$ nm, power output = 24mW) at 6 anatomical sites in the oral cavity (namely buccal mucosa, lateral and ventral tongue, labial mucosa, floor of the mouth, and palate excluding cancer site) prior to Radiotherapy for 45 days. Prior to the development of any mucositis, patients were treated with laser scanner; a frequency of 10 Hz for 5 minutes. After the development of mucositis, the patients received laser treatment to the affected sites with a non-contact fiber-optic hand piece (placed in immediate proximity). During the laser or the placebo treatment, the patient and the therapist wore wavelength specific protective eye goggles. The treatment time (t) for each application point was calculated by the equation $t \text{ (sec)} = \text{energy (J/cm}^2\text{)} \times \text{surface area (cm}^2\text{)} / \text{Power (W)}$, a constant spot of 1cm² (1.5cm diameter) was

irradiated for varying length of time to achieve the desired dose of 1.8-5 J/cm² [using formula $D = p \times t / A$], which was standardized at the initial phase of the study in our institution.

Evaluation (Outcome Measures)

An experienced radiation oncologist who was unaware for the trial intervention group did the clinical assessment of all the patients. The evaluation was done during the course of the treatment, on a daily basis, and the highest recorded value in that week was taken as the weekly measure. Following outcomes were assessed Severity of Mucositis was assessed using the Radiation Therapy Oncology Group/ European Organization for Research & Treatment of Cancer (RTOG/ EORTC) scoring system. Objective assessment of the Oral the Mucositis.

Statistical analysis

Statistical analysis was done using SPSS. version 18.0. Descriptive statistics was calculated for age and independent sample t-test was used to compare the corresponding subgroups of laser and control group. Chi-square test is used to determine if there is any association between categorical variables from two or more groups. P value less than/equal to 0.05 was considered significant for each of the above-mentioned analysis.

Results

100 patients completed the trial from March 2009 till August 2010. 50 were allocated to each group randomly. Most of the patients included into the study were 40 years or older. Mean age of patients was found to be 56.90 ± 11.97 years and 55.18 ± 10.94 years in laser and placebo group respectively. Majority of the patients were males (80 %); females constituted only 20% of all the patients. 9 patients (18%) in the laser arm were females, compared to 11 (22%) females in the placebo group. (Table No.1)

Similar numbers of patients in both the arms had oral malignancy (54% in the Laser arm vs. 56% in the placebo arm) and Oro-pharyngeal malignancy (46% in the laser arm vs. 44% in the placebo arm). Stage IV disease was more frequent in the placebo arm. Stage IV b was seen in 24% of the patients in the study arm and 34% in the placebo arm. No patient with stage I disease was included into the study. Test of repeated measures was used for the comparison of the oral mucositis grades between the two arms.

Table no.2 shows the weekly progress of oral mucositis. There was a significant delay in development of mucositis in the treatment arm when compared with the placebo arm. At the end of 2nd week, 66% in the laser arm had no mucositis, in contrast to only 42% in the placebo arm. By the end of the 3rd week, 22% of the laser treatment patients were free of mucositis, while 8% were free of mucositis in placebo group. There is divergence of the two arms second week onwards, that is pronounced beyond the 5 weeks. The oral mucositis scores were consistently lower over the course of treatment in the laser arm, and the difference was statistically significant ($p < 0.001$). (Table No.3)

Stage of disease and outcomes

The patients in the two arms were compared based on the stage of their disease on all the parameters. The results are tabulated stage wise below.

Stage II disease: Oral mucositis grades were similar in patients in both groups with stage II disease, and no statistical significance was noted.

Stage III disease: As seen in subgroups with stage II disease, there was no difference in the outcomes in the laser and the placebo arms.

Stage IV disease: The outcomes were significantly different between the two arms among Patients with stage IV disease, favoring the laser arm. the mucositis grades were significantly less in the laser group ($p < 0.001$)

Discussion

Oral mucositis is the most troublesome acute side effect in patients undergoing RT/CRT for Head and neck cancers [3]. It causes pain, which adversely affects the patient's swallowing and normal oral functioning. This in turn leads to diminution of oral intake and hence loss of weight. The progression of oral lesions and their impact on the patient's general condition may require tube feeding or unplanned treatment breaks or modification of the RT plan [3]. To date, no agent exists that is capable of curing or preventing mucositis. The use of low-level lasers had been suggested in a few studies to be useful in treating mucositis. The present study was done to evaluate the efficacy of prophylactic LLLT in the prevention and treatment of concurrent chemo-radiotherapy induced oral mucositis in Oral cavity cancers patients.

Both the study and the placebo arms were comparable in most of the demographic aspects. Though age and sex matching were done, there was no statistically significant difference in subgroups on comparison, which could have otherwise confounded the results. The mean age of the patients in our study was 56.90 years in laser group and 55.18 years in control group. There was about 17% female in laser group and 22% in control group. The great proportion of males in oral cancer could be a direct consequence of sex distribution of tobacco habits. The patients taken for the study were put on the same type of oral mouth-care regimes during the trial, mainly constituting frequent sodium bicarbonate mouth washes, to avoid any bias. Systemic antifungals were used in addition to topical antifungals when the patient was found to have oral candidiasis. All the patients were given similar doses of radiation and chemotherapeutic drugs.

In this study not only was oral mucositis in the two groups assessed, but also severity of pain and swallowing difficulties were compared between the laser and control groups.

The principle behind using lasers is that it is known to accelerate wound healing and, has anti-inflammatory action. Wound healing is one of the most studied aspects of low energy lasers. In studies of fibroblast responses to laser, increased cell division or increased collagen production have been reported in gingival tissues, He-Ne laser applications have stimulated DNA synthesis of myofibroblasts without any degenerative changes, and have transformed fibroblasts into myofibroblasts, which may promote wound healing [16]. With regard to pain relief, one proposed mechanism is modulation of nociception by modification of nerve conduction via the release of endorphins and enkephalins.

Curative laser application seems less successful than prophylactic laser application though the reason is not entirely clear. Ciais *et al.* reported in a retrospective study an increased frequency of mucositis among the 21 patients treated with curative intents (82%) when compared with a non-treated group of 21 patients (43%). In the same report, the group of 25 patients who received prophylactic applications experienced a seven-fold decrease in occurrence of mucositis when compared to patients treated before only with curative intent.

Therefore, in the present study patients were given laser treatment with the prophylactic intent initially i.e. before they developed any mucositis. Laser scanner was used to treat the entire oral cavity daily for the treatment group, until the patients developed any evidence of mucositis. Subsequently, laser probe was used to irradiate the specific points, which were erythematous and will be developing into areas of mucositis. Hence, the scanner acted as a preventive measure whereas probe was a treatment modality. As radiation treatment for a malignancy will certainly produce some of its effects on normal tissues included in the portal, laser treatment was tried with the objective of decelerating the progression of oral mucositis. This is a valuable strategy, as it could ensure that patients can complete the treatment without interruptions, and better local tumor control can be achieved, besides maintaining a

better quality of life. In our study, patients receiving laser treatment had a significant delay in development of mucositis compared to the placebo arm. 66% of patients were free of mucositis even at the end of the second week. There were no adverse effects noted with the use of low-level laser, though it is important to realize the importance of preventing retinal damage by the use of wavelength specific goggles. This is consistent with the previous reports [14, 15].

Results of our study showed LLLT was significantly effective in reducing the oral mucositis scores in laser group than Placebo group patients ($p=0.001$). The incidence of severe (grade 4) mucositis was far less in the treatment group (0% vs.24%). Mucositis scores grading revealed that the laser group did not progress to grade III/IV mucositis and performed fairly well. The improvement in subjective symptoms reported by the patient for pain or for impairment of function could be directly credited to the non-progression of mucositis because of laser treatment. Hence, the subjective responses were reliable. Maiya *et al.* [14] also reported significant reduction in mucositis grade ($P < .001$) with grade being 1.72 ± 0.67 in the laser group and 3.32 ± 0.69 in control group. Similarly, Barasch *et al.* [7] and Migliorati *et al.* [10] also found decrease in the progression of mucositis when using LLLT.

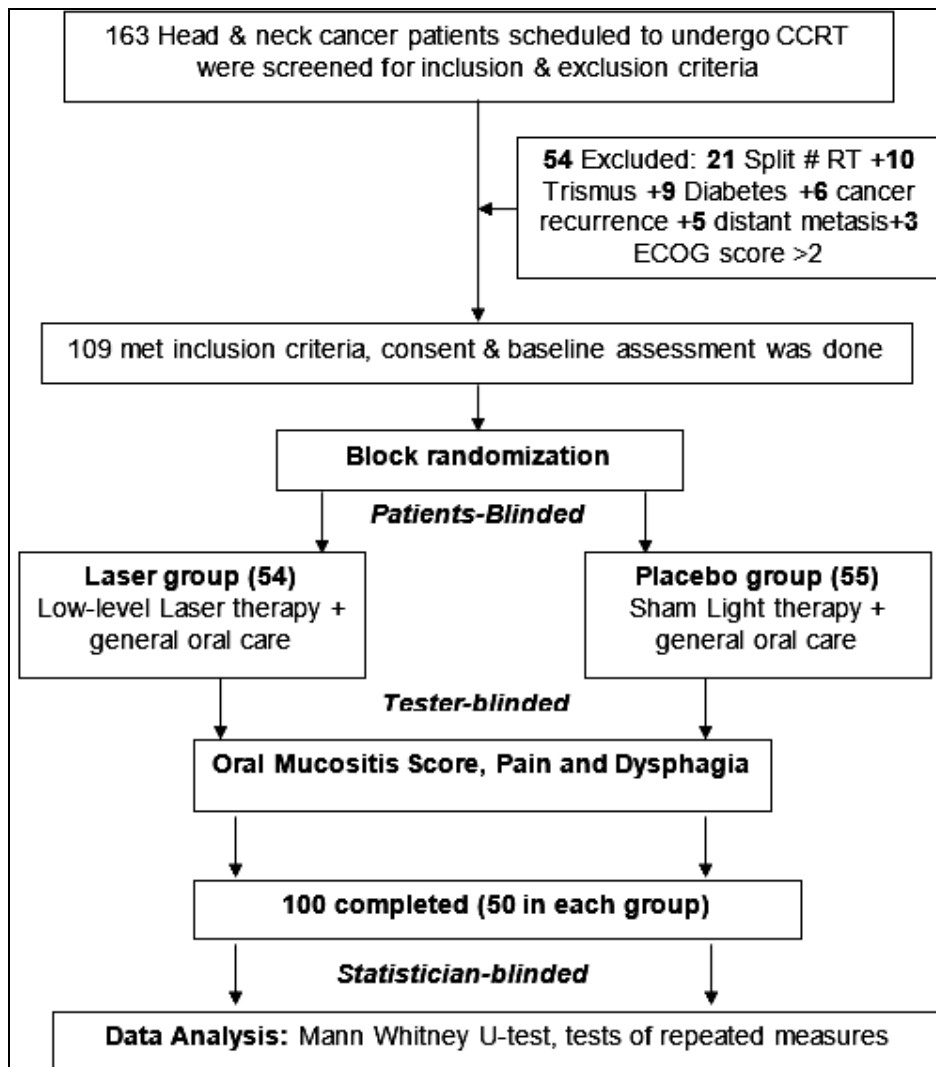


Fig 1: Flowchart of participants

Table 1: Socio demographic and clinical profile of Patients

Characteristics	Variable	Laser (Number)	Placebo (Number)
Age	20-40	5	5
	41-60	23	22
	61-80	22	23
Sex	Males	41	39
	Females	9	11
Site	Oral cavity	27	28
	Oropharynx	23	22
Stage	II	6	5
	III	17	10
	IV a	15	18
	IV b	12	17

Table 2: Oral mucositis scores among the Laser and Placebo groups

WEEK	Laser Group (50)					Placebo Group (50)				
	0	1	2	3	4	0	1	2	3	4
1	100%	0%	0%	0%	0%	98%	2%	0%	0%	0%
2	66%	32%	2%	0%	0%	42%	46%	12%	0%	0%
3	22%	52%	20%	6%	0%	8%	70%	12%	0%	0%
4	4%	48%	38%	10%	0%	0%	32%	48%	12%	8%
5	0%	26%	60%	12%	2%	0%	8%	52%	32%	8%
6	0%	18%	48%	30%	4%	0%	0%	32%	52%	16%
7	0%	16%	36%	48%	0%	0%	0%	26%	50%	24%

Table 3: Statistical significance of the difference between the 2 arms: p value Parameters measured

Stage of disease	Oral mucositis
II	0.16
III	0.002
IV	0.001

Conclusion

Our study supports the contention that laser therapy applied prophylactically during concurrent chemo-radiotherapy can reduce the severity of mucositis. A larger study needs to be done to confirm this clinically important end point.

References

- Vokes E, Haraf D, Kies M. The use of concurrent chemotherapy and radiotherapy for locoregionally advanced head and neck cancer. *Semin Oncol* 2000; 27:34-8.
- Forastiere AA, Trotti A. Radiotherapy and concurrent chemotherapy: a strategy that improves locoregional control and survival in oropharyngeal cancer. *J Natl Cancer Inst.* 1999; 91:2065-6.
- Trotti A. Toxicity in head and neck cancer: a review of trends and issues. *Int J Radiat Oncol Biol Phys.* 2000; 47:1-12.
- Epstein JB, Emerton S, Kolbinson DA *et al.* Quality of life and oral function following radiotherapy for head and neck cancer. *Head Neck.* 1999; 21:1-11.
- Trotti A, Bellm LA, Epstein JB *et al.* Mucositis incidence, severity and associated outcomes in patients with head and neck cancer receiving radiotherapy with or without chemotherapy: A systematic literature review. *Radiother Oncol.* 2003; 66:253-62.
- Mester E, Szende B, Tota JG. Effect of laser on hair growth of mice. *Kiserl Orvostud.* 1967; 19:628-31.
- Barasch A, Peterson DE, Tanzer JM *et al.* He-Ne laser effects on conditioning-induced oral mucositis in bone marrow transplantation patients. *Cancer.* 1995; 76:2550-6.
- Cowen D, Tardieu C, Schubert M *et al.* Low energy He-Ne laser in the prevention of oral mucositis in patients undergoing bone marrow transplant: results of double-blind randomized trial. *Int J Radiat Oncol Biol Phys.*1997; 38:697-703.
- Bensadoun RJ, Franquin JC, Ciais G *et al.* Low-energy He-Ne laser in the prevention of radiation-induced mucositis. *Support Cancer Care.* 1999; 7:244-52.
- Migliorati C, Massumoto C, de Paula Eduardo F *et al.* Low-energy laser therapy in oral mucositis. *J Oral Laser Appl.* 2001; 1:97-101.
- Wong S-F, Wilder-Smith P. Pilot study of laser effects on oral mucositis in patients receiving chemotherapy. *Cancer J.* 2002; 8:247-54.
- Jaguar GC, Prado JD, Nishimoto IN *et al.* Low-energy laser therapy for prevention of oral mucositis in hematopoietic stem cell transplantation. *Oral Diseases.* 2007; 13:538-43.
- Mark M, Schubert, Fernanda P *et al.* A phase III randomized double-blind placebo-controlled clinical trial to determine the efficacy of low-level laser therapy for the prevention of oral mucositis in patients undergoing hematopoietic cell transplantation. *Support Care Cancer.* 2007; 15:1145-54.
- Maiya AG, Sagar MS, Fernandes DJ. Effect of low-level helium-neon (He-Ne) laser therapy in the prevention & treatment of radiation induced mucositis in head & neck cancer patients. *Indian J Med Res.* 2006; 124:399-402.
- Arora H, Maiya AG, Keerthilatha MP, Sagar MS, Fernandes DJ *et al.* Efficacy of He-Ne Laser in the prevention and treatment of radiotherapy-induced oral mucositis in oral cancer patients. *Oral Surg Oral Med Oral Pathol Oral Radiol Endod.* 2008; 105:180-6.
- Pourreau-Schneider N, Ahmed A, Soudry M *et al.* Helium-neon laser treatment transforms fibroblasts into myofibroblasts. *Am J Pathol.* 1990; 137:171- 8.