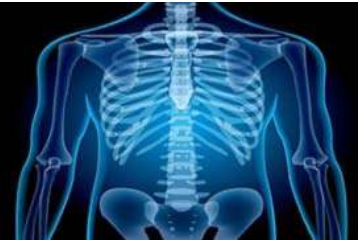

International Journal of Radiology and Diagnostic Imaging



E-ISSN: 2664-4444
P-ISSN: 2664-4436
IJRDI 2020; 3(1): 123-128
Received: 19-11-2019
Accepted: 21-12-2019

Dr. Devika C
MDRD, Assistant Professor,
Department of Radiodiagnosis,
Mandya Institute of Medical
Sciences, Mandya, Karnataka,
India

Dr. Sonali Ullal
MDRD, Associate Professor,
Kasturba Medical College,
Manipal University,
Mangalore, Karnataka, India

Comparative evaluation of the role of CT urography in diagnosis of urinary tract in patients with hematuria

Dr. Devika C and Dr. Sonali Ullal

DOI: <http://dx.doi.org/10.33545/26644436.2020.v3.i1b.65>

Abstract

Background and Aim: CT urography is a single comprehensive modality for the diagnosis of patients suspected with hematuria. Hence, the present study was designed to evaluate the efficacy of the diagnostic role of CTU in comparison with other diagnostic modalities.

Material and Methods: A total of 83 patients suspected with hematuria between 18-75 years of age presented at the Department of Radio-diagnosis, Kasturba Medical College (KMC), Manipal University, and Mangalore were selected. The patients were subjected to 3 phase CT examination after obtaining informed consent—first was an initial non-contrast phase followed by a nephrographic phase and then pyelographic phase. Patients' demographic details *viz.* age, gender, and clinical manifestations were recorded. Assessment parameters like sensitivity, specificity, positive predictive value, and negative predictive value were analyzed.

Results: The majority of study subjects with hematuria *i.e.* 28.92% belonged to the age group of 60-70 years followed by 25.30% in 50-60 years and 20.48% fallen in the age group of 40-50 years with male predominance. Ureterscopy was done for 17 cases, nephroscopy for 4 cases. 6 were radiodense calculi and 2 were radiolucent calculi. USG showed renal, PUJ and one VUJ calculus and hydronephrosis but it was only after CTU ureteric calculi were detected. 9 patients had both renal and ureteric calculi. Cystoscopy was done for 25 cases, out of which 17 cases showed bladder transitional cell carcinoma (TCC). In 14 cases, 11 out of 14 cases showed masses confined to the kidney (<7 cm diameter), which is corresponding to stage T1 RCC according to TMN classification. Two study subjects subjected to renal trauma were analyzed by CTU. The sensitivity and specificity of CTU for the stone were reported as 98-100% and 92-100% respectively.

Conclusion: In the present study, CTU shows high accuracy, sensitivity, and specificity in the detection of different cases of hematuria. Hence, CTU could be recommended to diagnose hematuria precisely and accurately.

Keywords: Hematuria, CT urography, sensitivity, specificity, calculi, pyelography

Introduction

Hematuria is one of the most widely recognized appearances of the urinary tract. Hematuria can begin from any site along the urinary tract and has a wide scope of causes including calculi, neoplasm, contamination, injury, drugs, coagulopathy, and renal parenchymal ailments [1]. This makes the differential finding broad and apparently incoherent. The idea of CT urography (CTU) is increasingly suitable as both the renal parenchyma and urothelium can be assessed with one generally non-obtrusive extensive assessment [2]. The method of reasoning for CT urography is that patients with haematuria can be completely researched by a solitary imaging strategy with a high level of affectability and explicitness [3]. It is particularly progressively reasonable for patients suspected with hematuria where the urinary tract must be evaluated for stone illness and neoplasms of the kidney and/or urothelium [4].

With the appearance of multi-indicator (detector) push CT scanners, assessment of the urothelium of the whole urinary tract with high-resolution slender areas during a solitary breath-hold has become a reality. Starting outcomes with this new system are empowering. Current examinations of MDCTU center around techniques to improve opacification and distension of the upper urinary tract gathering frameworks, pelvis, and ureters. The role of abdominal compression, implantation of saline or potentially furosemide, and ideal time postponement of excretory stage imaging is being investigated. Upper tract urothelial malignancies, including little sores (stones) less than 5 mm in distance across, can be

Corresponding Author:
Dr. Devika C
MDRD, Assistant Professor,
Department of Radiodiagnosis,
Mandya Institute of Medical
Sciences, Mandya, Karnataka,
India

distinguished with high affectability. Intravenous urography, ultrasonography, CT, retrograde urethrography and pyelography, cystoscopy, and ureteroscopy would all be able to be utilized to assess patients with hematuria.

The CTU procedure depends on the obtaining of non-enhanced and enhanced CT outputs of the midriff and pelvis, including the basic securing of dainty segment helical CT sweeps of the urinary tract during the excretory period of the upgrade. Multiplanar 2-dimensional and 3-dimensional reorganization images are created from axial source images during the excretory stage. The principal benefit of the CTU strategy is its capacity to identify uroepithelial malignancies. CTU gives an itemized anatomic portrayal of every one of the significant parts of the urinary tract *viz.* kidneys, intrarenal collecting systems, ureters, and bladder and thus play a pivotal role in a comprehensive evaluation of patients suffering from hematuria.

CTU offers a few imperative points of interest for imaging of the urinary tract: single breath-hold coverage of the whole urinary tract with an absence of respiratory misregistration, quick imaging with ideal contrast medium opacification and decreased partial volume effect as fitting cuts can be chosen from the volumetric figures. With this regards the present study was designed to evaluate the role of CTU in the diagnosis of the urinary tract in patients suffering from hematuria in comparison with other diagnostic modalities *viz.* intravenous urography, ultrasonography, CT, retrograde urethrography and pyelography, cystoscopy, and ureteroscopy.

Materials and Methods

Study subjects

Total of 83 patients suspected with a history of hematuria between 18-75 years of age presented at the Department of Radio-diagnosis, KMC, Manipal University, Mangalore were selected.

Inclusion criteria

- Patients presented with microscopic and macroscopic hematuria

Exclusion criteria

- Patients below 18 and above 75 years of age.
- Pregnant and lactating patient
- Patients with Serum Creatinine >1.8 and cases not on dialysis
- Cardiac failure
- Multiple myeloma
- Previous allergic reaction to contrast media
- Patients with known bleeding disorders

Imaging technique

The patients underwent a 3 phase CT examination after obtaining informed consent in written form. First was the initial non-contrast phase (Oral and rectal water - one liter). After half an hour contrast test dose was given. The corticomedullary phase was acquired 15-25 seconds after administration of intravenous non-ionic contrast [100 ml at a rate of 2 ml/sec.]. The next phase was the nephrographic phase, which was acquired following a delay of 30-55 seconds to evaluate the renal parenchyma. Followed by the pyelographic phase which was taken 8-15mins. Following

administration, to evaluate the urothelium from the pelvicalyceal system to the bladder. This was performed with a Multidetector CT scanner (G E Bright speed). CT scans were obtained from the kidneys to the bladder with the following technique: 100- 120 kv. 300- 350 m As. [Auto m As] Images were reconstructed at a thickness of 5 mm. Three-dimensional (3D) reconstructions of the non-enhanced, nephrogenic phase and excretory phase were performed.

Ethical approval

Clearance from the ethical committee of KMC, Manipal University, Mangalore was sought and obtained before the initiation of the study.

Data analysis

Patients' demographic details *viz.* age, gender, and clinical manifestations were recorded. Assessment parameters like sensitivity, specificity, positive predictive value, and negative predictive value were analyzed.

Results

Out of 83 study subjects diagnosed with haematuria, 24 (28.92%) belonged to age group of 60-70 years followed by 21 (25.30%) in 50-60 years, 17 (20.48%) in 40-50 years, 12 (14.46%) in 70-75 years, 5 (6.02%) in 30-40 years and 4 (4.82%) number of study subjects fallen in the age group of 20-30 years. Male predominance (83.13%) of study subjects was observed as compared to females (16.87%) (Table 1 and 2).

Table 1: Distribution of Study Subjects According to Age

Age (years)	No. of Patients	Percentage
20-30	4	4.82
30-40	5	6.02
40-50	17	20.48
50-60	21	25.30
60-70	24	28.92
70-75	12	14.46
Total	83	100

Table 2: Distribution of Study Subjects According to Gender

Gender	No. of Patients	Percentage
Male	69	83.13
Female	14	16.87
Total	83	100.00

The sensitivity and specificity of CTU for stone were reported as 98-100% and 92-100% respectively. The plain phase of our CT protocol showed all urinary calculi and proximal hydronephrosis due to the calculi. 7 renal calculi, 17 ureteric calculi, 3 pelvic-ureteric junctions (PUJ) calculi, and 5 vesicoureteric junctions (VUJ) calculi were noted. Ureteroscopy was done for 17 cases, nephroscopy for 4 cases. 6 were radiodense calculi and 2 were radiolucent calculi. USG showed renal, PUJ and one VUJ calculus and hydronephrosis but it was only after CTU ureteric calculi were detected. 9 patients had both renal and ureteric calculi (Figure 1).

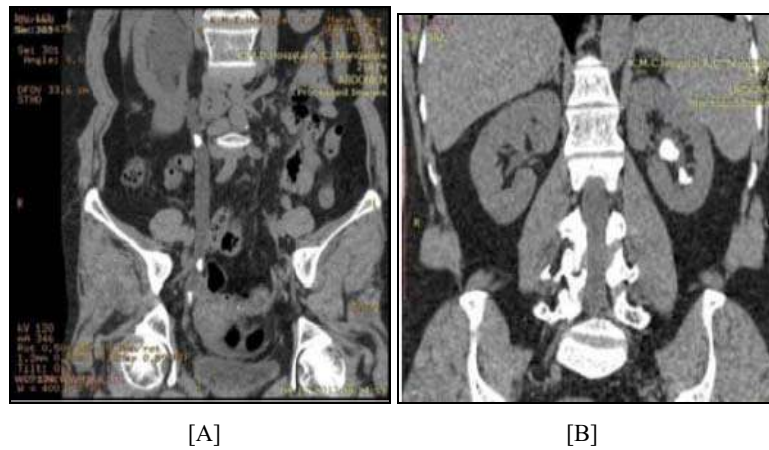


Fig 1: [A]-Showing 2 calculi in right ureter; [B] - Showing left renal calculi

Cystoscopy was done for 25 cases, out of which 17 cases showed bladder transitional cell carcinoma (TCC). Gross hematuria is not only a diagnosis. It is a symptom with an underlying cause, which is often serious and 15–28% of patients with gross hematuria have a malignancy in the urinary tract as the underlying cause. When examining

patients with gross hematuria, the most common tumor found in up to 20% of patients, is bladder cancer. Other tumors causing gross hematuria are renal cancer, urothelial cell carcinoma (UCC) of the renal pelvis and the ureters, and prostate cancer (Figure 2 and 3).

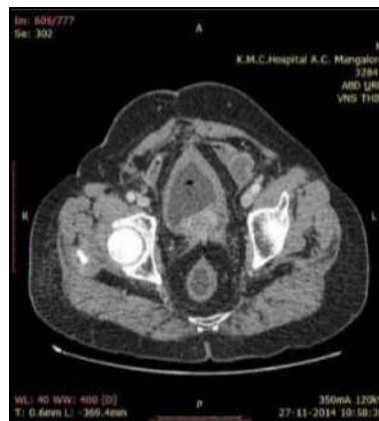

Fig 2: Case of urinary bladder TCC; CT axial image showing enhancing lesion in the left posterolateral wall with the involvement of left VUJ

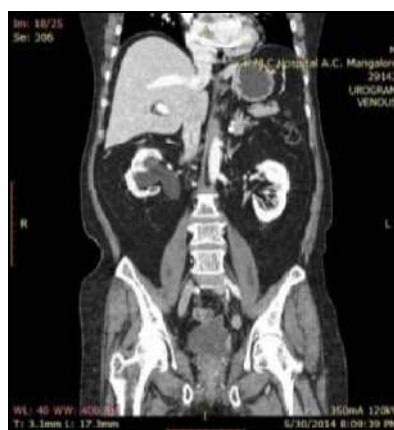

Fig 3: Showing enhancing lesion in bladder base with extension to right VUJ; Cystoscopy-radiation cystitis

Renal Cell Carcinoma (RCC) Cases: 14 cases 11 out of 14 cases showed masses confined to the kidney (<7 cm diameter), which is corresponding to stage T1 RCC according to TNM classification. The attenuation difference of 20 HU or more between non-contrast and post-contrast images was diagnostic for pathological enhancement. In one case the mass was more than 7 cm in diameter, confined to

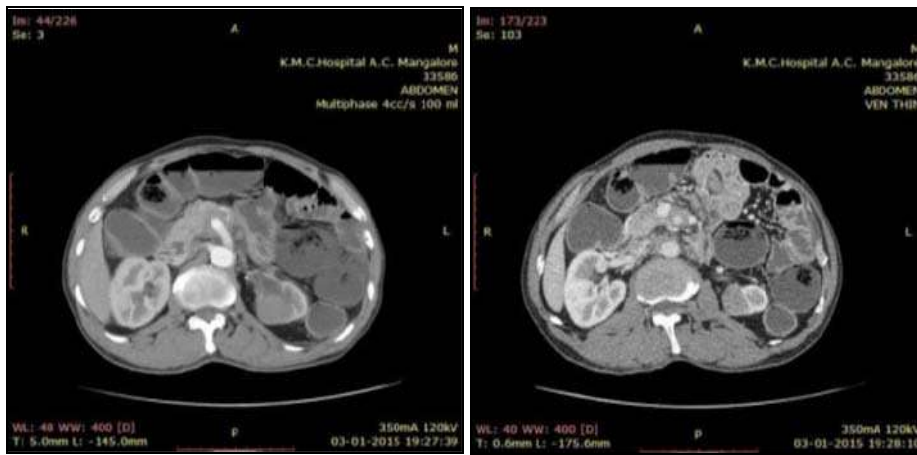
the kidney and associated with enlarged regional lymph nodes (corresponding to grade T2 and N2). Two cases showed renal vessel infiltration, corresponding to stage T3B. All the cases underwent nephrectomy and biopsy showed 3 as clear cell carcinoma (Figure 4).

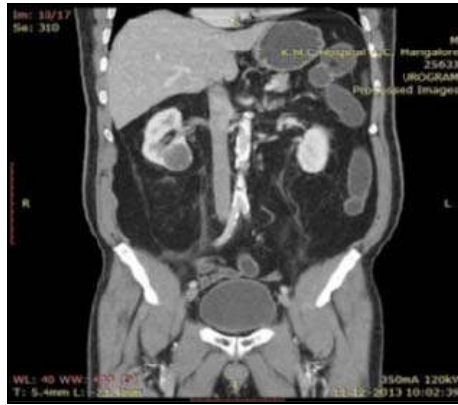

Fig 4: Image showing of right RCC case

Renal lymphoma was found in one case and appeared like the right renal homogenous mass lesion associated with

para-aortic enlarged lymph nodes (Figure 5).



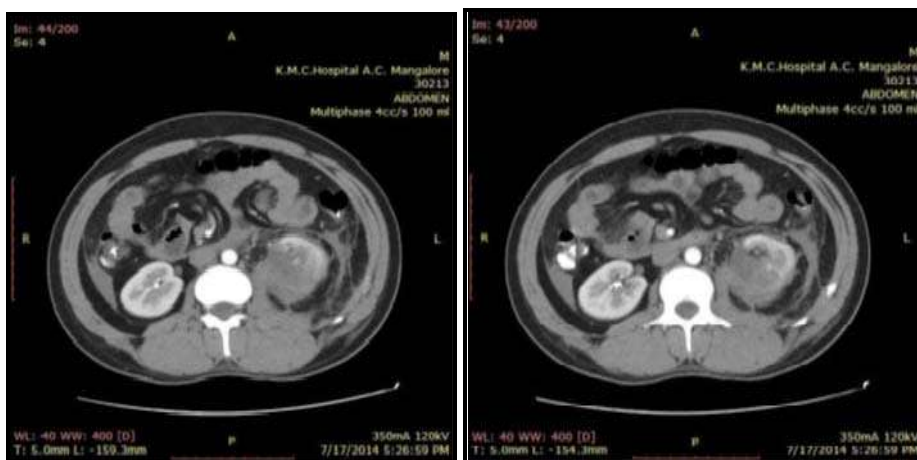
[A]

[B]

Fig 5: [A]-Showing case of lymphoma in the left kidney; [B]- Showing case of lymphoma in the left kidney with mesenteric and paraaortic lymph nodes

In the present study, two study subjects subjected to renal trauma were analyzed by CTU: one showed minor medullary contusion which appeared as the focal medullary area of hypodensity in non-contrast scan then become hypodense to normal renal parenchyma after contrast injection. These changes correspond to stage 1

renal injury. Another case showed complete separation of the lower pole of the left kidney with the involvement of the pelvic calyceal system, leakage of excreted contrast and perinephric hematoma. The vascular pedicles of both parts of the kidney were intact (stage 2 renal injuries) (Figure 6).



[A]

[B]

Fig 6: [A]-Showing left kidney injury; [B] - renal injury with perinephric hematoma

Discussion

Intravenous urography, ultrasonography, CT, retrograde urethrography and pyelography, cystoscopy, and ureteroscopy could all be utilized to assess patients with hematuria. Earlier, an amalgamation of a few of these was essential to completely assess patients. Although currently, CTU allows the evaluation of hematuria patients with a solitary exhaustive assessment, more experience and information is expected to decide its efficacy [5, 6]. Hence, the present study was conducted to evaluate the efficacy of CTU in the diagnosis of hematuria in comparison with the aforementioned diagnostic modalities.

The most common cause of hematuria is urolithiasis. Previous studies have shown that ultrasound combined with conventional radiography has a sensitivity of 70% in detecting urinary tract calculi. Conventional radiographs alone have a sensitivity of 60% for the same. Prior studies also show that intravenous urogram (IVU) is a less sensitive modality for the detection of calculi with false-negative results in 48% of cases. Nearly all stones were detected by CT urography. The sensitivity of ultrasound for the evaluation of macroscopic hematuria in the era of MDCTU is lower than expected. The sensitivity and specificity of CTU for calculi diseases are reported as 98-100% and 92-100% respectively. In our study, both the sensitivity and specificity in detecting urinary calculi by CTU was 100%. USG didn't show the ureteric calculi with a specificity of 47% as compared to CTU. With regards to urinary tract neoplasms, compared to ultrasound or IVU, CTU is accurate in the detection of renal masses. In our study, there were 14 cases of RCC with sensitivity and specificity of 100% and 98% respectively, positive predictive value (PPV) of 93% and negative predictive value (NPV) of 100%. Accuracy is 98%, CTU urography along with cystoscopy can be used in the detection of bladder carcinoma. In our study, the sensitivity, specificity, PPV, and NPV for bladder carcinoma was 100%, 97%, 89%, and 100% respectively. With regard to malignant upper urothelial abnormalities, CTU was more sensitive than retrograde pyelography in detecting pathology (98% vs. 79% of 84 lesions). Up to 40% of cases can be missed by IVU. In our study, there were 4 urothelial tumors of the ureter which were picked up by CTU with a sensitivity of 100% and histopathology confirmed the diagnosis.

MDCTU offers a few points of interest for imaging of the urinary tract *viz.* single breath-hold coverage of the whole urinary tract with the nonattendance of respiratory miss-enrollment, quick imaging with ideal complexity medium opacification and decreased partial-volume effect as suitable cuts can be chosen from the volumetric figures. Also, obtaining different slender covering cuts gives astounding two-dimensional (2D) and three dimensional (3D) reorganizations [7].

Joffe *et al.*, reported dose level of radiation is only one apprehension about a comprehensive CT technique for the study subjects suspected with hematuria [8]. In an investigation led by Dark Singes *et al.*, every arrangement of the assessment conveys a dosage of around 10 mGy (1 rad) which is essentially higher than the average dosage for IVU. To confine the radiation dosage, they chose not to cover the whole abdomen and pelvis on all periods of the assessment [9]. In our study, we tried to reduce the radiation dose to the patients by arterial phase, corticomedullary and nephrographic phases were limited to the kidneys. In the

present study, we used reconstructed coronal and sagittal images and found them very useful for the proper orientation of the lesions and their relation to the surrounding structures. Caoili *et al.*, reported that 3D CT images are useful in the evaluation of patients with anatomic variation as well as the contour abnormality of the renal outline [10].

We used non-contrast scan for renal masses to assess the baseline attenuation and degree of post-contrast enhancement as well as to detect calcification and hemorrhage, this is in agreement with Sheth *et al.*, expressed an underlying arrangement of unenhanced scans through the kidneys ought to be a piece of each convention for assessment of a speculated renal mass; it gives a gauge to quantify the upgrade inside the injury after the organization of intravenous complexity (contrast) material. Since most renal cell carcinomas have a rich vascular stockpile, they enhance altogether after the organization of complexity (contrast) material. Enhancement values of more than 12 HU are viewed as suspicious for malignancy [11]. We used the corticomedullary phase to detect the arterial supply of renal masses, collateral vessels as well as the involvement of the renal vein.

These findings are in corroboration with findings of Sheth *et al.*, also wherein the corticomedullary phase is essential for accurate staging of renal cell carcinoma. Maximal opacification of the renal arteries and veins occurs, allowing confident diagnosis of venous extension of tumoral tissue. 16% of renal masses were reported in the present study; MDCT correctly diagnosed the nature of renal masses in 98% of cases. It also helped in accurate staging renal cell carcinoma in all cases, this goes in accordance with findings of Maheshwari *et al.*, who stated that CT has a staging accuracy of up to 91%, making it the imaging method of choice for most patients. In the management of renal trauma, they use less invasive procedures and managed conservatively. If the injury is severe then surgery is mandatory [12]. So, it is important to precisely determine whether to provide conservative or surgical treatment using multislice scanner coronary angiography (MSCT) and it was very useful in detection and grading of renal trauma in a short scan time [13].

Conclusion

In conclusion, for patients with hematuria, many imaging techniques are used for the diagnosis. In this study, CTU shows high accuracy, sensitivity, and specificity in the detection of different cases of hematuria in patients including calculi, renal injuries, inflammatory and neoplastic lesions. Most of the ureteric stones were diagnosed accurately by CTU as compared to other diagnostic modalities. CTU offers the advantage of a reduction of radiation dose according to the suspected underlying cause. Hence, CTU could be recommended to diagnose hematuria precisely and accurately.

References

1. Song JH, Beland MD, Mayo-Smith WW. Hematuria evaluation with MDCT urography: is a contrast-enhanced phase needed when calculi are detected in the unenhanced phase. *American Journal of Roentgenology*. 2011; 197(1):W84-9.
2. Cowan NC, Turney BW, Taylor NJ, McCarthy CL, Crew JP. Multidetector computed tomography

- urography for diagnosing upper urinary tract urothelial tumour. *BJU international*. 2007; 99(6):1363-70.
3. Grainger RG, Allison DJ, Aam A, Dixon. Textbook of radiology. 4th edition, Churchill Livingstone, 2, 1492-1493.
 4. Jinzaki M, Tanimoto A, Shinmoto H, Horiguchi Y, Sato K, Kuribayashi S *et al*. Detection of bladder tumors with dynamic contrast-enhanced MDCT. *American Journal of Roentgenology*. 2007; 188(4):913-8.
 5. Sadow CA, Silverman SG, O'Leary MP, Signorovitch JE. Bladder cancer detection with CT urography in an Academic Medical Center. *Radiology*. 2008; 249(1):195-202.
 6. Sudakoff GS, Dunn DP, Guralnick ML, Hellman RS, Eastwood D, See WA. Multidetector computerized tomography urography as the primary imaging modality for detecting urinary tract neoplasms in patients with asymptomatic hematuria. *The Journal of urology*. 2008; 179(3):862-7.
 7. Maher MM, Kalra MK, Rizzo S, Mueller PR, Saini S. Multidetector CT urography in imaging of the urinary tract in patients with hematuria. *Korean journal of radiology*. 2004; 5(1):1-0.
 8. Joffe SA, Servaes S, Okon S, Horowitz M. Multi-detector row CT urography in the evaluation of hematuria. *Radiographics*. 2003; 23(6):1441-55.
 9. Gray Sears CL, Ward JF, Sears ST, Puckett MF, Kane CJ, Amling CL. Prospective comparison of computerized tomography and excretory urography in the initial evaluation of asymptomatic microhematuria. *The Journal of Urology*. 2002; 168(6):2457-60.
 10. Caoili EM, Korobkin M, Francis IR, Cohan RH, Platt JF, Dunnick NR *et al*. Adrenal masses: characterization with combined unenhanced and delayed enhanced CT. *Radiology*. 2002; 222(3):629-33.
 11. Sheth S, Fishman EK. Multi-detector row CT of the kidneys and urinary tract: techniques and applications in the diagnosis of benign diseases. *Radiographics*. 2004; 24(2):e20.
 12. Maheshwari E, O'Malley ME, Ghai S, Staunton M, Massey C. Split-bolus MDCT urography: upper tract opacification and performance for upper tract tumors in patients with hematuria. *American Journal of Roentgenology*. 2010; 194(2):453-8.
 13. Smith JK, Kenney PJ. Imaging of renal trauma. *Radiologic Clinics of North America*. 2003; 41:1019-1035.