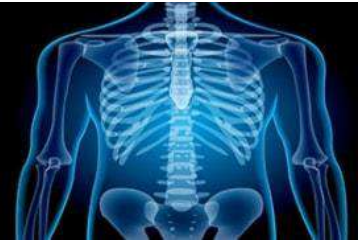

International Journal of Radiology and Diagnostic Imaging



E-ISSN: 2664-4444
P-ISSN: 2664-4436
IJRDI 2020; 3(1): 129-134
Received: 17-11-2019
Accepted: 21-12-2019

Jignesh Bhudiya
Department of Radiodiagnosis,
Baroda medical college and
SSG hospital, Vadodara,
Gujarat, India

Bhumika Suthar
Department of Radiodiagnosis,
Baroda medical college and
SSG hospital, Vadodara,
Gujarat, India

Study of different ankle pathologies on MRI

Jignesh Bhudiya and Bhumika Suthar

DOI: <http://dx.doi.org/10.33545/26644436.2020.v3.i1b.66>

Abstract

Purpose: The aim of this study is to evaluate the role of MRI in characterization of different ankle pathologies based on their aetiology and evaluate the prevalence of different pathologies in different age group and evaluate involvement of different structure in various ankle pathologies.

Patients and methods: This study include 47 patients (23 male and 24 female) with different complains of ankle including pain around the ankle, decreased movement of ankle joint, difficulty in walking, swelling around the ankle, tenderness around the ankle and trauma to the ankle underwent Magnetic Resonance Imaging of the ankle joint.

Results: In our study included 47 patients with different ankle complain were subjected to MRI of the affected ankle after initial examination and basic investigation including plain radiography. Maximum number of pathologies were detected in the age group of 41 to 60 years in 46.80% of the patients. Most common structure involved were joints, it was involved in 28 patients (59.57%). Traumatic etiology was more common in our study and seen in 18 patients (38.29%) followed by degenerative etiology in 11 patients (23.40%). Lateral ligament complex was most frequently injured ligament representing 83.33%. Although it is the strongest tendon in the human body, Achilles tendon was the most commonly injured ankle tendon.

Conclusion: Because of exquisite soft-tissue contrast resolution, noninvasive nature, and multiplanar capabilities of MR imaging make it especially valuable for the detection and assessment of a variety of soft-tissue as well as osseous and bone marrow disorders.

Keywords: Magnetic resonance imaging; Ligaments; Tendons; Injuries; Neoplasm; Degenerative; Infective/inflammatory.

1. Introduction

The past 15 years have witnessed an explosion of information regarding the role of magnetic resonance (MR) imaging in assessing pathologic conditions of the ankle. MR imaging has revitalized the study of musculoskeletal disease in this anatomic area due to its high soft-tissue contrast resolution and multiplanar capabilities^[1].

It provides a quick, noninvasive tool for the diagnosis of related injuries, which are often difficult to diagnose with alternative modalities. MR imaging is particularly advantageous for assessing soft-tissue structures around the ankle such as tendons, ligaments, nerves, and fascia and for detecting occult bone injuries^[1].

Magnetic resonance (MR) imaging has opened new horizons in the diagnosis and treatment of many musculoskeletal diseases of the ankle and foot. It demonstrates abnormalities in the bones and soft tissues before they become evident at other imaging modalities.

The exquisite soft-tissue contrast resolution, noninvasive nature, and multiplanar capabilities of MR imaging make it especially valuable for the detection and assessment of a variety of soft-tissue disorders of the ligaments (eg, sprain), tendons (eg, tendinosis, peritendinosis, tenosynovitis, entrapment, dislocation), and other soft-tissue structures (eg, anterolateral impingement syndrome, sinus tarsi syndrome, compressive neuropathies [eg, tarsal tunnel syndrome, Morton neuroma], synovial disorders. MR imaging has also been shown to be highly sensitive in the detection and staging of a number of musculoskeletal infections including cellulitis, soft-tissue abscesses, and osteomyelitis^[1].

In addition, MR imaging is excellent for the early detection and assessment of a number of osseous abnormalities such as bone contusions, stress and insufficiency fractures, osteochondral fractures, osteonecrosis, and transient bone marrow edema^[2].

MR imaging is increasingly being recognized as the modality of choice for assessment of pathologic conditions of the ankle.

Corresponding Author:
Bhumika Suthar
Department of Radiodiagnosis,
Baroda medical college and
SSG hospital, Vadodara,
Gujarat, India

Routine ankle MR imaging is performed in the axial, coronal, and sagittal planes parallel to the table top. The foot is imaged in the oblique axial plane (ie, parallel to the long

axis of the metatarsal bones), oblique coronal plane (ie, perpendicular to the long axis of the metatarsals), and oblique sagittal plane (Fig 1.1).

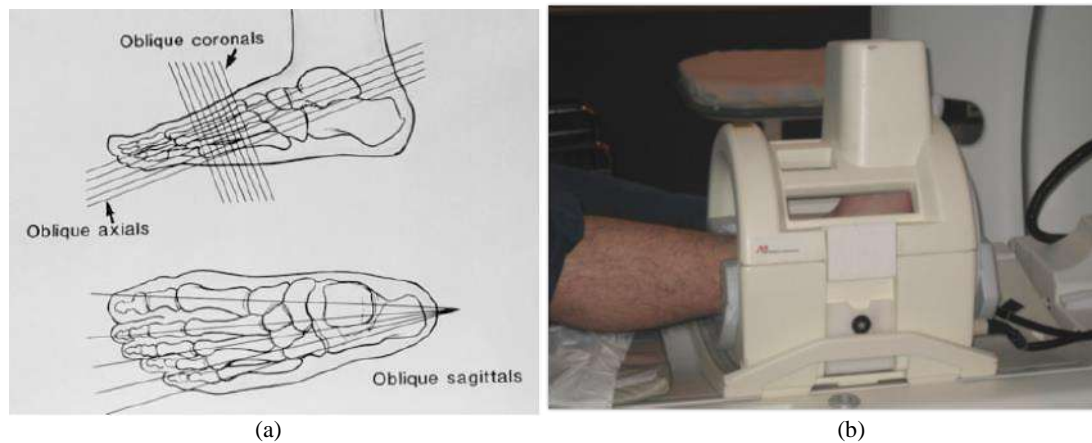


Fig 1.1: (a) Drawings of the foot illustrate the oblique axial, oblique coronal, and oblique sagittal imaging planes (1). (b) Dedicated foot and ankle coil incorporate a chimney like extension so that the phalanges can be included in the FOV.

The patient is supine with the foot in about 20° of plantar flexion. Plantar flexion is useful for three reasons: it decreases the magic angle effect, it accentuates the fat plane between the peroneal tendons, and it allows better visualization of the calcaneofibular ligament. The magic angle effect produces increased signal within normal tendons when they form an angle of about 55° with the main magnetic vector [3].

A standard extremity coil generally was employed for the ankle and if it was not available, the knee coil was used.

The ligaments are readily identified as thin, linear, low-signal-intensity structures joining adjacent bones and are usually delineated by contiguous high-signal-intensity fat [4]. Heterogeneity is typically seen due to the interposition of fat between the ligamentous fibers. This is particularly true for the anterior tibiofibular ligament, the tibiotalar components of the deltoid ligament, and the posterior talofibular ligament. Axial and coronal imaging with the foot in dorsiflexion and plantar flexion have been recommended to allow visualization of the ligaments in their entirety [5]. The ligaments can also be studied with 3D Fourier transform reformatted images [6].

The MR imaging criteria for the diagnosis of acute rupture of ligament include morphologic and signal intensity alterations within and around the ligament [7].

1.1 Aims and objective: To categorize different ankle pathology using MRI based on their aetiology and evaluate the prevalence of different pathologies in different age group and evaluate involvement of different structure in various ankle pathologies.

2. Materials and Methods

2.1 Study design: Record based descriptive study

2.2 Sample size: Time bound (47 cases).

2.3 Study Duration: August 2018 to August 2019

2.4 Inclusion Criteria:

- Patient coming to orthopaedic department of SSG hospital having ankle joint related complains.
- Patients coming directly to SAHYOG imaging centre from other hospitals for ankle MRI.

2.5 Exclusion Criteria

- Patients who are having any type of orthopaedic implants in ankle region.
- Patient with metallic hip implants and cardiac pace maker.
- Patient with pregnancy.
- Patients with normal MRI findings.

2.6 Methods

My intended study is a record base study, which will be carried out on the patients visiting the OPD/IPD and referred from other health centre for advance treatment of different ankle pathologies to the Department of Radiodiagnosis, Medical College Vadodara for a period of 12-month duration.

MRI will be done by using GE signa hdxt 1.5 tesla MRI machine at SAHYOG imaging enter in Medical College, Vadodara.

Clinical information included brief history of patient, with whole spectra of varied symptoms including pain in and around ankle, restriction of joint movement, difficulty in walking, swelling with or without tenderness around the ankle and fever with or without chills which caused the clinician to get done an MRI ankle.

2.7 MRI Examination

- MRI was performed using GE signa hdxt 1.5 tesla MRI machine.

2.7.1 Patient position and coils

- Imaging was done with the foot about 20° of plantar flexion with the patient in a supine position. A standard knee coil was used. A marker (Pudinhara tablet) would be kept at the site of clinical complain.

2.7.2 Scanning protocol

- The imaging planes, sequences, and even the selection of which coil to use varied depending on the clinical circumstances. The lower extremity was externally rotated and the planes of imaging were oriented to the anatomy of the foot, rather than to the magnet. Only the

extremity with a suspected abnormality was imaged to employ a small field of view to increase the detail and resolution of the images.

- The FOV included the distal tibia and fibula, all of the tarsal bones, and the bases of the metatarsals.
- Slice thickness ranged from 3-5 mm with gap of 1 mm.
- Matrix 256/192.

2.8 MRI Sequences

- 2.8.1 T1W images: It was evaluated for normal anatomy of bones, ligaments, tendons, joints, synovium, soft tissue and neurovascular bundle in axial, coronal and sagittal planes.
- 2.8.2 T2W images: It was evaluated for pathologies of bones, ligaments, tendons, joints, synovium, soft tissue and neurovascular in axial, coronal and sagittal planes.
- 2.8.3 PD FS (proton density fat saturation) images: It is particularly important when tendons and ligaments are site of clinical concern and evaluated in axial, coronal and sagittal planes.
- 2.8.4 STIR (short T1 inversion recovery) images: It was particularly evaluated for bone marrow, bone tumour and metastasis in axial, coronal and sagittal plane.
- 2.8.5 Post contrast T1W images: It was evaluated in case of bone or soft tissue mass and other infective aetiology as and when required.
- 2.9 Data analysis: To be done in Microsoft Excel by descriptive analysis of different ankle pathologies on MRI sequences and characterize them.
- 2.10 Outcome: List of the different ankle pathologies that can be better diagnosed with the help of MRI. Categorization and characterization of ankle pathologies on MRI.
- 2.11 Final confirmatory diagnosis: Final confirmatory diagnosis was affirmed as per Clinical/Radiological features.

3. Result and discussion

MRI features of different pathologies were evaluated using various conventional as well as specific MR sequences and characterized based on their etiology, structure involve in the pathology and associated abnormalities. After careful evaluation of different MR sequences and patient’s clinical complain, final diagnosis was made.

The patients in our study were arranged in age groups of 20 years beginning from below 20 years. The youngest patient in our study was 14 years old, whereas the oldest patient was 70 years old.

Out of the 47 case studies, maximum number of pathologies were detected in the age group of 41 to 60 years in 47% of the patients, followed by 20 to 40 years age in 32% of the patients.

Table 3.1: Classification based on various structure involved

Structure involved (n=47)	Number	%
Tendons	14	26.78%
Ligaments	18	38.29%
Bones	26	55.31%
Joints	28	59.57%
Synovium	6	12.76%
Soft tissue	8	17.02%
Neurovascular bundle	0	0%
Muscles	0	0%

In our study of 47 patients we found that different structure at the ankle joint like tendons, ligaments, bones, joints, synovium and soft tissue were involved in different pathology. In our study most common structure involved was joints in 59.57% patients of which most common joint involved was tibiotalar joint which was involved in 67.85% of patient, second most common structure involved was bones, it was involved in 55.31%. There were no involvement of neurovascular bundle and muscles seen in any of the patients in our study.

Table 3.2: Classification based on types of etiology

Type of etiology (n=47)	Number	%
Traumatic	18	38.29%
Infective/inflammatory	9	19.14%
Degenerative	11	23.40%
Neoplastic	5	10.63%
Miscellaneous	5	10.63%

Patients were broadly grouped into categories based on their etiology into traumatic, infective/inflammatory, degenerative, neoplastic and other etiology. We found that traumatic etiology was more common and seen in 18 patients (38.29%) followed by degenerative etiology seen in 11 patients (23.40%) while least common specific etiology was neoplastic seen in 5 patients (10.63%). Infective/inflammatory etiology was seen in 9 patients (19.14%) and other miscellaneous etiology was found in 5 patients (10.63%) which include synovial chondromatosis, os trigonum, focal marrow edema isolated joint effusion and reflex sympathetic dystrophy.

Most common traumatic pathology was ligament tear which was found in 11 patients (61.11%), second most common pathology was ligament sprain which was seen in 7 patients (38.88%). Tendon tear was seen in 6 patients (33.33%) and bone fracture was seen in 4 patients (22.22%).

Table 3.3: Classification of various pathologies involving different ligamentous compartments

Ligamentous compartment	Medial compartment ligaments	Lateral compartment ligaments	Syndesmotc ligaments
Complete thickness tear (n=3)	2 (66.66%)	2 (66.66%)	1 (33.33%)
Partial thickness tear (n=10)	6 (60%)	6 (60%)	2 (20%)
Sprain (n=9)	4 (44.44%)	7 (77.77%)	1 (11.11%)

In our study we encountered that complete thickness tear of ligaments seen to involving medial compartment, lateral compartment and syndesmotc ligaments however commonly involving medial compartment in 2 patients (66.66%) and lateral compartment ligament in 2 patients (66.66%), it was involving syndesmotc ligaments in only 1 patient (33.33%). Partial thickness tear of ligaments seen to involving medial, lateral compartments and syndesmotc ligaments however commonly involving medial compartment in 6 patients (60%) and lateral compartment ligament in 6 patients (60%), it was involving syndesmotc ligaments in 2 patients (20%). Sprain of ligaments also seen to involving medial, lateral compartments and syndesmotc

ligaments however commonly involving lateral compartment ligaments in 7 patients (77.77%) and second most commonly involving medial compartment ligaments in 4 patients (44.44%), it was involving syndesmotic ligaments in only 1 patient (11.11%).

Deltoid/medial ligament complex was less likely to be injured compare to lateral ligament complex. This coincides with Cheng et al. (8) work which is stated that lateral ligament complex is the most commonly torn ankle ligaments and in 70% of ankle sprains lateral ligament complex is torn. The deltoid ligament is the strongest.

Table 3.4: Classification of different ligaments involved in different pathologies

LIGAMENTS INVOLVED (n=18)	COMPLETE THICKNESS TEAR	PARTIAL THICKNESS TEAR	SPRAIN
ATTL	1	6	3
PTTL	1	4	3
TiNL	1	5	3

TiSL	1	4	1
TiCL	0	5	2
ATFL	2	4	6
PTFL	0	3	1
CFL	0	2	3
ATiFL	0	3	0
TSL	1	0	0
TCL	1	0	0
TNL	1	0	0
PTiFL	0	0	0
INTEROSSEOUS	0	0	0

However, we encountered that most common ligament involved in complete thickness tear was ATFL which was seen in 2 patients followed by ATTL, PTTL, TiNL, TiSL, TSL, TCL and TNL which was seen in 1 patient each. Most common ligament involved in partial thickness tear was ATTL which was seen in 6 patients. Most common ligaments involved in sprain was ATFL which was seen in 6 patients. In our study PTiFL and interosseous ligaments were not involved in any type of ligament pathologies.

Table 3.5: Classification of various pathologies involving the different tendons

Pathologies	Achilles tendon	Plantaris	Tibialis posterior tendon	Peroneal tendons	FDL	EDL
Complete thickness tear	1	0	0	0	0	0
Near complete thickness tear	1	1	0	0	0	0
Partial thickness tear	2	0	1	1	0	0
Tendinosis	1	0	1	1	0	0
Tendinitis	0	0	1	1	0	0
Giant cell tumor	0	0	1	1	1	1
Ganglion cyst	0	0	0	0	1	0

In our study we encountered that complete thickness tear of tendon seen only involving Achilles tendons no other tendons shows complete thickness tear, near complete thickness tear of tendon seen involving Achilles tendons and plantaris tendon in 1 patient each (50%), partial thickness tear was seen involving Achilles tendon, tibialis posterior and peroneal tendons however it was seen to involved Achilles tendon most commonly which was seen in 2 patients. This is matched with Nevien El-Liethy [9] have reported that 11 cases of Achilles tendon injuries representing 52.4% of the tendinous injuries. 18.2% of these cases (2 cases) were presented with complete rupture of the Achilles tendon, however in our study partial thickness tear of Achilles tendon was more common.

Tendinosis was seen involving Achilles tendon, tibialis posterior and peroneal tendons equally in 1 patient each.

Tendinitis was seen equally involving tibialis posterior and peroneal tendons. We have found only one case of giant cell tumor involving tendon sheath of tibialis posterior, peroneal, FDL and EDL tendons.

Although it is the strongest tendon in the human body, Liffen,2014(10) agreed that the Achilles tendon is the most commonly injured ankle tendon, with the site of pathological findings is typically a zone of relative avascularity 2–6 cm from the calcaneal insertion [10]. Our result coincides with this hypothesis as Achilles tendon injury represent 50% of all diagnosed tendon injuries.

In our study, tibialis posterior tendon showed 4 pathological entities (8.5% of all cases, and 28.57% of all tendons pathologies). Shows 1 case of tendinosis, partial thickness tear, tendinitis and giant cell tumour of tendon sheath represents 25% each of pathological Tibialis posterior

tendons.

Of the three medial ankle tendons, the tibialis posterior tendon is the most frequently affected. Although there was small number of tibialis posterior tendon pathology in our study group, our results were similar to the results achieved by Nevien El Liethy [9].

Of the remaining medial ankle tendons, the FDL tendon is rarely affected by pathological changes [11, 13]. Our study included one case of giant cell tumor involving FDL.

Although the anterior ankle tendons are rarely affected with pathology in comparison with the other ankle tendons, our study included 1 case with giant cell tumour of EDL tendon sheath. This agreed with Narvaez [14] who reported that TA tendon injuries are uncommon.

Longitudinal split tears of the peroneus brevis tendon have been increasingly reported as a source of lateral ankle pain and disability. Lee *et al.* [15] studied the longitudinal split tear of the peroneus brevis tendon and reported that MRI is useful in identifying the appearance of longitudinal split tears of the peroneus brevis tendon to differentiate this entity from other causes of chronic lateral ankle pain. Mansour and Jain [16] also reported that MR imaging is useful in identifying the appearance of longitudinal split tears of the peroneus brevis.

Margetic *et al.* [11] and Mansour *et al.* [13] stated that the use MRI had demonstrated a high degree of differentiation in helping to distinguish partial thickness from tendinosis.

In our study we found that 5 patients with neoplastic etiology have different neoplastic lesions. Most common neoplastic lesion was giant cell tumor which was found in 3 patients (60%). Other neoplastic lesion in our study was ganglion cyst which was seen in 1 patient (20%) and

malignant bone tumor which was also seen in 1 patient (20%).

In our study we found that 9 patients with infective/inflammatory etiology have different infective/inflammatory pathologies. Most common infective/inflammatory pathology was synovitis which was found in 5 patients (55.55%), second most common pathology was acute osteomyelitis which was seen in 4 patients (44.44%). Other pathologies seen were erosive

arthropathy which was seen in 2 patients (22.22%), infective OA was seen in only 1 patient (11.11%) and tendinitis which was also seen in only 1 patient (11.11%).

In our study we found that 11 patients with degenerative etiology have different pathologies. Most common degenerative pathology in our study was degenerative osteoarthritis which was found in 9 patients (82%), second most common pathology was tendinosis which was seen in 4 patients (27%).

Table 3.6: Classification of different aetiology in various age group

AGE GROUP (Years) (n=47)	Traumatic	Neoplastic	Infective/ Inflammatory	Degenerative	Miscellaneous
Below 20	3 (16.66%)	1(20%)	1(11.11%)	0(0%)	2(40%)
20-40	5(27.77%)	4(80%)	3(33.33%)	2(18.18%)	1(20%)
41-60	10(55.55%)	0(0%)	4(44.44%)	7(63.63%)	2(40%)
61-80	0(0%)	0(0%)	1(11.11%)	2(18.18%)	0(0%)

Out of the 47 case studies, we come to know that different aetiologies were common in different age group. In our study traumatic etiology was most commonly seen in the patients of 41-60 years age group involving 10 patients (55.55%) which is matched with Klauser et al. and Liffen (14) who reported that tendon ruptures are commonly affecting the middle aged between 35 and 60 years. However, they have included only traumatic tendon injury among the different age group which is lacking the prevalence of other aetiology in different age group which was included in our study.

Second most common age group in our study was 20-40 years involving 5 patients (27.77%) followed by 3 patients (16.66%) below 20 year of age. In our study there was no any patient of traumatic etiology in 61-80 years age group. Neoplastic etiology most commonly found in 20-40 years age group involving 4 patients (80%), only 1 patient (20%) found to have neoplastic etiology in age group of below 20 year. Infective/inflammatory etiology most commonly found in 41-60 years age group involving 4 patients (44.44%), second most common age group was 20-40 years involving 3 patients (33.33%), followed by age group below 20 year and 61-80 year. Degenerative etiology most commonly found in 41-60 years age group involving 7 patients (63.63%), second most common age group was 20-40 years and 61-80 years involving 2 patient each (18.18%). Other miscellaneous etiology most commonly found in age group of below 20 year and 41-60 years involving 2 patients each (40%).

In our study 41-60 year of age group was most commonly involved in degenerative and traumatic etiology while 20-40 year of age group was most commonly involved in neoplastic etiology. Infective/inflammatory etiology was almost equally seen in 20-40 years and 41-60 years of age group.

4. Abbreviations: MR-Magnetic Resonance; FOV-Field of vision; OPD-Out patient department; IPD-In patient department; T1WI-T1 Weighted Image; T2WI-T2 Weighted Image; PDFS-Proton density fast spin; STIR-Short Tau inversion recovery; ATFL-Anterior talofibular ligament; ATTAL-Anterior tibiotalar ligament; PTTL-Posterior tibiotalar ligament; TiNL-Tibionavicular ligament; TiSL-Tibiospring ligament; TSL-Talospring ligament; TCL-Talocalcaneal ligament; TNL-Talonavicular ligament;

PTiFL-Posterior tibiofibular ligament; FDL-Flexor digitorum longus; EDL-Extensor digitorum longus; OA-Osteoarthritis

5. Conclusion

Among the all pathologies involving ankle joint, traumatic aetiology was more common (36.17%) followed by degenerative aetiology (25.53%). However neoplastic lesion involving ankle joint was least common (10.63%).

More common traumatic pathology was ligaments tear (64.70%) followed by ligaments sprain (41.17%). Tendon tears were seen in 29.41% of patients. More common degenerative pathology was osteoarthritis (75%) involving ankle joint. Synovitis (55%) was more common infective/inflammatory aetiology followed by acute osteomyelitis (44%). Most of the neoplastic lesions involving ankle of ankle joint were benign of which giant cell tumor (60%) was more commonly seen involving bones and tendons sheath around the ankle.

Among the all age groups 41-60 years of age group was involved more commonly in traumatic (52.94%) and degenerative (58.33%) ankle lesions. Whereas 20-40 years of age group more commonly involved in neoplastic lesions (80%).

Because of exquisite soft-tissue contrast resolution, noninvasive nature, and multiplanar capabilities of MR imaging make it especially valuable for the detection and assessment of a variety of soft-tissue as well as osseous and bone marrow disorders.

6. References

- Rosenberg ZS, Beltran J, Bencardino JT. From the RSNA refresher courses: MR imaging of the ankle and foot. *Radiographics*. 2000; 20 (SPEC.ISS.):153-79.
- Perrich KD, Goodwin DW, Hecht PJ, Cheung Y. Ankle ligaments on MRI: Appearance of normal and injured ligaments. *Am J Roentgenol*. 2009; 193(3):687-95.
- Erickson SJ, Cox IH, Hyde JS, Carrera GF, Strandt JA, Estkowski LD. Effect of tendon orientation on MR imaging signal intensity: a manifestation of the "magic angle" phenomenon. *Radiology*. 1991; 181:389-392.
- Muhle C, Frank LR, Rand T *et al*. Collateral ligaments of the ankle: high-resolution MR imaging with a local gradient coil and anatomic correlation in cadavers. *Radio Graphics*. 1999; 19:673-683.

5. Mesgarzadeh M, Schneck CD, Tehranzadeh J, Chandnani VP, Bonakdarpour A. Magnetic resonance imaging of the ankle ligaments: emphasis on anatomy and injuries to lateral collateral ligaments. *Magn Reson Imaging Clin N Am.* 1994; 2:39-58.
6. Verhaven EF, Shahabpour M, Handelberg FW, Vaes PH, Opdecam PH. The accuracy of three-dimensional magnetic resonance imaging in the diagnosis of ruptures of the lateral ligaments of the ankle. *Am J Sports Med.* 1991; 19:583-587.
7. Bencardino J, Rosenberg ZS, Delfaut E. MR imaging of sports injuries of the foot and ankle. *Magn Reson Imaging Clin N Am.* 1999; 7:131-149.
8. Cheng Y, Cai Y, Wang Y. Value of ultrasonography for detecting chronic injury of the lateral ligaments of the ankle joint compared with ultrasonography findings. *Br J Radiol.* 2014; 87:1-6.
9. El-Liethy N, Kamal H. High resolution ultrasonography and magnetic resonance imaging in the evaluation of tendino-ligamentous injuries around ankle joint. *Egypt J Radiol Nucl Med [Internet].* 2016; 47(2):543-55. Available from: <http://dx.doi.org/10.1016/j.ejrnm.2016.02.009>.
10. Liffen Neil. Achilles tendon diagnostic ultrasound examination: a locally designed protocol and audit. *Int Musculoskelet Med.* 2014; 36(1):1-12.
11. Margetic Petra, Salaj Martina, Lubina Ivan Zvonimir. The value of ultrasound in acute ankle injury: comparison with MR. *Eur J Trauma Emerg Surg.* 2009; 35(2):141-6.
12. Fessell DP, Jacobson JA. Ultrasound of the hindfoot and midfoot. *Radiol Clin North Am.* 2008; 46(6):1027-43.
13. Mansour R, Jain N. Imaging of the ankle, musculoskeletal imaging. *Imaging.* 2013; 22:1-18.
14. Narvaez JA, Cerezal L, Narvaez J. MRI of sports-related injuries of the foot and ankle. *Curr Probl Diagn Radiol.* 2003; 32(7):139-55.
15. Lee Sun Joo, Jacobson Jon A, Kim Sung-Moon, Fessell David, Jiang Yebin, Dong Qian, et al. Ultrasound and MRI of the peroneal tendons and associated pathology. *Skeletal Radiol.* 2013; 42:1191-200.
16. Mansour R, Jain N. Imaging of the ankle, musculoskeletal imaging. *Imaging.* 2013; 22:1-18.