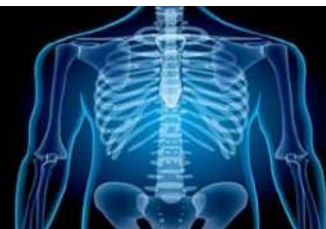

International Journal of Radiology and Diagnostic Imaging



E-ISSN: 2664-4444
P-ISSN: 2664-4436
www.radiologypaper.com
IJRDI 2020; 3(1): 215-218
Received: 23-11-2019
Accepted: 27-12-2019

Dr. Shruti Santosh Patil
Associate Professor,
Department of Radiology,
Mahadevappa Rampure
Medical College, Gulbarga,
Karnataka, India

Dr. Richesh S Tathode
Post Graduate, Department of
Radiology, Mahadevappa
Rampur Medical College,
Gulbarga, Karnataka, India

Corresponding Author:
Dr. Shruti Santosh Patil
Associate Professor,
Department of Radiology,
Mahadevappa Rampure
Medical College, Gulbarga,
Karnataka, India

MRI evaluation of internal derangement of knee

Dr. Shruti Santosh Patil and Dr. Richesh S Tathode

DOI: <http://dx.doi.org/10.33545/26644436.2020.v3.i1.c.79>

Abstract

Internal derangement of knee joint constitutes a major source of morbidity in patients attending orthopedic outpatients department of our hospital. It includes a group of disorders due to disruption of normal functioning of ligaments and menisci of knee joint leading to persistent or intermittent signs and symptoms such as pain, instability, or abnormal mobility of the knee. MRI would be a noninvasive non operator dependent effective modality for early detection of these pathologies and has very high negative predictive value. MRI of knee would save us many unnecessary diagnostic arthroscopy, which is an invasive procedure with associated risks. Fifty patients with clinically suspected internal derangement of knee (37 men, 13 women; mean age 33.2 yrs) were included in this prospective study. They were evaluated with detailed clinical history and clinical examinations and were subsequently subjected to imaging of knee using 1.5 T MRI PHILIPS ACHIEVA MRI machine. Sequences used were axial, sagittal and coronal PD Fat Sat; sagittal, axial and coronal T2 FSE and sagittal T1 FSE. This study included 50 patients with clinical suspicion of internal derangement of knee. Thirty-seven were men and 13 women with mean age of 33.2 years. Acute traumatic injury to knee exceeded the non-traumatic etiology. ACL was the commonest ligament to be injured with complete tear being more common than partial tear. LCL was the commonest ligament to be torn in association with ACL. Indirect signs of ACL injury were evaluated and helped to corroborate the tears. Meniscal injury was common in medial meniscus and predominantly involved the posterior horn. This was also the commonest site of lateral meniscal tear. Certain pattern of associations of injuries was found such as ACL tear with postero-lateral corner injury and O'Donoghue's triad.

Keywords: meniscal tear; internal derangement of knee; acl tear; bucket handle tear

Introduction

Knee being one of the major joints involved in kinesis, also bears the consequences of increased mobility. The price of its mobility is a tendency to instability. With increasing involvement in sports related activities especially in young people, trauma related knee pathologies have increased.

MRI has emerged as an excellent modality for imaging of ligaments, cartilage, menisci and other structures around the knee joint^[1]. This is due to the combination of multiplanar capability and superior soft tissue characterization. This modality has superseded already available modalities like radiograph and CT, over last two decades.

It is a non-invasive diagnostic modality that lacks the radiation issues associated with radiograph and CT and is non-operator dependent unlike ultrasound.

Tears in the menisci result from acute trauma or repetitive trauma and progressive degeneration. Chronic repetitive trauma is common both in athletes and nonathletes with aging. Acute tears are usually due to athletic injuries, with crushing of the meniscus between the tibia and femoral condyles. Most tears extend from posterior to anterior.

Chondrocyte necrosis and increase in mucoid ground substance can lead to meniscal tears.

MRI is an established method of diagnosing meniscal tears with high sensitivity and Specificity^[2].

In approximately 10% of cases, however, MRI findings are equivocal for the diagnosis of meniscal tear. Evaluation of the meniscus in these instances may be limited by partial volume averaging, truncation artifact, artifact from motion, meniscal degeneration, or normal anatomic structures abutting the meniscus^[3].

Injuries of the ligaments and menisci in knee joints are associated with particular traumatic mechanisms. MRI findings can reveal the traumatic mechanisms in many acute knee injuries. Compression and tension are the two basic loads that commonly act on the knee.

In compressive load, bones collide leading to impaction. Compressive load causes bone marrow contusion and, if sufficient in magnitude, depressed cortical fracture.

It can also damage interposed soft tissues, most commonly the articular cartilage and meniscus, when they become entrapped between bones.

In tensile load, on the other hand, bones pull apart leading to distraction across the joint and traction on stabilizing structures. Tensile load can cause ligament and tendon tears as well as avulsion fracture.

Impaction and distraction injuries have different characteristic appearances on MR Images. Impaction causes bone marrow edema. On MR images, trabecular contusion has the appearance of bone marrow edema. Ligament damage is a common and important distraction injury, with numerous MRI manifestations [4].

A sudden strong force is more likely to snap a ligament in its midsubstance. Before Growth plates close, the immature skeleton is at increased risk of avulsion fracture.

The risk of avulsion is also increased in the elderly population because of osteoporosis.

In ACL tears, the tibia translates anteriorly and the menisci can be torn either by entrapment between the tibia and femur or by tension transmitted to them by the posterior joint capsule and menisiofemoral ligaments [5].

The ACL and MCL develop maximum tension when internal rotation is combined with valgus force [6]. Therefore with excessive internal rotation and valgus loading, both the ACL and MCL fail, leading to anterior tibial translocation and the pivot shift pattern of bone marrow edema.

Methodology

This study was performed in the department of Radiology on patients referred from orthopaedic department over a period of twelve months.

Sample size: Fifty cases

Type of study: Prospective study

Inclusion Criteria

- Patients presenting with painful or unstable knee joint with or without other associated symptomatology.
- Any age group.
- Both male and female patients.

Exclusion Criteria

- Patients who has been operated previously on the same knee.
- Any absolute contraindication for MRI.

They were evaluated with clinical examinations and were subsequently subjected to imaging of knee using 1.5 T MRI Philips Achieva MRI machine.

Results

There were 37 males and 13 females in this study. Males comprised 74% and female 26% of the study group and male patients exceeded the number of female patients in all the age groups.

The age group ranged from 15 to 64 years with mean age of 33.2 years. Maximum patients (50%) were in the age group of 15-30 years and only 14% were more than 45 years.

So it was mostly young adult male who underwent MR for clinically suspected internal derangement of knee.

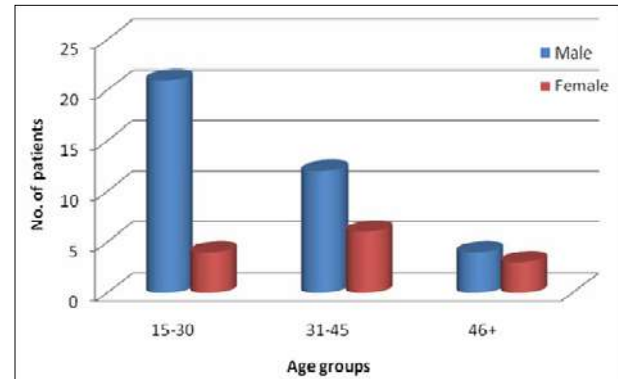


Fig 1: Age and sex distribution of patients with suspected internal derangement of knee

Definite history of acute trauma preceded the symptomatology in 35 cases (70%). Criteria for acute trauma was taken as any significant trauma to knee within six weeks of imaging. Other 30% of patients had a history of remote trauma or belonged to non-traumatic group. 73% of males and 61.5% of females belonged to acute traumatic group.

Table 1: Distribution of trauma in study group

Acute trauma	Male	Female
Present	27	8
Absent	10	5

Tears of various ligaments around the knee were identified involving either a single ligament or combination of ligaments. ACL tear was seen in 29 (45.3%), PCL tear in 5 (7.8%), MCL tear in 16 (25%) and LCL tear in 14 (21.8%) of cases.

ACL tears were imaged in total of 29 cases. Complete tear of ACL was detected in 19 cases and partial tear in 10. Associated LCL tears were identified in 13 cases (45%) and MCL tears in 10 cases (35%).

ACL tears were associated with tear of posterior cruciate ligament in 4 cases.

All of these had history of significant trauma.

Association with joint effusion was noticed in 67%. Bone contusion was associated in 72% of ACL tears. Bony contusions of lateral compartment structures were noted in 20 cases (69%).

86% of cases with Positive Lachman's test had complete ACL tears on MR. In 14% of cases, ACL tear were not suspected clinically on Lachman's test but was detected on MR these were all cases of partial ACL tears.

Indirect signs of ACL tear in the form of Objective criteria such as Sagittal ACL - Tibial angle, Blumensaat line - ACL angle, PCL angle and anterior tibial displacement were used.

The mean Sagittal ACL - Tibial angle was 41° in case of partial ACL tear while the mean was only 23° in complete ACL tears.

The mean Blumensaat line - ACL angle was + 3° in partial ACL tear and was + 27° in complete ACL tears.

The mean PCL angle was 123° in partial ACL tear and more acute angled with a mean angle of 106° in complete ACL tears. In Medial Meniscus, Posterior horn was involved in 20 (65%) and the predominant type of tear in posterior horn

was oblique tear that occurred in 10 (50%). Also the commonest type of tear involving anterior horn was also oblique tear. The commonest type of tear to involve the whole of meniscus was bucket handle tear.

Grade III tear were the commonest seen in 13 cases (42%) followed by Grade II in 29%.

In lateral meniscus, also posterior horn was commonest site of involvement, occurring in 10 (53%). Predominant type of tear was radial and was seen in 4 (21%). Oblique tears predominantly involved the posterior horn of lateral meniscus. In contrast to medial meniscus, bucket handle tears of lateral meniscus spared the anterior horn. Two cases of meniscocapsular separation was seen and involved posterior horn of lateral meniscus. Horizontal tears involved the anterior horn more than posterior horn.

Grade III tears were common in both medial and lateral menisci followed by Grade II tears. 44% of meniscal tear were of Grade III and 30% were Grade II. Least common grades of tear were Grade IV tear in medial meniscus and Grade I tear in lateral meniscus.

Table 2: Grades of meniscal tears

Grades of tear	Medial meniscus	Lateral meniscus	Total percentage
Grade I	5	1	12%
Grade II	9	6	30%
Grade III	13	9	44%
Grade IV	4	3	14%

Lachman test was conclusive for ACL tear in 86% of cases, posterior drawer test in 60%, McMurray's test in 68% of medial meniscal tear, 79% of lateral meniscal tear, valgus stress test in 75% of MCL tear and varus stress in 100% of LCL tears.

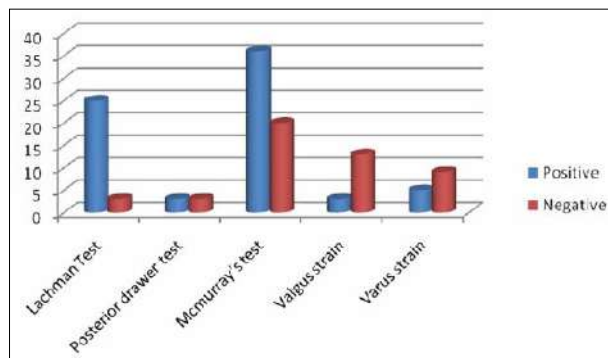


Fig 2: Clinical examinations for internal derangement of knee

Discussion

Meniscal tear was diagnosed by either an area of abnormal signal within the meniscus on at least one image that extended to the meniscal articular surface, or abnormal morphology of the meniscus. If the abnormal signal extends to the articular surface on two or more images, the sensitivity for a meniscal tear increases from 56% to 94% medially and from 30% to 90% laterally.

Meniscal tear was found in 50 cases in this study. 47% involved only the medial meniscus, 14% only the lateral meniscus and 39% involved both menisci.

Anterior horn tear was found in 3% of cases in our study which is comparable to the study done by De Smet *et al.* [7]. That showed involvement of anterior horn of medial

meniscus in 2% of cases. Grade III tear were the commonest seen in 13 cases (42%) followed by Grade II in 29%.

Various types of medial meniscal tears detected in this study were – horizontal tear (26%), oblique tear (42%), bucket handle (9.5%), radial tear (3%) and complex tears (19%).

Helms *et al.* [8] reported that 10% of tears of medial meniscus were of bucket handle type. Our study also found similar occurrence of bucket handle tears (9.5%). All the 3 cases of bucket handle tear of medial meniscus showed double PCL sign, where the displaced fragment was seen as a hypointense structure parallel to PCL on all sequences. MR has a sensitivity of 27% to 44% and a specificity of 98% to 100% in detecting bucket-handle tears.

Studies done by Wright *et al.* [9] emphasized the importance of MR imaging in reliable identification of meniscal displacements and fragments. Displaced meniscal fragments are often clinically significant lesions requiring surgical intervention and therefore are important to identify. Displaced meniscal injuries can occur in both the medial and lateral meniscus and include flap tears, bucket-handle tears, and free fragment displacement.

A definite indication for MR in clinically suspected meniscal tears are the identification of the meniscal flap. It is important because arthroscopy may be necessary for its removal or reattachment. When located inferomedial to the tibial plateau and deep in relation to the medial collateral ligament, these fragments may become an arthroscopic pitfall when the fragment is unapparent until probed with a hook. According to Lynn K Lecas *et al.* [10] MR imaging is a sensitive, noninvasive method of detection of meniscal tears and their displaced fragments. MR imaging may also help in preoperative planning and may facilitate the detection of inferiorly displaced fragments that might have gone unnoticed during surgery.

One case of inferior flap tear of medial meniscus was identified in our study. Pitfall of imaging displaced meniscal fragment is that other normal low-signal-intensity structures, such as the semimembranous tendon, should not be mistaken for displaced menisci.

Lateral meniscal tears also commonly occurred in posterior horn (53%), as in medial meniscus. But anterior horn of lateral meniscus was more commonly torn (37%) than that of medial meniscus. Various types of lateral meniscal tears detected in this study were – oblique tears (16%), horizontal tears (16%), radial tear (21%), Bucket handle tear (10.5%), vertical tear (10.5%), meniscocapsular separation (10.5%) and complex tear (16%). Grade I tear was found in 5%, Grade II in 31.5%, Grade III in 47% and Grade IV in 16%.

In both medial and lateral menisci Grade III tear were most common type of tear.

Superior menisco-popliteal fascicle was assessed in cases of lateral meniscal injuries.

Disruption of superior menisco-popliteal fascicle was noted in 82% of lateral meniscal tear and in 18% without lateral meniscal injury.

Study done by Blankenbaker *et al.* [11] on 121 patients which compared MR findings with arthroscopy, suggested that abnormal fascicle is highly associated with a lateral meniscal tear but not specific for a tear.

Fascicle abnormalities are associated with lateral meniscal tears because the biomechanical forces that tear the meniscus also cause disruption of the fascicles.

Root tear was found in 1 case of medial meniscal tear. Tears of the posterior meniscal root can be easily missed because

of inconsistent clinical symptoms and can be overlooked without thorough arthroscopic examination. Retrospective study conducted by So Yeon Lee *et al.* [10, 3] concluded that MRI of the knee is reliable and accurate for detection of radial tears of the medial meniscal root and Coronal T2-weighted imaging was the most useful MRI sequence.

Radial tears are crucial to be identified on MR as precise description of this type of tear can alert the clinician and allow better preoperative planning. Jee WH *et al.* [12] emphasized that the ability to preoperatively identify such patients suitable for meniscal repair would be ideal. In our study 20% of radial tears occurred in medial meniscus and 80% in lateral meniscus.

In this study, 60% of Bucket handle tears involved medial meniscus and 40% the lateral meniscus. But other studies have shown 2:1 ratio of medial-to-lateral involvement in bucket-handle tears. The displaced fragment could be seen as fragment in notch, double PCL or flipped meniscus sign. In our study, double PCL sign was seen in 3 cases and fragment in notch was seen in 2 cases. Flipped meniscus sign was not seen. The double PCL sign is a highly specific indicator of a bucket-handle tear, with a specificity range of 98%-100% and a positive predictive value of 93%. However the sensitivity of MR imaging for the diagnosis of bucket handle tears is lower than that for other meniscal tears.

Conclusion

Currently, MR imaging has evolved as the most commonly performed radiologic test in the assessment of intra-articular knee abnormalities especially in traumatic settings. Post-traumatic pre-arthroscopic MR imaging evaluation has proved to be cost-effective. Although arthroscopy has revolutionized the diagnosis and treatment of knee disorders, most orthopedists acknowledge the invasiveness of the procedure; limitations in evaluation of extra-articular pathology; cost and uncommon but potential complications associated with the procedure. They acknowledge the accurate diagnostic imaging complementing their clinical evaluation and providing a global intra-articular and extra-articular assessment of the knee.

References

1. Mair SD, Schlegel TF, Gill TJ, Hawkins RJ, Steadman JR. Incidence and location of bone bruises after acute posterior cruciate ligament injury. *Am J Sports Med.* 2004; 32:1681-7.
2. Sanders TG, Miller MD. A systematic approach to magnetic resonance imaging interpretation of sports medicine injuries of the knee. *Am J Sports Med.* 2005; 33:131-48.
3. Ross G, Chapman AW, Newberg AR, Scheller AD Jr. Magnetic resonance imaging for the evaluation of acute posterolateral complex injuries of the knee. *Am J Sports Med.* 1997; 25:444-8.
4. Rodriguez W, Vinson EN, Helms CA, Toth AP. MRI Appearance of Posterior Cruciate Ligament Tears. *AJR.* 2008; 191:W155-W159.
5. Recondo JA, Salvador E, Villanúa JA, Barrera MC, Gervás C, Alústiza JM. Lateral Stabilizing Structures of the Knee: Functional Anatomy and Injuries Assessed with MR Imaging. *RadioGraphics.* 2000; 20:S91-S102.
6. Berquist TH. *MRI of Musculoskeletal System.* 5th ed. Philadelphia: Lippincott William & Wilkins, 2006.
7. De Smet AA, Norris MA, Yandow DR, Quintana FA,

- Graf BK, Keene JS. MR diagnosis of meniscal tears of the knee: importance of high signal in the meniscus that extends to the surface. *AJR.* 1993; 161:101-7.
8. Helms CA, Laorr A, Cannon WD. The absent bow tie sign in bucket-handle tears of the menisci in the knee. *AJR.* 1998; 170:57-61.
9. Wright DH, De Smet AA, Norris M. Bucket-handle tears of the medial and lateral menisci of the knee: value of MR imaging in detecting displaced fragments. *AJR.* 1995; 165:621-25.
10. Lecas LK, Helms CA, Kosarek FJ, Garret WE. Inferiorly Displaced Flap Tears of the Medial Meniscus: MR Appearance and Clinical Significance. *AJR.* 2000; 174:161-4.
11. Blankenbaker DG, De Smet AA, Smith JD. Usefulness of Two Indirect MR Imaging Signs to Diagnose Lateral Meniscal Tears. *AJR.* 2002; 178:579-82.
12. Jee WH, McCauley TR, Kim JM, Jun DJ, Lee YJ, Choi BG *et al.* Meniscal tear configurations: categorization with MR imaging. *AJR Am J Roentgenol.* 2003; 180(1):93-7.