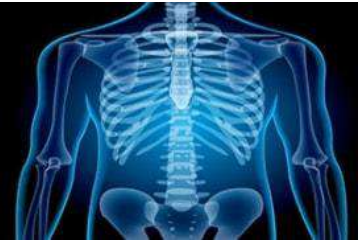

International Journal of Radiology and Diagnostic Imaging



E-ISSN: 2664-4444
P-ISSN: 2664-4436
www.radiologypaper.com
IJRDI 2020; 3(2): 21-23
Received: 11-02-2020
Accepted: 14-03-2020

Dr. Ankush Maheshwary
MBBS, Medical officer
Mrs. Khushbir Kalra Memorial
hospital, Amritsar, Punjab
Address: H.No 356 Nagina
Avenue, Majitha Road,
Amritsar, Punjab, India

Dr. Dolly Khanna
MBBS, DNB Radiodiagnosis
Head of Radiodiagnosis
Surjit Hospital, Amritsar,
Punjab, India

Dr. Karandeep Singh Bhatti
MBBS, Medical officer
Mrs. Khushbir Kalra Memorial
hospital, Amritsar, Punjab,
India

Antenatal diagnosis of bilateral hydronephrosis- A case report

Dr. Ankush Maheshwary, Dr. Dolly Khanna and Dr. Karandeep Singh Bhatti

DOI: <http://dx.doi.org/10.33545/26644436.2020.v3.i2a.92>

Abstract

Antenatal ultrasonography has become the frontline investigation for detailed fetal evaluation. Ease of use, widespread accessibility, and prompt diagnosis has given the routine use of ultrasonography a boost with doctors increasingly relying on it in every stage of pregnancy. Fetal hydronephrosis detected as an abnormal dilatation of the urinary canal is one of the most common prenatal anomalies. It is defined by two universally accepted criteria vis-à-vis Society for fetal Urology (SFU) grading and anteroposterior diameter (RAPD) of the renal pelvis. Evaluation antenatal hydronephrosis (ANH) before and after birth is warranted, and factors such as to cause, severity, and whether the condition is uni- or bilateral are used to formulate decisions about additional assessment and potential intervention. Here we present a typical case of bilateral fetal hydronephrosis detected in the 2nd trimester. The progression was analyzed by regular antenatal US and appropriate management instituted.

Keywords: Antenatal ultrasonography, bilateral fetal hydronephrosis, society for fetal urology grading, renal pelvic anteroposterior diameter

Introduction

Prenatal ultrasonographic detection of fetal genitourinary abnormalities was first reported in 1970 by Garrett *et al*. Prenatal hydronephrosis is diagnosed at an incidence of 1:100 to 1:500 by ultrasonographic studies [1]. The condition is bilateral in 17-54% of the cases and additional abnormality is occasionally present [2]. Isolated unilateral hydronephrosis is usually benign and about half of these cases might show complete resolution on follow up [3]. Prenatal ultrasound can detect several urinary tract pathologies e.g. multicystic dysplastic kidneys but the most frequent cause that requires surgical correction are ureteropelvic junction obstruction (10-30%), vesicoureteral reflux (10-40%), and vesicoureteric junction obstruction (5-15%) [4].

Hydronephrosis is suspected if RAPD > 4 mm in 2nd trimester and > 7 mm in the 3rd trimester is detected on ultrasound [2]. ANH can be mild, moderate/severe, persistent depending upon the Renal pelvic anteroposterior diameter (RAPD) of ≥ 5 mm, ≥ 7 mm and ≥ 10 mm (in 3rd trimester) respectively [4]. In 1993 SFU grading (Society for fetal urology) was adopted as a more quantitative measure of ANH, based on the appearance of the intrarenal collecting system [5]. SFU grading is as follows [6].

Grade 0- no hydronephrosis

Grade 1- Dilatation of the pelvis with or without visualization of the infundibulum

Grade 2- Calyces are visible in addition to dilatation of pelvis

Grade 3- Calyces are also dilated

Grade 4- Most severe and implies renal parenchymal thinning

Case Report: A 29-year-old female (G1P0) presented to the department for a routine Level II scan.

The sonogram showed a single intrauterine pregnancy with a variable presentation of 19 weeks and 4 days. The fetal movements were normal.

Fetal kidney showed hydronephrosis (fig 1) with dilated ureters up to the lower end. The left kidney shows grade III hydronephrosis with megaureter (10 mm) (fig 3). The right kidney showed hydronephrosis with dilated ureter (6mm) (Fig 2). Urinary bladder appeared small in

Corresponding Author:
Dr. Ankush Maheshwary
MBBS, Medical officer
Mrs. Khushbir Kalra Memorial
hospital, Amritsar, Punjab
Address: H.No 356 Nagina
Avenue, Majitha Road,
Amritsar, Punjab, India

size (fig 4).

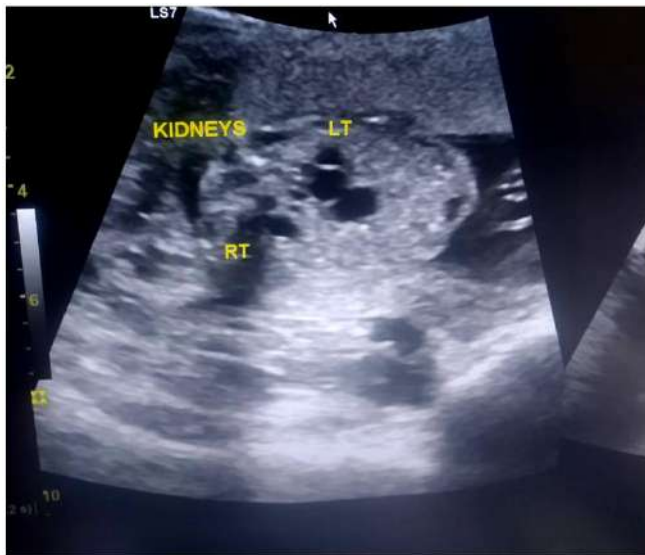


Fig 1: Red arrow indicates the pelvicalyceal junction In fetal kidney

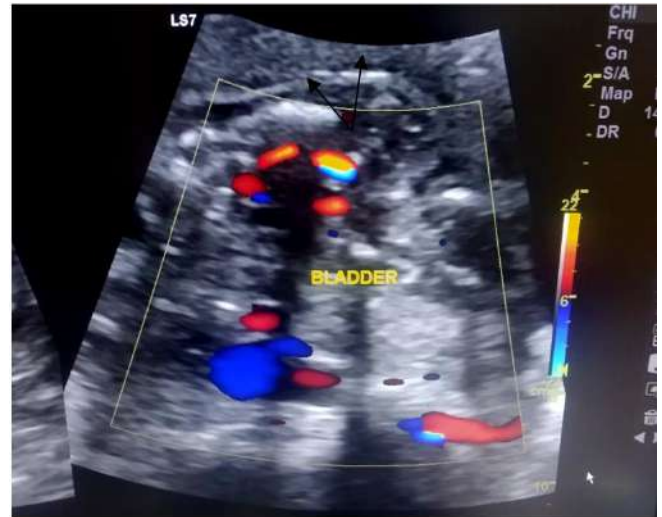


Fig 4: Urinary bladder appeared small in Size

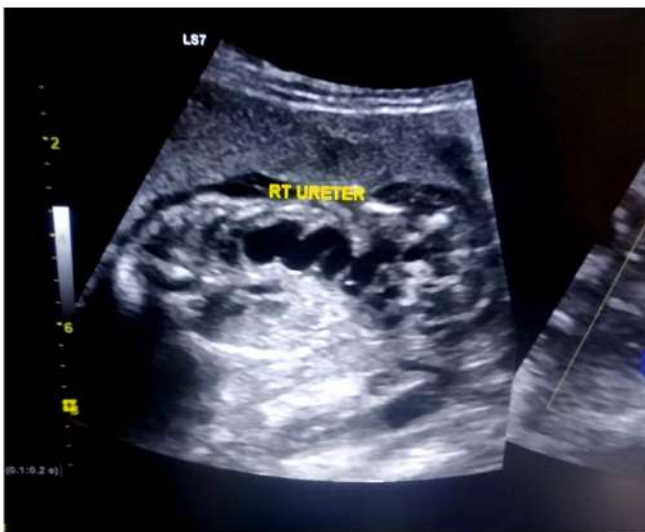

Fig 2: The right kidney showed hydronephrosis with dilated ureter (6mm)

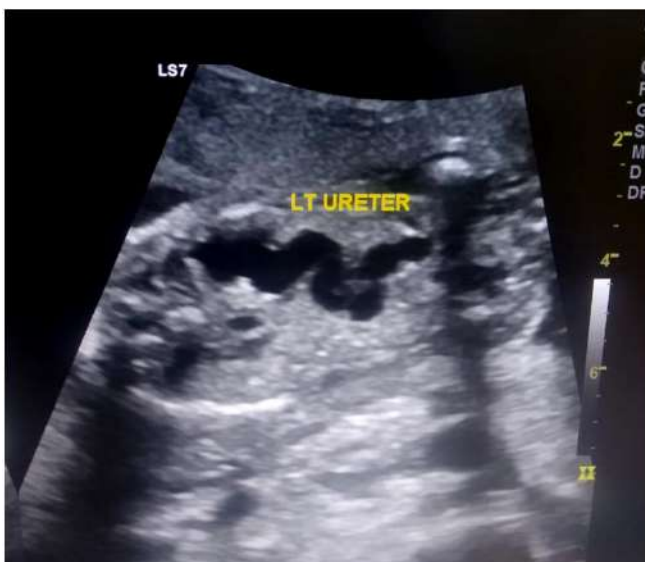

Fig 3: The left kidney shows grade III hydronephrosis with megaureter (10 mm)

Amniotic fluid volume was at a lower limit of normal range with AFI 8 cm. The abdominal wall was intact and the stomach bubble visualized. The placental location was posterior and 2 cm from the internal os. No evidence of craniovertebral junction anomaly was seen and the skull and spine appeared normal. The fetal heart was normal-sized, four chambered with apex formed by the left ventricle.

Effective fetal weight (at the time of examination) was 296.77 Gms +/- 42.52 Gms. Fetal growth parameters such as Biparietal diameter, Head circumference, abdominal circumference, Femur length were 4.49 cm (19 weeks 4 days), 17.17 cm (19 weeks 6 days), 14.38 cm (19 weeks 5 days), 2.98 cm (19 weeks 1 day) respectively.

Diagnosis of bilateral hydronephrosis possibly due to posterior urethral valve or urethral obstruction was made and the patient was advised regular followup every 4 weeks, to decide upon the continuation of pregnancy and forming adequate management plan.

Discussion: The causes of ANH include pelviureteric junction obstruction, vesicoureteral junction obstruction, Posterior urethral valve (PUV), Multicystic dysplastic kidney (MCDK), and vesicoureteric reflux (VUR). Almost 80% of cases of ANH detected in the second trimester resolves spontaneously, persistent or worsening in the 3rd trimester is associated with postnatal pathology. Sequential follow-up with ultrasonography largely depends upon the gestational age at which it is diagnosed; a 4-6 weeks followup is usually recommended. Renal pelvic APD of 5mm and 8-10 mm in the 2nd and 3rd trimester respectively is 100 % sensitive in predicting the need for surgery [2].

Known predictors of adverse outcomes include oligohydramnios, severe renal parenchyma changes such as cortical cysts and renal parenchyma hyperechogenicity, bladder outlet obstruction and severe extrarenal abnormality [7]. Fetal hydronephrosis associated with a major structural abnormality or with one or more additional soft signs raises the likelihood of chromosomal aneuploidy hence parental counseling and karyotyping are advised [2].

In cases where hydronephrosis progresses significantly impairing renal and pulmonary functions, interventions may be considered. Options for fetal intervention include open fetal surgery, vesico-centesis/renal pelvis aspiration, vesico-amniotic shunt, and more experimental methods, such as fetoscopic and laparoscopic surgery. Unfortunately, an

intervention can only be done later during gestation, which is frequently too late to prevent renal dysplasia [5].

Megaureter is the descriptive term referring to the dilated ureter. Primary megaureter refers to ureteral dilation without an identifiable anatomic cause at the vesicoureteral junction. There are three types of primary megaureter: obstructed primary megaureter, refluxing primary megaureter, and nonrefluxing unobstructed primary megaureter. In primary obstructed megaureter, the most distal part of the ureter is adynamic and unable to conduct a peristaltic wave, producing a functional obstruction similar to that observed in achalasia or Hirschsprung's disease. US features of primary megaureter include fusiform dilation of the distal third of the affected ureter proximal to its insertion into the bladder and a smooth, tapered, adynamic far distal ureter on real-time examination [8]. Megaureter or vesicoureteric junction obstruction can be managed with observation (with the serial US and renal scans) and antibiotic prophylaxis, in those whose renal function is greater than 35% [9].

The posterior urethral valve is the most common cause of lower urinary tract obstruction and presents mostly in males. After birth, any suspected case of PUV should be investigated for with renal US and VCUG on the 1st day of life and placement of 5 french feeding tube to ensure decompression of the obstructed bladder is indicated. Neonate's creatinine levels are closely monitored thereafter until it nadirs. The incision of the valve is performed in the first week of life in most cases by several approaches including cold hook knife, electrocautery, and balloon dilatation. In select cases of profound upper urinary tract dilatation despite catheter placement or severe renal failure diversion of bladder or ureter is indicated [9], [10].

The role of prophylactic antibiotics in suspected neonates until the post-natal investigations are completed is still controversial but most physicians use amoxicillin 50 mg/day and cephalexin 50 mg/day [11].

Conclusion

ANH is one of the most common urinary tract abnormalities detected on the routine prenatal scan, with most of the cases resolving spontaneously after birth. The diagnoses, workup, and management of Antenatal hydronephrosis has undergone a paradigm shift from pre-emptive surgical intervention to a more conservative approach as the natural history of the differential diagnosis becomes more appreciated [10]. When a fetus is suspected to have hydronephrosis the goal of management should be determining the differential diagnosis, assessment of associated anomalies and determining the fetal and postnatal risk of the malformations. Prenatal consultation with a pediatric nephrologist and urologist is useful in decreasing parental anxiety and facilitating postnatal management [11].

References

1. Asl AS, Maleknejad S. Clinical outcome and follow-up of prenatal hydronephrosis. *Saudi J Kidney Dis Transpl.* 2012; 23:526-31
2. Sinha A, Bagga A, Krishna A, *et al.* Revised guidelines on management of antenatal hydronephrosis. *Indian Pediatrics.* 2013; 50(2):215-231. doi:10.1007/s13312-013-0064-6.
3. Sarhan OM, Helaly AE, Otay AA, Ghanbar MA, Nakshabandi Z. Isolated low grade prenatally detected unilateral hydronephrosis: do we need long term follow-up? *International braz j urol.* 2018; 44(4):812-818. doi:10.1590/s1677-5538.ibju.2017.0474.
4. Weerakkody Y. Fetal hydronephrosis: Radiology Reference Article. *Radiopaedia Blog RSS.* <https://radiopaedia.org/articles/fetal-hydronephrosis?lang=gb>. Accessed April 5, 2020.
5. Yamaçake KGR, Nguyen HT. Current management of antenatal hydronephrosis. *Pediatric Nephrology.* 2012; 28(2):237-243. doi:10.1007/s00467-012-2240-7.
6. Zhan X, Tao G, Cheng L, Liu F, Li H, Liu S. Ultrasound score: a new method to differentiate fetal physiological and pathological hydronephrosis. *European Journal of Obstetrics & Gynecology and Reproductive Biology.* 2010; 151(1):26-32. doi:10.1016/j.ejogrb.2010.02.046.
7. Wollenberg A, Neuhaus TJ, Willi UV, Wisser J. Outcome of fetal renal pelvic dilatation diagnosed during the third trimester. *Ultrasound in Obstetrics and Gynecology.* 2005; 25(5):483-488. doi:10.1002/uog.1879.
8. Choi YH, Cheon JE, Kim WS, Kim IO. Ultrasonography of hydronephrosis in the newborn: a practical review. *Ultrasonography.* 2016; 35(3):198-211. doi:10.14366/usg.15073
9. Shamsunnahar P, Motaleb A, Nasrin B, Hossain F, Mahmood S, Begum S. Fetal Hydronephrosis, A Case Report And Review of Literature. *Journal of Paediatric Surgeons of Bangladesh.* 2015; 5(1):36-38. <https://doi.org/10.3329/jpsb.v5i1.23888>
10. Herndon CA. Antenatal Hydronephrosis: Differential Diagnosis, Evaluation, and Treatment Options. *The Scientific World Journal.* 2006; 6:2345-2365. doi:10.1100/tsw.2006.366.
11. Psooy K, Pike J. Investigation and management of antenatally detected hydronephrosis. *Can Urol Assoc J.* 2009; 3(1):69-72. doi:10.5489/cauj.1027